CONTRIBUTION TO THE EMBRYOLOGY OF THE LIZARD;

With especial Reference to the Central Nervous System and some Organs of the Head; together with Observations on the Origin of the Vertebrates.

HENRY ORR, PH.D.

UNIVERSITY FELLOW IN BIOLOGY AT PRINCETON, N. J.

INTRODUCTION.

THE embryology of the lizard has been investigated in parts by various authors, yet all the work done on the subject is hardly so complete as to warrant a monograph. Concerning the segmentation of the egg and the formation of the germ-layers we are indebted for our knowledge to *Balfour*,[1] *Hoffman*,[2] and *Weldon*.[3] These earliest stages of development were lacking in the material collected by me, so that my work begins about the stage where that of *Balfour* and *Weldon* ended, and deals with the early development and differentiation of some of the organs. The most comprehensive contribution hitherto made to lizard-embryology is that of *Hoffman*. *Strahl*, in a series of articles in the Arch. f. Anat. u. Phys. (Anat. Abth.) '81–87, has described the relations of the amnion and some anatomical features, but his methods prevented him from entering upon details requiring a finer histological investigation.

The material for the present investigations was collected by me while a member of the zoölogical expedition generously equipped and sent to Abaco, Bahamas, W.I., by the *Johns Hopkins University*. The specimens have been kindly identified for me by *Prof. E. D. Còpe.*

---

[1] *Balfour.*—On the Early Development of the Lacertilia, together with some Observations on the Nature and Relations of the Primitive Streak.—*Quart. Journ. of Mic. Sci.*, Vol. XIX., N.S., 1879.

[2] *Hoffman.*—Weitere Untersuchungen z. Entw.-gesch. d. Reptilien.—*Morphologisches Jahrbuch*, XI. Bd., 1885.

[3] *Weldon.*—Note on the Early Development of Lacerta Muralis.—*Quart. Journ. of Mic. Sci.*, Jan., 1883.

The species on which most of my work has been done is *Anolis sagræi* (Dum. et Bib.), but I have also examined some stages of *Sphærodactylus notalus* (Baird) and *Liocephalus carinatus* (Gray). The embryo of Anolis develops in the uterus until about the stage represented in Fig. 2, C, Pl. XII. I found the full-sized eggs, rarely four in number, in the uterus. They have a hard white shell when deposited, and could be obtained in large numbers in the sand-filled crevices of heaps of broken conch-shells on the sea-beach. The eggs of the other two species are of a different size, with soft shells. The embryos were killed in Perenyi's fluid, and preserved in 90° alcohol. After this method of treatment I found a saffranin stain gave the best results.

Owing to the ventral curve in the head of the embryo (cranial flexure), the words "anterior" and "posterior," etc., come to have two meanings. One has regard to the entire embryo, in which sense the extreme anterior end of the embryo would be the dorsal summit of the mid-brain. The other meaning regards the organs as they would appear if the curve were rectified and the head continued in the straight line of the body axis. In this case the extreme anterior end would be the outer surface of the front median lip (anterior medullary fold) of the medullary groove. This would also be the dividing line between the dorsal and ventral surfaces. As this latter morphological meaning expresses the homologies of the parts and greatly simplifies the terminology, I shall adopt it throughout.

Except where otherwise specified, the description and figures refer to Anolis.

PART I.

General Description of Youngest Stage.

The youngest stage which I have obtained is represented entire in Fig. 1, A, and in sections in Figs. 7, A–18, A, inclusive. There are four protovertebræ. The cranial flexure is well marked, and the lateral medullary folds touch each other above the central canal from a point just behind the primary fore-brain, backward as far as the lumbar region. Although the medullary folds touch each other through this distance, they are fused together in only a short part of the middle dorsal region. Toward the tail the lumen of the central canal gradually enlarges, and finally is wide open above. Anteriorly to the apex of the cranial flexure the lateral medullary folds spread wide apart (*MF*, Figs. 8, A–12, A), but in the most anterior part of the head they curve toward each other and unite in a median anterior fold (*AF*, Fig. 13, A). By measurements of its thickness and distance from the dorsal crest of the hind-brain, it may be seen that this anterior fold is not a simple continuation of the ventral floor of the primary first ventricle, but an elevated fold continuous with the lateral folds, and enclosing the primary first ventricle anteriorly as the lateral folds enclose it laterally.

The epiblast, which is continuous with the dorsal edges of the medullary folds, is spread a certain distance laterally over the body of the embryo, and is then folded up over itself to form the amnion. The line of this fold runs parallel to the curved axis of the body and head, so that the line of the fold at the side of the head curves ventrally and slightly backward. In Fig. 13, A, the curved line of the fold is cut in two places on the left side of the head. The part of the amnion springing from the ventrally and backward curved line of the fold covers the mid- and fore-brain. The epiblast, continuous with the dorsal edge of the anterior medullary fold, is spread over the external surface of the anterior fold until just beyond the ventral edge of the latter it meets the line of the amnion fold, and recurving on itself it forms the anterior median part of the amnion (see Fig. 14, A, and its explanation). In a median sagittal section, the anterior part of the amnion cavity appears to curve around the head, and terminate with a small blunt end at that point where the mouth will first appear, — *i.e.*, the pit of the so-called mouth-involution (cf. Diagram I.). These relations of the amnion I have deduced by reconstructing the drawings of consecutive transverse sections.

The hypoblast extends as a blind sack into the head, forming the rudiment of the head intestine. Along the dorsal median area of the hypoblast arises the notochord: its origin from the hypoblast has been described by *Hoffman*. In the embryo of series A, the greater part of the notochord is distinctly developed, but in some places it still shows a more intimate connection with the hypoblast. At this stage it lies everywhere in close contact with the hypoblast below it, and with the medulla above it. The dorsal wall of the head intestine, with its accompanying notochord, follows, therefore, the curved ventral surface of the primary mid- and fore-brain around to that point immediately ventral to the anterior medullary fold, where the hypoblast touches and fuses with the epiblast. At the base of the anterior medullary fold the notochord runs into a mass of cells (*HC*) which is continuous with the fused hypoblast and epiblast. The mass of cells seems, however, to be of hypoblastic origin, in like manner as the notochord (Figs. 11, A–15, A, Pl. XIII.).

The ventral wall of the head intestine curves slightly downwards to meet the epiblast at the point of the oral fusion. In the present stage there are no traces of the branchial system: when the branchial clefts appear later, the posterior clefts are parallel to each other, and at right angles to the axis of the intestine. The two anterior clefts are not parallel, but their ventral ends are convergent. These facts seem to me explicable only as the result of a general ventral bend of the anterior end of the embryo, — a bend which appears primarily as the cranial flexure, and imparts itself secondarily to the notochord and head intestine; for, owing to the relative mass of the different parts, it would be impossible to suppose the converse method to be true.

We cannot avoid regarding as dorsal all that part of the intestine which gives rise to notochord. In this case the notochord extends as far as the oral fusion of hypoblast and epiblast; therefore this point of fusion must be regarded as the extreme anterior end of the head intestine. Owing to the curve of the dorsal wall of the intestine, its lumen appears in section as far forward as section 13, A, Pl. XIII.; but this is simply the dorsal part of the intestine, not a "pre-oral intestine," for this latter, in Anolis at least, would be impossible.

Diagram I. will make the relation of these parts more readily apparent. It will be seen that the fusion of notochord and hypoblast with the epiblast at the pit of the "mouth involution" appears to have a restraining influence on the epiblast, and to hold it in place at this point. The external or ventral wall of the "mouth involution" is simply the median part of the amnion, and arises directly on the continuation of the lateral line of the amnion fold, — indicated by the dotted line *l, A, F.* The ventral curvature of the medullary folds gives to the "mouth involution" the appearance of being an invagination of epiblast to meet the hypoblast; but its relation to the amnion fold does not warrant such a conclusion. If we imagine the head continued forward in a straight line (which was undoubtedly its more primitive condition), then we should have the hypoblast of the head intestine extending to the anterior surface of the head, and fused with the epiblast at a point immediately ventral to the medullary fold and just dorsal to the line of the amnion fold.

DIAGRAM I.

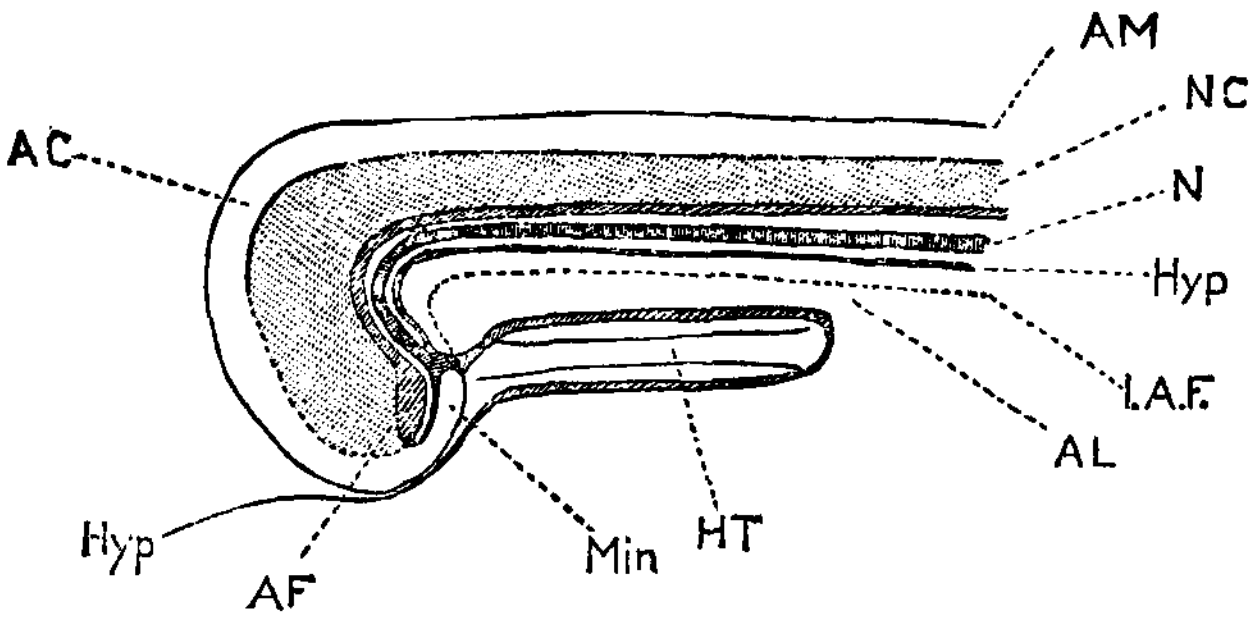

AC — Amnion cavity. AF — Anterior fold. AL — Alimentary canal. AM — Amnion. HT — Heart. Hyp — Hypoblast. l. A. F. — Lateral line of the amnion fold. Min — Mouth involution. N — Notochord. NC — Neural canal.

The dotted line running from the anterior fold to the apex of the cranial flexure indicates the part of the brain-roof which is still open.

Having passed the stage just described, and figured at 1, A, Pl. XII., the embryo begins to develop the various organs in rapid succession, or some apparently simultaneously. Before the primary first ventricle is completely closed anteriorly, the optic outgrowths have made their appearance (Fig. 45, Pl. XV.). Shortly after the closing of the brain, the ear appears as a dorsolateral invagination of the epiblast. At the same time appear the hypoblastic evaginations to form the gill-clefts. At this time the mouth has not yet broken through (see series B). Shortly after the appearance of the oral opening, the condition of the head is as shown in the median sagittal section (Fig. 51, D, Pl. XV.). At this time the segmental organs are well developed; the thyroid gland, the liver, and pancreas appear. Of the outgrowths of the anterior half of the intestine, the thyroid gland is the first to appear, and the lung the last. The head-cavities have become large, oval-shaped cavities on either side of the head, medial to the posterior part of the eye-cup (*HC*, Fig. 2, C, Pl. XII.).

Figs. 2, C, and 24, C–42, C, represent that stage in which all the embryonic organs have appeared save the lung, and the point of origin of the latter is already indicated. The development of some of these parts is given below in detail.

2. *The Notochord, Head-cavities, and Hypophysis.*

It is generally agreed that the notochord arises by a differentiation of the linear median area of the dorsal wall of the primitive intestine. The extreme anterior point of this differentiation of hypoblast into notochord still remains uncertain for most animals, and we are in doubt as to whether it remains constant in its relations to other parts in all animals, or whether it is sometimes nearer to, and again sometimes farther from, the anterior extremity of the intestine. In the frog, the intestine has the appearance of extending much beyond the anterior end of the notochord, while in the cyclostomata the converse seems to be true, and the notochord appears to extend beyond the intestine. The lizard, in this respect, seems to represent a primitive state, for here the notochord continues to the anterior extremity of the intestine, or the oral fusion of hypoblast and epiblast. The origin of the notochord has already been referred to (S. 1). In the lizard it is relatively very much smaller than in Elasmobranchs and Amphibians, and never attains such large proportions; also in relation to the growth of the other organs it becomes vacuolated much later in the lizard than in Amphibians. In advanced embryos the vacuolated part extends slightly anterior to the first vertebral rudiment; but from here forward to the region of the hypophysis it remains a long time in its primitive condition, sometimes irregularly crooked, and finally disappears, leaving as a last trace a more densely nucleated line in the tissue of the base of the rudimentary skull.

When the notochord first appears, its anterior part lies between the intestine and the brain-rudiment, touching both. Fig. 10, A, Pl. XIII., represents a section tangential to the ventral external surface of the mid-brain. In the third section, behind

10, A, the ventrally curved part of the notochord is visible (*N*, Fig. 11, A). Its anterior end fuses with a mass of cells (*HC*) which lie close to the ventral surface of the rudiment of the fore-brain. In the fourth section, behind 11, A, this mass of cells (*HC*) is seen to be fused with the epiblast (Fig. 12, A). This fusion with the epiblast is, however, continuous from side to side across the median line. Five sections behind 12, A, this mass of cells (*HC*) is seen to be also completely fused with the wall of the intestine (*AL*, Fig. 13, A). The section 13, A, passes near the inner surface of the epiblast at *Hph*. The epiblast near this point lies close against the base of the anterior medullary fold, *AF*. The epiblast at *Hph* is the roof of the hypophysis, which, appearing at this early stage, remains permanently unmoved from this point of contact with the fore-brain. Six sections farther backward, Fig. 14, A, represents a section passing near the external surface of the roof of the hypophysis (*Hph*), and cutting in its own plane the epiblast (*Ep*) which covers externally the anterior medullary fold. Five sections behind 14, A, the section 15, A, passes through the anterior curved end of the amnion cavity (*M.in*). The wall of fused epiblast and hypoblast, which separates the lumen of the intestine from the amnion cavity, shows here its thinnest point in the median line, and indicates where the mouth-opening will appear. Just posterior to this point the epiblast recurves around over the head to form the amnion, so that within five sections backward there is no epiblast on the ventral side of the body.

This manner of development of the notochord and hypophysis seems to point to some peculiar relation between the two organs. There are also other parts which are intimately related to these organs, namely, the muscular elements of the head, — primarily the head-cavities, which are developed from the mass of cells, *HC*.

The next older embryo which I have been able to examine is represented in the series of transverse sections, B. The mouth-opening has not yet appeared. The notochord in the head still lies close to the hypoblast, but the increased growth of the brain has lifted the mid-brain away from the notochord. In Fig. 19, B, is seen the ventrally curved portion of the notochord (*N*). In 20, B, — four sections farther backward, — is seen the dorsal wall of the intestine and its lumen (*AL*).

Anteriorly, at the base of the fore-brain (*FB*), appears the recurved end of the notochord (*N.*) in cross-section; and laterally from it, extending partly around the base of the fore-brain on both sides, is a double wall of cells (*CZ*), pressed close together for a distance, but separating distally to form a lumen. This lumen is enclosed by the distal union of the two walls. The cavity is round, excepting a conical point at the place where the two walls separate; so that proceeding toward the notochord the lumen gradually disappears, though the walls remain distinct as far as to the notochord. An examination of the whole series shows the structure in question to be a rod-like body with a distal hollow enlargement. Meeting each other at the median line, the two parts enclose and fuse with the anterior extremity of the notochord. The hollow enlargement is the head-cavity. As I am unacquainted with any name for such a median connection of the head-cavities and notochord, I shall hereafter refer to it as the coelenteric zone.[1]

In the embryo of series B, that connection of the notochord and rudiment of the coelenteric zone with the epiblast has disappeared. In the embryo of series A, the cell-mass (*HC*) at the anterior end of the notochord was fused with the epiblastic roof of the hypophysis, and not completely separated from the hypoblast. In the present stage, however, the separation from the hypoblast is complete. Section 21, B (six sections behind 20, B), shows also that the separation of the notochord and the coelenteric zone from the hypophysis is complete, for here nothing but a thin band of the general interstitial tissue separates the intestine from the fore-brain anteriorly to the coelenteric zone. The second section behind this shows in tangential section the epiblastic roof of the hypophysis (*Hph*, Fig. 22, B) As in the preceding stage, it is in close contact with the base of the fore-brain. Three sections farther backward, Fig. 23, B, shows the oral fusion of the hypoblast and epiblast, also the laterally open cavity between the oral fusion and fore-brain, which becomes the cavity of the hypophysis. In Figs. 22, B,

---

[1] *Marshall* (On the Head-Cavities and Associated Nerves of Elasmobranchs. *Quart. Journ. of Mic. Sci.*, Vol. XXI., N.S., 1881) has described homologous and nearly similar relations as existing in the Elasmobranchs. *Van Wijhe* (Ueber d. vorderen Neuroporus, etc., Zoöl. Anzeig., pp. 683, 684) supposed, for theoretical reasons, that some such connection must exist or have existed.

and 23, B, it will be seen that the ventral flexure of the brain causes an angle to be formed between the ventral (or morphologically anterior) surface of the head and the external surface of the oral fusion and lower jaws. The apex of this angle of surfaces is seen in the line of epiblast, *Ed* and *Hph*, in Fig. 22, B. In 23, B, the space (*M.in*) enclosed by the angle is seen. The apex of the angle, therefore, extends from side to side of the head in nearly a straight line. As the brain and lower jaw increase in size, the angle becomes more and more acute. In Fig. 48, D, this angle (*M*) is shown in a lateral, longitudinally vertical section. In the median line, posterior to the apex of the angle, the mouth-opening breaks through. The lower jaw, thus released in the middle, curves outward, and, overlapping the epiblast anterior to the apex of the angle, it begins its growth forward, which eventually brings its median part to the nasal tip of the head.

Between the apex of the angle referred to and the dorsal edge of the mouth-opening there remains a small portion of the posterior epiblastic surface of the angle. This small portion of epiblast forms the posterior wall of the hypophysis; it is visible in Fig. 49, D, under the end of the notochord and posterior to the space *M*, and also in 50, D, — a slightly lateral section (*Hph*). Owing to the lateral twist of the head of the embryo, it is impossible to make a truly median, longitudinally vertical section; although section 49, D, passes through the median plane at the notochord, it cuts also the lateral boundary of the mouth-opening just behind the space *M* (Fig. 49, D). (I have omitted to reproduce this posterior wall of the hypophysis in the reconstructed section of Fig. 51, D.) As soon as the hypoblast separates from, and sinks down from the notochord, the characteristic appearance of the hypophysis becomes much more pronounced, and appears as pictured in Fig. 47. Here the hypoblast blends indistinguishably with the posterior wall of the hypophysis. The cavity of the hypophysis has meanwhile become enclosed laterally by the tissue at the sides of the hypoblastic mouth (*M*, Fig. 22, B) growing forward to form the upper jaw. The expansion of the head-cavities may possibly help to cause this effect. The later condition of the hypophysis may be seen in Figs. 33, C, and 34, C. Here the brain is increased very much in size, and a ventral distension of the lateral parts of the head has enclosed the hypophysis laterally, while its median roof has remained in its primitive position in contact with the same part of the brain where it first appeared. In the embryo of series C the hypophysis appears as a lateral, slit-like depression in the roof of the mouth. Later stages show that the growth of the surrounding parts gradually constricts the opening of the hypophysis to the mouth. The hypophysis appears then as a laterally distended body with extremities turned slightly upward, according with the curved surface of the brain, against which it lies.

The head-cavities having first appeared as already described, become large oval cavities, with walls of a distinct, compact, epithelial nature. Their position and relations may be seen at *HC*, in Figs. 2, C, 34, C, 35, C, 36, C, and 48, D. The nerves of the third pair enter their dorsal posterior walls (*CZ*, Fig. 34, C). At a late period in the duration of the head-cavities, at that end of each cavity nearest the mouth, a transverse constriction appears in the median wall, as if the cavity were to be divided into two,—one smaller anterior and one larger posterior cavity. Whether such a division really takes place I have been unable to prove, for very soon after the appearance of the constriction the whole cavity seems to disappear, its walls being converted into muscle. The constriction is interesting, as corresponding with a similar condition of the first head-cavities in the elasmobranch fishes.[1]

The coelenteric zone continues to exist for a considerable time, uniting the anterior ends of the head-cavities; it is still visible in stage C (*n III*, Fig. 34, C). Figs. 43, C, and 44, C, Pl. XV., represent two successive sections in the region of the coelenteric zone of the embryo figured at 2, C. In Fig. 43, C, a solid band of cells (*CZ*) connects the head-cavities (*HC*) above the hypophysis (*Hph*); and in the posterior section (44, C) is seen the anterior tip of the notochord (*N*) joining in the middle with the band (*CZ*). I have not discovered any later trace of the coelenteric zone. Immediately after this period it seems to become absorbed.

The preceding statements describe what seems to me to be the most common manner of development of the anterior end

---

[1] *Balfour.*—A Monograph on the Development of Elasmobranch Fishes. London, 1878.

of the notochord and the coelenteric zone in the embryos which I have examined; but as it is usual for degenerate rudiments of organs to present variations, so also the anterior tip of the notochord and the coelenteric zone apparently follow the general rule. To follow the lines of development of these variations would, of course, be impossible; but the description of a few stages will make clear the chief variations. In an embryo slightly older than that of series B, and in which the mouth-opening has broken through, I found the notochord anteriorly widely separated from the hypoblast. Only the anterior tip retains its fused connection with the roof of the hypophysis. The notochord, for a short distance from the tip backwards, is very crooked. Laterally from the tip of the notochord extends the coelenteric zone, also connected for a distance with the roof of the hypophysis. The lumen of the head-cavities extends into the coelenteric zone very near to the median line, as is shown by a sagittal section (47, Pl. XV.), two or three sections from the notochord. Other older embryos show that the coelenteric zone has entirely disappeared, while the anterior tip of the notochord still remains fused with the roof of the hypophysis. This condition I found in one embryo older than that of series C, and in another so far advanced that the head-cavities had entirely disappeared.

It might be supposed that in some cases the roof and posterior wall of the hypophysis are formed from the hypoblast, and that therefore the tip of the notochord has simply remained connected with the cell-layer from which it originated; but on this hypothesis it would be difficult to imagine an adequate reason why the tip should be bent out of line to retain this connection. The appearance of the hypophysis in all the embryos is so similar, that there is no reason to suppose a variation in its origin. In one instance I have shown it to be derived from the epiblast; this agrees with what has been found by authors on the embryology of other vertebrates. In the present case, the first appearance of the tip of the notochord, the coelenteric zone, and head-cavities is in the form of a small mass of cells, apparently budded from the hypoblast. This mass is fused with the epiblast. In some individuals the notochord and coelenteric zone separate from the epiblast at the same time, though retaining connection with each other. In other individuals the coelenteric zone separates from the epiblast much earlier than does the notochord, and disappears; while the notochord remains a long time connected with the epiblast or hypophysis.

3. *The Alimentary Canal.*

The alimentary canal in the youngest stage examined by me (series A) has already been described. I need only add that in the region of the mouth it appears laterally compressed, while behind the mouth it is dorso-ventrally compressed. Behind the region of the mouth the lumen appears everywhere of equal size as far back as the yolk-sack. No traces of gill-pouches have appeared.

The oral fusion of epiblast and hypoblast appears very early in the lizard. *Hoffman* has described it as present in an embryo with only two somites. *Balfour* has pictured the two layers in contact in this region in an elasmobranch embryo, of which the medullary groove is only a slight depression. It seems probable, therefore, that in these cases no mesoblast ever develops between the other two layers at the point where the oral fusion appears. If this supposition be true, the mouth-opening of the lizard presents a method of origin very different from that of the gill-clefts.

The gill-cleft rudiments first appear as paired pouch-like protrusions from the dorso-lateral parts of the alimentary canal (series B). They grow toward the epiblast, pushing through the mesoblast, which at first entirely surrounded the alimentary canal. The first and second clefts are the first to acquire an external opening. Then follow in order the third and fourth clefts (Figs. 30, C, and 31, C, Pl. XIV.). Behind the fourth there appears later a fifth rudiment, for which alone I have never detected any external opening. In longitudinal-horizontal section there may be seen in some embryos small rounded swellings of the epiblast on the lateral posterior corners of the gill arches. These were at first suggestive of gills, but are perhaps simply remnants of the breaking through of the epiblast. That part of the alimentary canal from which the gill-clefts open is, comparatively, extremely large, and may be supposed to indicate its condition at the time when it was functionally active, as part of the respiratory system.

On the ventral surface of this large gill chamber, intermediate to the regions of the first and second clefts, appears the first rudiment of the thyroid gland (Fig. 31, C). In horizontal section its outline is a circle. It is a compact thickening of the wall of the gill chamber, and its cells lie in a radiate position. Immediately ventral to it is the fork of the ventral aorta. In a later stage this round thickening of cells has become depressed in the centre, so that it has a lumen slightly constricted at its opening to the gill chamber. Later it appears entirely separated from the wall of the alimentary canal, and without lumen. Finally it assumes its usual shape and position, with its thin median part lying ventrally across the trachea, a little in front of the separating bronchial tubes.

After the breaking through of the primitive mouth, as already stated, the lower jaw, overlapping the primitive anterior surface (anatomical base) of the brain, grows toward the nasal tip of the head. The progress of this growth may be seen in Fig. 51, D, where the jaw is a little in advance of the hypophysis; and Fig. 63, F, Pl. XVI., where the jaw extends beyond the optic chiasma.

The lumen of the gill chamber gradually decreases posteriorly until, just behind the region of the fifth cleft-rudiment, the ventral half of the lumen seems to be obstructed by a transverse wall. Dorsally the lumen continues, but so small that a single one of its limiting cells would suffice to fill it. From this transverse, obstructing wall (*Tr*, Fig. 36, C) is developed the lung rudiment. First appears a small tube growing out posteriorly and parallel with the intestine. This tube soon divides into two similar tubes, which continue their growth backward, though separating laterally. All these tubes are provided with a lumen, and show the same columnar endothelium as the intestine. A distal expansion of these lateral tubes finally leads to the growth of two large bladder-like sacks. At one period, when these sacks occupy relatively the entire space intended for the lungs, they possess simple large oval cavities without any reticulation. They have, however, small ridges on their internal surface through which run blood-vessels. These ridges soon increase in size, and, extending into the cavity, cause the reticulation.

Behind the origin of the trachea, and opposite the posterior end of the heart, the liver and pancreas make their first appearance. They grow out toward the right side of the embryo as hollow diverticula of the intestine; and are almost opposite each other, the liver tending ventrally and the pancreas dorsally (Fig. 40, C, Pl. XV.). The liver is the first to assume a glandular appearance. It projects into the venal sinus, behind the heart, so that its relations to the circulatory system are about the same as those described by *Shipley*[1] in Petromyzon.

In Anolis, although the walls of the neurenteric canal appear distinct in my youngest stage, yet the lumen makes its appearance at a rather late period. The alimentary canal extends a very short space behind the allantoic diverticulum, and then bending upward, its lumen becomes that of the neurenteric canal. This region presents the usual features of the fusion of the three germ-layers. Ventrally, just behind the allantois there exists in an early stage a median elongated thickening of the epiblast. A solid mass of cells extending from the intestine is fused with this thickening anteriorly. This is the spot where the cloaca appears later; and, in view of the recent researches on the subject, I should judge it to be the last trace of the blastopore. The neurenteric canal remains open a comparatively long time. There is still a trace of it in embryos in which the tail extends behind the cloaca more than half the length of the trunk. Fig. 58, Pl. XV., represents a section through the tip of the tail of such an embryo. The section seems to be not exactly transverse. In the centre is seen the neurenteric canal (*NeC*); at the right are a few cells of mesoblast; and at the left a fused mass of mesoblast and hypoblast (*MHp*). Above the latter, and next to the ectoderm, is a small round body (*N*), which, when followed forward, approaches a central position, and is found to be the notochord. This appearance is very peculiar, and seems to indicate a very irregular and rudimentary condition. I have examined this part in only a few embryos at this stage, but found no two exactly alike. A little farther from the tip of the tail (Fig. 57) the medulla (*Md*), notochord (*N*), and caudal intestine (*AL*) become well defined. The caudal intestine sometimes shows a lumen, and sometimes is only a cord of cells, though with indications of a lumen. The meso-

---

[1] *Shipley.* — On some Points in the Development of Petromyzon Fluviatilis.— *Quart. Jour. of Mic. Sci.*, Jan., 1887.

blast (*Mp*) is also distinctly defined, with its usual shape dorsally but uniting ventrally below the intestine. Proceeding farther forward, the caudal intestine invariably becomes a solid cord, which gradually disappears. The condition of the tail at this point is shown in Fig. 56, which represents a cross-section just behind the middle length of the tail. From these facts I conclude that the caudal intestine continues to grow in the neurenteric region, even after its anterior part behind the anus has atrophied. The atrophy occurs from before backward, and for a time the proximal end seems to atrophy about as fast as the distal end grows.

4. *The Mesoblast and Primitive Kidney.*

The origin of the mesoblast has been described by the authors referred to in the introduction. I will only refer to a few points in its development. The origin of the head-cavities, which are homologous with the body-cavity, has already been described. The segmentation of the mesoblast into somites occurs from before backward, — the first somite appearing at just the distance behind the ear that would equal the space occupied by one somite. About the time of the segmentation of the mesoblast the dorsal part forming the somites becomes separated from the ventral part, which incloses the permanent body-cavity. On each side the walls of the body-cavity — the somatopleure and splanchnopleure — meet dorsally at an acute angle. The apex of this angle becomes divided off by a longitudinal constriction, and appears at first to form a continuous rod of cells more or less fused dorsally and ventrally with the adjacent mesoblast. This rod later becomes segmented. It is the "intermediate cell-mass," or rudiment of the Wolffian bodies, and has been described by *Weldon* in Lacerta muralis. In an embryo with four somites the parts of the mesoblast are crowded on each other, and are not very distinctly defined. In the posterior region of an older embryo, owing to the greater size of the body, the parts referred to are separated from each other and distinctly marked. In an embryo with nine somites the unsegmented mesoblast, slightly anterior to the region of the neurenteric canal, has not divided into dorsal and ventral parts. A little farther forward this division is taking place, and the "intermediate cell-mass" appears as pictured by *Weldon* (Figs. 15 and 17 of *Weldon's* article). Some of my sections show, also, that a part of the lumen of the body-cavity is enclosed by the intermediate cell-mass. When the constriction is completed, the lumen at first projecting into the intermediate cell-mass has disappeared. Farther forward the intermediate cell-mass in cross-section appears round, and is completely removed from the protovertebræ, though remaining in contact and fused with the wall of the body-cavity. Still farther forward this fusion disappears, and the intermediate cell-mass is segmented into the Wolffian bodies. The Wolffian bodies are much elongated, and extend in a dorso-lateral direction to near the epiblast, where they unite with the segmental duct. A lumen is visible in the most anterior of the Wolffian bodies, uniting with the lumen of the segmental duct. The gradation of all these changes is apparent in the consecutive sections from behind forwards.

Haddon[1] has recently summarized the facts and reasons for considering the segmental duct as a product of the epiblast. As most of the literature on this subject referred to by him, has been inaccessible to me, I give but a brief account of what I have found in this respect. It is best illustrated in the same embryo of nine somites, in which I have described the development of the Wolffian bodies. Near the region of the neurenteric canal, opposite that part of the unsegmented mesoblast which has not yet divided into a dorsal and a ventral part, there appears a small linear thickening of the epiblast. This thickening is the same on each side, and lies horizontally and a little above the level in which the intermediate cell-mass is to appear. Posteriorly this epiblastic thickening fades away; but in the direction of the head it becomes more marked, and appears in cross-section as a distinct semicircular clump of five to eight cells adhering to the epiblast. (In one embryo in which the epiblast is stained darker than the mesoblast, the cells in question took the deeper stain.) A little farther forward this thickening of the cells becomes gradually separated from the epiblast, and lies as a solid cord about midway between the epiblast and the rudiment of the Wolffian body. Still farther forward the cord of cells acquires a lumen, and lies in contact with the Wolffian body. It is now easily recognizable as the seg-

---

[1] *Haddon.* — Suggestion respecting the Epiblastic Origin of the Segmental Duct. — *Scientific Proceedings of the Royal Dublin Society* (read Feb. 16, 1887).

mental duct. Its size increases anteriorly, until in the body segments behind the heart-region it unites with the most anterior, and accordingly the oldest, Wolffian bodies, as above described. Later stages show that each Wolffian body becomes a much convoluted tubule, with the median end of its lumen separated by a thin membrane from a protruding pocket of the aorta, while distally its lumen connects with that of the segmental duct, which opens into the cloaca.[1] (See series B.)

In stages about the time the egg is laid may be seen the method of development of the mesoblast of the tail. In transverse sections through the anterior region of the large neurenteric canal, and just in front of it, the intestine presents a vertically oval lumen, with a wall of distinct columnar cells. In the dorso-lateral parts of the wall the cells are much elongated, and extend their free spindle-shaped ends outward. A band of similarly shaped cells on each side connects this part of the wall of the intestine with the corner of a triangular solid mass of mesoblast, which lies dorsal to the intestine between the neural tube and the epiblast. Aside from the cells just mentioned no others appear between the hypoblast and epiblast. A few sections farther forward this cell-proliferation ceases, and the mesoblast unites ventrally.

This derivation of the caudal mesoblast corresponds to a very general method of origin of the mesoblast, from the dorso-lateral walls of the alimentary tract. This appears also to be the method of origin of the head-cavities.

5. *The Circulatory System.*

The circulatory system of the lizard in these early stages presents but few peculiarities of difference from the accounts given of other lower vertebrates. In general it agrees with the description given by *Shipley* of the same system in Petromyzon.

In the space between the oral fusion and the opening of the head-intestine into the yolk-sack the splanchnopleures fold in-

---

[1] It was not at first my intention to treat of the primitive kidney in this paper. When I became impressed with the significance of what I described above it was too late to add new figures to my plates, which had already been sent to the lithographer. I hope to publish, at another time, figures illustrating what I have here described.

ward below the intestine, and unite the apical surfaces of the folds in the median line just ventral to the intestine. A little distance below this another similar in-folding takes place; and thus arises a tubular lumen enclosed by the splanchnopleures, between the head-intestine and the hypoblastic wall of the yolk-sack. Fig. 16, A, shows this organ in process of formation: *HT* represents the lumen of the tube, — eventually the lumen of the heart. Owing to the twist of the embryo the growth is very indistinct on one side. When the tube is completely enclosed, it becomes separate from the splanchnopleures above and below it. These, however, remain continuous with each other across the median line, above and below the tube. Later, the growth of the somatopleure and epiblast, encircling the anterior ventral part of the body, separates this tube from that layer of the splanchnopleure which is adjacent to the yolk-sack. The ends of the tube open to the spaces between the hypoblast and mesoblast. As the tube grows in size it folds over on itself and forms a ventral loop, assuming at the same time the appearance and functions of a heart (see Fig. 59, B, and series C). The pericardial cavity is by this time very large, extending forward to the lower lip of the mouth. Enclosed courses have also appeared for the circulation of the blood. The blood-vessels, for the greater part of the body, may be traced out in series C. At first, all the blood from the heart passes through the mandibular arteries which divide where the ventral trunk leaves the pericardial cavity. At this time none of the posterior arterial arches have appeared. The mandibular arteries empty into two dorsal arteries. Anterior to the confluence of the mandibular arteries with the dorsal arteries the latter are continued (with decreased lumen) forward into the head as the carotids. In the region of the Wolffian organs the two dorsal arteries become a single median trunk, but, again, in the tail appear as two distinct arteries. This paired condition of the dorsal arteries is interesting, from the fact that previous to the appearance of any walls to the blood-vessels, the blood-corpuscles are found throughout the length of the body in the paired spaces on either side of the notochord, these spaces being completely separated by the medulla, notochord, and hypoblast.

The cardinal veins are continued in unbroken course forward as far as the eyes. Just anterior to their confluence in the ductus cuvieri the cardinals give off on each side a vein that runs backward immediately dorsal to the Wolffian organs, and supplies each of these organs with a small vein running between the convolutions of the tubule.

6. *The Central Nervous System.*

The central nervous system in the earliest stage of my material has been already referred to. Its chief features may be seen in the transverse serial sections represented in Figs. 7, A, and 18, A, inclusive. In general appearance it is a long tube, anteriorly enlarged and curved ventrally. For a short distance at both ends the tube is open dorsally, toward the middle the walls meet dorsally, and in the middle region they are fused. In the posterior open part of the tube the wall is a single layer of columnar cells. Farther forward the lateral parts gradually become much thicker, and the nuclei increase in number; the cells no longer extend from surface to surface of the wall, but spindle-shaped cells appear internally. This condition obtains throughout the anterior part of the tube. The floor of the tube, however, remains permanently a single layer of cells. Owing to the laterally compressed condition of the tube, this arrangement is in some places difficult to observe, but it is well marked in the floor of the brain. The floor may thus be distinguished from the anterior medullary fold, which corresponds with the lateral walls.

At this stage may be seen the three anterior swellings of the tube which correspond to the hind- mid- and fore-brain. The latter is the part that is open dorsally. This opening extends from the division of mid- and fore-brain to the dorsal edge of the anterior medullary fold. In the lateral walls of this primary fore-brain appear internally small depressions (*Op*, Fig. 9, A), which are the first indication of the optic outgrowths.

The lateral walls of the neural tube are largest in the head, and taper gradually toward the posterior end of the body. In the fore-brain the lateral walls appear to grow most rapidly, so that by the time they fuse dorsally they enclose in diameter the largest part of the neural canal. The anterior medullary fold does not partake in this growth. Its growth ceases at an early period, and it seems to take no part in the dorsal enclosure of the fore-brain.

If we imagine a middle longitudinal axis running through the neural tube of this earliest stage, its anterior part would have a marked ventral and slightly posterior curve,[1] and would end at a median point on the inner surface of the anterior fold. The growth of the lateral walls continues chiefly in a dorsal direction, so that before their dorsal fusion takes place the lateral folds are about twice as high from the floor as is the anterior fold. This I have ascertained by a series of horizontal sections parallel to the axis of the fore-brain in a slightly older embryo of *Sphærodactylus notatus*. The dorsal growth of the fore-brain brings its middle longitudinal axis into such a position that its anterior end at the time of the dorsal fusion is a point about the dorsal edge of the anterior fold. For convenience sake I shall consider the axis as ending exactly at this spot. Fig. 45, Pl. XV., represents a section through the fore-brain of an embryo of sphærodactylus slightly older than the embryo of series A. This section runs just dorsal to the longitudinal middle axis of the fore-brain, and parallel to the same. It is also symmetrically horizontal to the back of the embryo; but this part is assymmetrical because of the lateral twist of the head. The fore-brain is not yet dorsally enclosed; a narrow slit (*o*) extends from the dorsal edge of the anterior fold to the division between fore- and mid-brain. The sections of this series which are ventral to the longitudinal middle axis show that part of the lumen of the fore-brain which is inclosed anteriorly by the anterior fold. The latter, at this stage, is of the same appearance and thickness as the lateral folds. Later, the floor of this part of the brain becomes the infundibulum. The rudiments of the optic vesicles (*Opv*) are comparatively very large. In the figure, the vesicle of only one side is seen; on the other side the section passes dorsal to the vesicle. The distal end of the vesicle bends slightly in a posterior direction. In the dorsal half of the fore-brain — *i.e.*, that part above the middle axis and the edge of the anterior fold — the anterior walls of the two optic vesicles are separated from each other by the narrow slit *o*. This slit, therefore, extends the entire dorsal length of the primary fore-brain, and down the anterior surface to a point between the rudiments

---

[1] The lateral twist of the head is here not taken into account.

of the eyes. This region would correspond in a much older embryo (Fig. 51, D), as nearly as can be estimated, to the space between the constriction of the brain, *c*, and the point *og*, which lies directly between the two hollow optic stalks. In embryos a little older than that of Fig. 45, but much younger than that of 51, D, there is a linear median fusion of the dorsal and part of the anterior wall of the fore-brain with the epiblast. Everywhere else the brain is separated from the epiblast. The latter consists of a single layer of cubical cells. This fusion extends exactly through the region of the slit above described, and indicates the line of the closure of the fore-brain. Along the middle region of the fusion is a linear external depression, — the last remnant of the slit. The fusion is perhaps more complete at its ends, but its general appearance has led me to the conclusion that the entire slit closed nearly simultaneously.

In view of what I have found to be the case in the embryos examined by me, I am at a loss to account for the statements of *Hoffman* in this respect. He has figured a median longitudinal, vertical section of the entire head of an embryo of Lacerta, in which in the middle dorsal region of the primary fore-brain there is a pore-like external opening of the ventricle, the adjacent brain-wall being continuous with the epiblast. This, he says, is the last point of the enclosure of the brain. The lateral twist of the head would make it impossible to obtain any such complete median vertical section in all my embryos of this stage. In my youngest specimen the morphologically vertical plane of the head is at an angle of about 45° to the vertical plane of the trunk. In later stages, sections parallel to the vertical, longitudinal plane of the trunk and hind-brain, but slightly to one side, would cut the slit (*o*) in the fore-brain obliquely, so that it would present in each section the appearance of a pore.

Shortly after the complete closure of the brain and its separation from the epiblast, its vertical median section appears as represented in the reconstructed section of Fig. 51, D. The epiblast is a thin membrane of flattened cells, and lies close to the roof of the brain. The roof of the hind-brain is also a thin membrane. There is no dorsal constriction between the hind-brain and mid-brain, but they are separated by a marked lateral constriction. The mid- and fore-brain are separated by an encircling constriction in the region *c*. The condition of the cranial flexure is here well illustrated. In the curved floor of the mid-brain (*MB*) there are peculiar transverse folds disappearing up the sides of the brain, — as though the curvature of the brain had compressed its floor into folds. This seems to preclude the hypothesis that the curvature is caused by a lack of growth in the floor of the brain.

In the middle of the anterior wall of the fore-brain, between the optic stalks, is a small transverse groove (optic groove, *og*). It has a very slight lateral extension, appearing only in about four sections. The position of the groove between the optic stalks seems to correspond to the anterior end of the slit above referred to, and to the dorsal edge of the anterior fold. Though I have not been able to trace out exactly and prove such an origin for the groove, yet I think there is little room for doubting that it is the last trace of the union of the lateral medullary folds, above the anterior fold. There seems to be no other plausible explanation for the presence of such a groove in this particular spot. This groove also appears in amphibian embryos. *Goette* has pictured it in Bombinator, and I have observed it in the frog and Amblystoma. In a median vertical section of an embryo of Amblystoma, just ventral to the groove begins an enlarged thickening of the brain-wall, which extends toward the hypophysis, and there thins out into the thin floor of the brain in the infundibular region. The position of this thickening in relation to the hypophysis characterizes it as the anterior fold. I cannot determine the relation, in this embryo, of the groove to the closure of the brain, as the latter has already taken place.

The eye is the first of the sense organs to develop, the second and third being respectively the ear and olfactory organs. The term "outgrowth" hardly conveys the full significance of the first appearance of the eye rudiment. In Fig. 45 it will be seen that the walls of the optic vesicles are parts of the lateral brain-wall, which remain in their primitive contact with the epiblast, while the other parts have sunk inward from the epiblast. This inward-sinking is continued until every part of the central nervous system is separated from the epidermis by the mesoblast, and only the eyes retain their original contact. At a later period mesoblastic tissue enters the eye-cup by the choroid slit, to form the vitreous humor; but this cannot be said to separate the eye from the epiblast. A proximity to the epiblast is a fundamental necessity for an organ of sight, and this has undoubtedly been one of the chief formative motives in the early growth of the eye. Figs. 45 and 46, Pl. XV., represent two early stages of the growth of the eye, the sections being cut nearly horizontal, and parallel to the longitudinal axis of the primary fore-brain. In Fig. 45 the optic vesicle extends laterally, with a slight posterior bend at the distal end. In Fig. 46 the greater part of the vesicle extends in a posterior direction, so that what is at first the posterior wall becomes later the median wall. This wall may be distinguished from the anterior wall, as the postero-median wall does not touch the epiblast. About this time the distal expansion of the vesicle makes the stalk appear as though dorso-ventrally constricted, the lumen being round. The postero-median wall develops a heavy pigment on its inner surface (toward the vesicle). If we presume the existence of an ancestral form with eyes, the outer surface of whose head corresponded with the present inner surface of the brain, then these pigmented spots would seem to indicate the position of those primitive eye-spots, which, as the brain became enclosed by the sinking in of the middle part of the head, first faced anteriorly and then laterally. On this supposition, the anterior parts of the brain-wall, thus brought between the primitive eye-surface and the epiblast, would, being nearest the surface, tend to assume the optic functions, and the primitive eye would thus degenerate. This idea is suggested by the fact that in the embryonic eye the anterior or external wall continues to grow and differentiate, while the postero-median wall atrophies. The general features of the development of the eye are so well known that I will here refer only to a few points. An examination of Figs. 45, 46, and series C and D, will show that the optic organs are not ventral outgrowths, as they appear to be in the adult brain, but are lateral outgrowths from the extreme anterior region of the primary fore-brain, so that the anterior walls of the optic stalks are in the same plane with the anterior surface of the fore-brain. The optic vesicle becomes compressed by the development of the lens, so that its walls touch, and it takes the shape of a double-walled cup, with an unclosed slit (choroid slit) at its anterior end immediately external to the distal end of the optic stalk. The relation of these parts and the development of the lens is illustrated in the figures just referred to.

The first development of the ear (*E*) and the olfactory organs (*Na*) is shown in the figures 59, B, Pl. XVI., and 41, C, Pl. XV. Both organs appear first as thickenings of the epiblast, which gradually become hollow, rounded depressions. The ear becomes later constricted off from the epiblast as a hollow spherical body, with its median wall touching the hind-brain (Fig. 24, C). At the same time its nerve reaches it from before. The nasal thickening receives its nerve before there is any appearance of a depression (41, C). The depression, which appears later, always remains externally open.

By the time the above-described changes have taken place, the brain has reached the stage of development which is illustrated in series C (Figs. 2, C, and 24, C, to 42, C). The line *P–s*, Fig. 2, C, indicates the plane of the sections. This series shows the rudiments of the anterior ten nerves of the head, with the exception of the fourth and sixth, which have not yet appeared. There is still no trace of nervous fibres in any part of the brain or spinal cord. The hind-brain (Figs. 24, C, to 29, C) is a slightly curved tube, with a triangular lumen much widened anteriorly, while posterially it blends into the spinal cord. The sides are thick, meeting almost at an angle ventrally; dorsally they become thinner, and from their edges a thin membraneous roof is spread almost flat across the top. Section 30, C, shows the narrow part between the hind-brain and mid-brain. From this point forward the mid-brain extends as a rounded swelling, and is cut almost transversely. The third nerve-pair springs from it ventrally. In Fig. 35, C, appears the infundibular region of the fore-brain (*FB.*). A slight elongated constriction separates the mid-brain from the fore-brain; this is seen in Figs. 38, C, and 39, C. This constricted region becomes the thalamencephalon, and in Fig. 42, C, is seen the dorsal constriction (*c*) marking off the region of the thalamencephalon from the dorsal swelling which later divides into the two lobes of the secondary fore-brain (*FB′*). Sections of more advanced embryos, showing the later growth of the brain, are figured at 6, Pl. XII., 52, E, Pl. XV., and 62, F, and 63, F, Pl. XVI. The explanations of the plates will show their relations to the parts just described.

Previous to the stage represented in series C, there have appeared in the lateral walls of the hind-brain and the region of the thalamencephalon a number of symmetrical constructions, giving the walls in horizontal, longitudinal, sectional an undulated appearance. *Kupffer*[1] has given a short account, without figures, of a similar condition in embryos of osseous fishes, but did not discover the relation of these parts to the cranial nerves. *Kupffer* has called these parts "Medullar-falten;" but as the word "medullary folds" has another English meaning, I have adopted for them the word "neuromeres." The general appearance of the neuromeres is shown in the sections of the hind-brain in series C. Each neuromere is separated from its neighbors by an external dorso-ventral constriction, and opposite this an internal sharp dorso-ventral ridge, — so that each neuromere (*i.e.*, one lateral half of each) appears as a small arc of a circle. The constrictions are exactly opposite on each side of the brain. Fig. 6, Pl. XII., shows the arrangement of the cells in the neuromeres at a very early stage. The elongated cells are placed radially to the inner curved surface of the neuromere. The nuclei are generally nearer the outer surface, and approach the inner surface only toward the apex of the ridge. On the line between the apex of the internal ridge and the pit of the external depression, the cells of adjoining neuromeres are crowded together, though the cells of one neuromere do not extend into another neuromere. This definition of adjacent neuromeres presents, in some sections, the appearance of a septum extending from the pit of the external depression to the summit of the internal ridge (*Spt*). This septum may be nothing else than those parts of cell-walls which form the boundary line of the neuromeres, and which are made conspicuous by lying in a straight line. Of the neuromeres in the hind-brain, five are distinctly marked with the above characteristics, and are of equal extent in length. The most anterior of these gives off (on each side) from its dorsal half a mass of ganglion cells, constituting the root of the fifth nerve. The second gives off ventrally, and at a much later period, the sixth nerve. The third neuromere gives off, in a manner similar to the first, the single ganglionic root of the seventh and eighth nerves. The fourth neuromere gives off no nerve, but the

---

[1] *Kupffer.* — Primare Metamerie des Neuralrohrs der Vertebraten, Sitzing d. Math', — physische Classe vom 5 Dec., 1885, München.

space lateral to it is occupied by the auditory vesicle, so that the fourth might be considered the original neuromere of the auditory nerve. The fifth neuromere gives off, also dorsally, the root of the ninth nerve. Immediately posterior to the fifth neuromere is another similar swelling, which, however, is not separated by so definite a ridge and depression from the posterior neural tube into which it blends. This swelling gives off, dorsally, the tenth nerve; so we are justified in calling it a neuromere. Anterior to the neuromere of the fifth pair of nerves, the lateral brain-wall continues forward in a long curve to the constriction marking the rear boundary of the mid-brain. At this constriction there is a slight external depression and internal ridge, thus giving to the region of the long curve (in a very young embryo) the appearance of a neuromere nearly three times as long as the posterior neuromeres. There is no nerve for this neuromere, unless we suppose that primitively some relationship existed between it and the fourth nerve, which arises at a very much later period in the region of the anterior limiting constriction. I know of no evidence to support such a view. At the time of the earliest development of the neuromeres which I have described, the mid-brain appears to be simply an enlarged neuromere. Anterior to the mid-brain in the region of the thalamencephalon are two neuromeres, which are similar to the characteristic neuromeres of the hind-brain, except that they never give off any nerves. Fig. 6, Pl. XII., shows these neuromeres in a more advanced embryo; anterior to them is the swelling of the secondary fore-brain. As the nerve-fibres in the brain begin to develop, the constrictions marking off those neuromeres, posterior to the division of mid- and hind-brain, gradually disappear. There are no neuromeres behind the tenth nerve. As the embryo approaches the time of hatching, the cartilaginous dorsal arches of the vertebræ seem to cause a regular constriction of the medulla; but at this time the dorsal and ventral fissures have appeared, and there are no ridges in the small central canal. This different appearance and apparently different origin do not allow any very direct homology of these parts of the medulla with the neuromeres of the brain. *Balfour* described certain internal swellings of the lateral wall of the hind-brain of elasmobranch embryos: "Swellings of the brain towards the interior of the fourth ventricle are in connection with the first five roots of the vagus and the glossopharyngeal root, and a swelling is also intercalated between the first root of vagus and the glossopharyngeal root." In his figure (Fig. 5, Pl. XVI., *l c*) there are no external marks of these divisions, and the "swellings" lie opposite the nerve-roots, while in the region between the nerve-roots there are internal depressions. In the lizard, on the contrary, in the region between the nerve-roots are internal ridges. The two conditions are thus very different; but possibly younger elasmobranch embryos might show a connection between these "swellings" and neuromeres.

As has already been mentioned, the greater number of the cranial nerves appear during the stages of development described in the preceding paragraphs. By examining a transverse section of the neural tube of the young embryo it will be seen that the lateral outlines are for a distance almost straight, and then meet dorsally and ventrally in rather sharp curves. In the region of the dorsal curve, on each side, the cells point laterally and ventrally from the inner to the outer surface, while the straight part of the wall has its cells directly transverse. It is in this region of the latero-dorsal curve that the cells which form the nerve-ganglion are proliferated from the neural tube. Without observing the actual moving process, it is a difficult point to decide; but all my sections lead me to believe that the cells are proliferated throughout the entire dorsal curve, retaining their connection with the tube, however, only at the lower end of the curve, which thus remains the permanent point of exit of the dorsal nerve-root. I find nothing to support the view that the permanent attachment of the dorsal nerve-root is secondary to the formation of the ganglion. The origin of the dorsal nerves in the brain seems not so simple as in the spinal cord, but is apparently of the same nature. Their earliest appearance, as observed by me, is figured at Fig. 5, Pl. XII.; a few cells of the ganglion of the fifth nerve lie adjoining the dorso-lateral part of the hind-brain, midway between two neuromeric constrictions. Excepting the optic, the third, and the sixth, the first nine pairs of nerves of the brain are exclusively of dorsal origin, *i.e.*, they first arise from the dorsal parts of the lateral brain-walls. The optic nerve has been in part described, and I shall again recur to it. The third and sixth pairs of nerves have a ventral origin nearly similar to the ventral roots from the spinal cord. Their point of exit will be described later. The first pair of nerves spring laterally from the anterior dorsal (nasal) tip of the primary fore-brain, and run a very short distance direct to the nasal thickenings of the epiblast, in which they end. The nerves of the third pair arise from the mid-brain ventrally, in the middle region of the cranial flexure, and pass directly to the dorsal posterior walls of the head-cavities. The fourth pair arises at a time much later than the stages on which this work is based, and is intimately related to the later histological differentiation of the brain. The fifth nerve, arising as already noticed, passes forward, dividing into a dorsal and a ventral branch. The latter loses itself in the denser tissues which give rise to the structures of the jaws. The dorsal branch (ramus opthalmicus) passes forward dorsally to the head-cavity, and ends close to the dorsal surface of the eyeball; later it gives off a branch to the anterior wall of the head-cavity. The sixth nerve passes directly from its ventral origin in the hind-brain to the ventral posterior wall of the head-cavity. The seventh nerve passes down behind the first gill-cleft. The eighth passes to the anterior wall of the auditory vesicle. The ninth nerve passes down behind the second gill-cleft. The tenth nerve passes to the median wall of the first somite, which lies dorsally intermediate to the second and third clefts. Shortly after its first appearance a dorsal longitudinal commissure may be seen extending from this nerve backwards through the region of about four somites. This longitudinal commissure is irregularly attached to the brain-wall by a number of small fibrous roots. Distally a few rudiments of nerves may be seen extending from it a short distance. Two ventral nerve-roots unite, at this later stage, with what I first described as the tenth nerve. These nerves, together with the commissure, represent the rudiment of the vagus. I have not followed their development in detail. Behind the vagus-rudiment all the nerves present the typical features of spinal nerves.

It is worthy of notice that between the neuromere of the fifth nerve, which sends a branch down behind the mouth-opening, and the neuromere of the seventh nerve, which passes down behind the first gill-cleft, there is an intermediate neuromere. Also between the neuromere of the seventh and the neuromere of the ninth nerve, which passes down behind the second gill-cleft, there is another intermediate neuromere. Therefore if we consider the visceral arches as indicating the metameres of the head, the latter do not correspond to the neuromeres of the brain.

The fibrous elements of the central nervous system appear first in the stages succeeding that of series C. The fibres seem to be formed from the contents of the cells, by the breaking up of the cell-nucleus and absorption of the wall; or in other cases by the attenuated prolongation of the distal pole of the cell. The first method seems to be the case with the lateral longitudinal fibres; but I have not been able to follow it with certainty, and cannot say whether it is preceded by a polar attenuation. My sections, however, show the breaking up of the nucleus, and the gradual disappearance of the cell-walls. The second method is the case with the fibres forming the continuous transverse ventral commissure. The cells internal to the lateral longitudinal band of fibres give off long filaments from their distal poles, which run ventrally to form the transverse commissure.

The first fibres to appear are a thin, superficial band of longitudinal fibres, in cross-section, extending around the ventral lateral corner of the neural tube. From this corner springs the ventral nerve-root, and the greater part of the fibrous band lies dorsal to this nerve-root. Shortly after the appearance of the ventral band a similar superficial band of longitudinal fibres appears on the dorsal lateral corner, with its lower edge at the point of exit of the dorsal nerve-root. In the spinal cord these two bands are at first very distinctly separate; but in the head they blend into a single band lying superficially, — lateral in the hind-brain and ventro-lateral in the mid- and fore-brain. The appearance of these bands in the spinal cord is represented at *vL* and *dL* in Fig. 66, Pl. XVI. The same figure shows how the distal poles of the cells internal to the longitudinal bands bend downward, sending out fibres which run around the ventral surface of the tube to the opposite lateral wall. These fibres form the transverse ventral commissure. They appear at the same time with the dorsal longitudinal band. The floor of the central canal is still a single layer of columnar epithelial cells. These cells appear to take no part in the formation of the fibres of the ventral commissure, which lies closely attached to the floor of the central canal. The fibres of this commissure seem to be simply attenuated polar outgrowths connecting the ganglion-cells of one lateral wall with the ganglion-cells of the other. In longitudinal section it may be seen that these fibres crossing the ventral surface of the tube run parallel with each other, and exactly at right angles to the long axis of the tube. I have not been able to find any trace of their bending horizontally to join the course of the longitudinal fibres. Whatever connection may take place between the transverse and longitudinal fibres, seems to occur only through the mediation of ganglion-cells. The ventral transverse commissure is continuous through the body-region, the hind-brain and mid-brain, as far forward as the ventral angle caused by the cranial flexure just in front of the exit of the third nerve-pair. Anterior to this angle is the infundibular region, where no nerve-fibres appear. The ventral commissure, in its upward lateral course, cuts off from the main mass a small bundle of ganglion-cells, which are marked *gc* in Fig. 67. From this continuous bundle of ganglion-cells spring the fibres which enter the ventral nerve-roots. The ventral lateral longitudinal band of fibres as it grows in thickness gradually extends upward until it meets and blends with the dorsal band, leaving only the small spaces where the fibres of the dorsal nerve-roots pass out from the main mass of ganglion-cells. Neither the longitudinal nor the transverse fibres enter the nerve-roots. In the cranial as well as in the spinal region the fibres which enter the nerve-roots pass from the neighboring ganglion-cells through the lateral band to the roots.

Fig. 67, Pl. XVI., represents a stage in the development of the spinal cord later than that of Fig. 66. In Fig. 67 it will be seen that the lateral bands have coalesced, and their continued growth causes on each side a ventral protuberance (*pt*). These protuberances gradually extend in a ventral median direction, and form the lateral walls of the ventral fissure. The ventral commissure remains the roof of the ventral (anterior) fissure. In this way the ventral commissure comes to lie eventually just below the middle of the cord. The dorsal fissure arises by the median compression of the lateral walls of the central canal, and the atrophy of the roof of the latter, so that at a slightly later stage there may be traced a straight line dividing the lateral halves of the cord, and running from the dorsal surface down to the remnant of the central canal. The remnant of the canal has a small round lumen, and is entirely surrounded by a columnar epithelium. It looks as if the compression of the walls had caused the edges of the original epithelium of the floor of the canal to curve upward and unite dorsally, thus enclosing a small lumen.

Fig. 67 also shows a few elongated cells isolated in the fibres of the middle lateral region of the ventral commissure. The fate of these cells I have not traced. The bundle of cells from which spring the ventral roots (*ar*) has increased in size and is more definitely marked. This bundle of cells, the ventral (anterior) gray column, gradually disappears on entering the hind-brain, and is not found in any region of the brain anteriorly. In no part of the brain is there a ventral extension of the lateral bands of fibres, like that which forms the ventral fissure of the cord. The transverse and longitudinal fibres, however, are conspicuous in the brain. The ventral edge of the longitudinal band is very distinctly marked. Between the ventral edges of the two longitudinal bands extend the transverse fibres, which run upwards laterally at right angles to, and apparently interlacing with, the longitudinal fibres. The definite endings of the transverse fibres of the brain I have not been able to find. Fig. 65, Pl. XVI., shows a part of a transverse section through the mid-brain, cutting the roots of the third pair of nerves. This section shows the ventral transverse fibres (*TF*), and, as has been before intimated, is just a little behind their anterior limit of extension. The section also shows the ventral edge of the longitudinal band (*LF*). Just on the edge of this band, fibres from the internal ganglion-cells pass outward, constituting the root of the third nerve. This method of origin, though not exactly similar, is at least homologous with that of the ventral spinal nerve-roots. The sixth nerve originates in exactly the same relations to the transverse and longitudinal fibres as does the third nerve. In the case of the sixth nerve, however, the fibres of the nerve-root pass out in two or three separate bundles, which unite first external to the brain surface in the cellular nerve rudiment.

Although the lateral longitudinal bands of fibres in the fore-brain possess the same fundamental features as in the posterior parts, yet their relations to certain commissures make it more convenient to treat of the fore-brain separately. As has been said, the ventral transverse commissure does not appear in the fore-brain. The main part of the lateral band, following the curve of the cranial flexure, passes along the ventral lateral wall of the fore-brain, and appears on the anterior surface of the fore-brain immediately ventral to the optic stalks. Fig. 52, E, Pl. XV., shows a section of the fore-brain cut at right angles to its anterior surface and immediately ventral to the optic stalks. The lateral band (*LF*) bends slightly dorsal to the plane of this section, and then, entering the plane again, passes in it around the anterior surface of the brain (*LF''*). At *LF''* the lateral longitudinal fibres unite, blending together so that this whole system may be described as a band of generally parallel fibres extending across the anterior surface of the central nervous organ and running posteriorly along its sides. At the stage represented in Fig. 53, E, there is only one other band of fibres in the region of the primary fore-brain, and that is the posterior commissure (*PCs*). Its general appearance is as if, on entering the fore-brain, a part of the fibrous mass had split off dorsally, and instead of following the curve of the cranial flexure these fibres continued across the dorsal surface of the brain just anterior to the mid-brain. In Fig. 52, E, the posterior commissure is cut obliquely near its point of separation from the lateral band. In Fig. 53, E (a section dorsal and anterior to 52, E), is shown the posterior commissure crossing the dorsal surface of the brain. Fig. 54, E, shows the first rudiment of the pineal eye, which arises a little distance anterior to the posterior commissure. Fig. 55 shows a section from an embryo of about the same stage as that of series E. This passes through the hypophysis (*Hph*) and fore-brain parallel to the anterior surface of the latter, cutting also the optic stalk (*O.st*), (cf. figures of series D). Immediately ventral to the optic stalk is seen the lateral band of fibres — in cross-section — just posterior to their meeting on the anterior surface of the brain. Outside the region of the bands above described no trace of fibres can be found in the brain at this stage; nor have any fibres appeared yet in the optic stalks. By comparing this description of the main band of longitudinal fibres with the description of earlier stages, it becomes evident that the main band of fibres follows the course of the primitive lateral and anterior walls of the medullary groove or tube. The band occupies a position corresponding to the external surface of these walls. In the spinal cord this identity of parts is at once evident; but in the head the dorsal dilatation of the primitive tube to form the swellings of the brain has left the band in a position relatively more ventral.

In the stages immediately succeeding that which has just been described, the fibres of the optic nerve make their appearance. *Hoffman* has stated that the fibres of the optic nerve form first on the ventral wall of the optic stalk. This is true according to a general and rather inexact terminology; but it is on the morphologically anterior wall of the optic stalk that the fibres first appear. The fibres of the opticus develop in a manner very different from the fibres of all the other nerve-roots. They are not polar elongations, nor do they originate in the internal ganglion-cells of the neighboring brain-wall. They are formed next the external surface of the anterior wall of the optic stalk and the lateral wall of the optic cup, in the same manner as the fibres of the lateral bands are formed. The fibres appearing on the anterior wall of the optic stalk are continuous with the dorsal edge of the anterior and lateral band above described, so that the fibres of the band appear to continue outward along the stalk. Fig. 61 shows a horizontal section through the optic stalk at right angles to the anterior surface of the primary forebrain. As the stalk does not lie exactly in a horizontal plane, the section cuts it obliquely. The stalk still has a lumen (*l*), and on its anterior wall (*op''*) are the nerve-fibres. There is no trace of fibres on the posterior wall (*op'*). At this stage I could not trace any decussation of the fibres from the opposite sides, — probably because the fibres run so nearly parallel. Fig. 60 represents a section through the anterior part of the eye-cup and part of the optic stalk, in the same plane as Fig. 61. This section shows the fibres *NF* developing on the anterior wall of the stalk (*op''*) and on the lateral wall of the eye-cup (*Ey'*). The fibres in the eye-cup do not spread equally in all directions, but extend chiefly in a posterior direction, which is the direction of the long axis of the cup. The lateral wall of the optic cup has increased very much in size; while the median wall has become very thin, and is in some places a mere membrane. The corresponding walls of the optic stalk are affected in a similar manner. The anterior wall, as it develops the fibres, increases in thickness. The posterior wall develops no fibres, but gradually becomes thinner. At a period when the two walls are still distinct, though the lumen has been obliterated by the growth of the anterior wall, the posterior wall is a thin layer of flattened cells, connecting the membraneous wall of the eye-cup and the cellular, non-fibrous brain-wall immediately dorsal to the lateral band. This thin layer of flattened cells is entirely free from fibres, and in stages a little older it has disappeared, excepting a wedge-shaped cellular projection of the brain-wall immediately posterior to the point where internally a conical depression marks the original median opening of the stalk-lumen (*l*), (cf, Fig. 61). The dorsal and ventral division of the anterior and posterior walls of the optic stalk corresponds originally with the line along which the lateral and median walls of the optic cup unite.

During the period of the development of the optic-nerve fibres and the formation of the chiasma, the brain undergoes considerable change. The parts of the brain already present become more pronounced, and the lobes of the secondary fore-brain appear. These changes are illustrated in Fig. 63, F. Anteriorly this section passes to the right of the fold which separates the ventricles of the two lobes (see description of figure). The dorsal anterior part of the primary fore-brain becomes dilated into a small, rounded swelling (*FB''*, Fig. 6). The anterior surface of this round dilatation extends to a point just dorsal to the optic stalks, where its boundary is marked by a constriction. A little later a small median groove appears in the roof of the swelling, dividing it into lateral halves. From this time on, each half continues its growth separately, leaving the originally slight groove as a deep cleft separating the two. Bearing in mind the foregoing descriptions, it is evident, from a comparison of Fig. 51, D, with Fig. 63, F, that the secondary fore-brain is a dorsal and not an anterior outgrowth. In this latter stage (63, F) the increase of the cranial flexure has brought the infundibular region relatively much nearer the floor of the hind-brain. The secondary fore-brain is shown at its largest vertical and longitudinal diameters in this figure.

Fig. 62, F, represents a section of the same series as 63, F, and in a parallel plane, but passing through the lateral wall of the brain. This section shows the lateral longitudinal band of fibres (*LF*) passing forward to meet the opposite band just vertical to the chiasma (*Ch*). A comparison of the distance between the ventral parts of the fore- and hind-brain in the two sections (62, F, and 63, F) will give an idea of the transverse curve of the ventral surface of the brain. Owing to this curve and the anterior diminution of the basal breadth of the brain, the lateral band passes out of the plane of section 62, F, before reaching the anterior surface of the brain.

Before the last trace of the lumen of the optic stalk has disappeared, the decussation of the fibres of the optic nerves becomes apparent. The fibres of the dorsal edge of the lateral band, as they pass across the anterior surface of the brain towards the root of the optic stalk on the other side, bend dorsally, and running along the anterior wall of the stalk spread over the lateral wall of the eye-cup. Where the fibres from opposite sides meet, those from each region resolve themselves into four or five flattened bundles, and cross in such a way that between each two bundles of one nerve lies a bundle from the opposite nerve. I have searched in vain for any traces of fibres running from the lateral band into the optic nerve of the same side. None such appear. At this time the chiasma lies within the general superficial surface of the brain, its flat outer surface corresponding with the surface of the brain, while its inner surface is rounded. The ventral edge of the chiasma is at first continuous with the dorsal edge of the anterior band (*LF*), but later a wedge-shaped growth of cells pushes in between the two edges. Fig. 64, F, is an enlarged view of the region of the chiasma in the same section that is pictured at 63, F. Here the chiasma (*Ch*) and the anterior band are seen still touching each other, while at the same time they are marked off from each other by a wedge-shaped protrusion of the cells of the brain-wall. Later this wedge-shaped protrusion increases in size, and completely separates the two parts in the median line. By following the courses of these two fibrous parts in the consecutive sections between sections 63, F, and 62, F, it is found that the anterior band (*LF*) is perfectly continuous with the lateral band (*LF*, Fig. 62, F), and that the bundles of the chiasma coming from the opposite optic stalk also unite and blend with the lateral band; while the bundles from the other lateral band run into the optic stalk of this side. In later stages the chiasma comes to lie outside the surface of the brain. At that time, in transverse sections the anterior band is very distinct, and is completely separated from the chiasma in the median line; but laterally the optic fibres from the chiasma run into the lateral continuations of the anterior band, *i.e.*, the lateral bands.

In Fig. 62, F, may be seen the posterior commissure (*PCs*) in lateral section. This is the only commissure of the brain which is complete at this stage. Its fibres are continued dorsally in a broad band lying superficially across the roof of the brain. At the anterior edge of this band is the rudiment of the pineal eye. The latter has acquired a lumen, but is otherwise unchanged from the condition shown in Fig. 54 E. Anterior to the pineal eye, the roof of the thalamencephalon is a thin layer of cubical cells; and just behind the lobes of the secondary fore-brain it shows a number of small, round, gland-like outgrowths. About half-way between the posterior commissure and the optic chiasma is a small band of fibres extending dorsally from the lateral band and ending in a point. (This is represented in the drawing, but not lettered.) None of these fibres cross over the roof of the brain. From its position, I judge this pointed band to be the rudiment of the superior commissure described by *Osborn* in several amphibia, and by *Shipley* in *Petromyzon*. About half-way between the rudiment of the superior commissure and the chiasma lies another band of fibres, extending dorsally into the anterior wall of the secondary fore-brain. At this stage I find no trace of these fibres uniting across the median line with fibres from the band of the opposite side; but they undoubtedly form, later, the anterior commissure. In embryos of the frog and Amblystoma, at a stage apparently corresponding to this stage of Anolis, I find the general features of the lateral and anterior bands, and their relation to the optic fibres, to be about the same as above described; but in the amphibian embryos the fibres which run dorsally from the lateral bands, just behind the optic stalks, unite across the anterior surface of the brain, forming a superficial commissure a short distance dorsal to the optic stalks; therefore I think there can be no doubt that the corresponding fibres in the brain of the lizard are the rudiments of the anterior commissure.

Whether the fibres of these dorsal commissures are continuations of the lateral longitudinal fibres, I have not been able to determine with certainty. The commissural fibres spread wider apart on entering the region of the lateral bands, so that their appearance is easily deceptive; nevertheless, many of them, perhaps the majority, continue downwards, crossing for a distance the lateral longitudinal fibres nearly at right angles, but not appearing ventral to the lateral bands. Their ultimate endings I could not find. The superficial position of these three commissures, — anterior, superior, and posterior, — their similar connections with the lateral bands, and their relation to the constrictions of the brain, suggest at this period a striking homology between them.

Before hatching, the brain of the lizard undergoes great histological changes, as well as changes in the relative size and position of its parts. The most remarkable of these changes is the great development of white matter, and the change in the character of the comparatively few remaining ganglion-cells. The tissues assume the complex appearance of the adult brain-tissues. Through these changes I have not followed the fate of the lateral and anterior bands. Their position remains up to about the time of hatching, still occupied by white matter, but this is not distinguishable from adjacent parts; and the courses of the fibres appear very complicated,— an appearance which is perhaps increased by the greater irregularity in the surface of the brain. The fibres of each optic nerve can be traced along the opposite wall of the thalamencephalon, where they gradually become indistinguishable, a large bundle of them apparently passing to a ganglionic kernel in the lateral wall of the thalamencephalon. The anterior and posterior commissures are at this time well marked, for they constitute the largest bundles of parallel fibres. The fate of the above-described rudiment of the superior commissure I have not discovered.

Although it is not my intention at present to follow out the later stages in the development of the brain, yet I wish to call attention to a feature of the secondary cranial flexure, which falls partly in the embryological period with which I have dealt. As seen in Fig. 2, C, Pl. XII., the hind-brain has a slight dorsally convex curve. The future roof of the mouth from the hypophysis to the nasal tip lies nearly at a right angle to the long axis of the hind-brain. In the fully developed individual this part of the mouth-roof lies nearly in the horizontal plane of the long axis of the body, and the primary cranial flexure has meanwhile increased. It is necessary, therefore, as the anterior part of the head approaches the straight line of the main body-axis, that the secondary cranial flexure should form a curve or angle of about ninety degrees. The manner of this bending is illustrated in Figs. 3 and 4, Pl. XII. In the region of the bend, the roof of the hind-brain is so thin that it offers comparatively no resistance to the mechanical changes of position of the lateral walls. Anteriorly and posteriorly, however, the walls are held in position by the thickened roof. Fig. 4 shows how the hind-brain (*HB*) bends ventral-wards, the ear being just behind the apex of the bend. Fig. 3 shows how, at the same time, the dorsal edges of the lateral walls are distended laterally at the apex, so that the roof of the ventricle presents the appearance of a rhomboid. If we conceive a pliable body of the same shape as the hind-brain, it is evident that by undergoing a similar bending it would present the same appearance. In the hind-brain the bend continues to increase. The posterior and anterior walls of the rhomboid approach each other, the median angles dividing the lateral walls becoming more obtuse, while the lateral angles become more acute. Finally, the two anterior and the two posterior walls lie approximately in two transverse straight lines and nearly touch each other. The reduced lumen presents the form of a cross. By this process the region of the elongated neuromere between the mid-brain and fifth nerve-pair, becomes the region of the cerebellum. The fifth nerve-pair springs from the lateral angles produced by this bend of the hind-brain. The ear, which now occupies a somewhat greater space, touches the mid-brain. The hind-brain has naturally continued its growth during this period, but its principal changes of form are produced according to the mechanical laws of flexion.

In some amphibian and teleost[1] embryos which I have examined, in various stages of early development, the process of the secondary cranial flexure seems to be very much abbreviated or almost obliterated. The first appearance of it consists in lateral angular outgrowths, or distensions of the walls in the

---

[1] I am indebted to *Mr. C. Earle* for kindly allowing me to examine his preparations of the different stages of the embryos of *Ctenolabrus*.

anterior part of the hind-brain. Thus, the lumen at this point acquires the same appearance of a cross as in the late stages of the lizard. The process of formation of this part in the lizard explains the angular outgrowths in these other embryos, and the lizard may be considered to represent in this regard the more primitive method of development.

PART II.

Certain phyllogenetic considerations give the development of the lizard a peculiar interest. The results of general morphology indicate that the elasmobranchs present a relatively primitive type of vertebrates,[1] distinct from the other lower forms in the fact that the latter have been more modified by degeneration and peculiar specialization. The development of the elasmobranchs appears also to be very primitive. The embryological development of the Teleostei seems to be partly abbreviated, and otherwise peculiarly modified and changed from a primitive condition. The same is true in part for the Cyclostomata and Amphibia.[2] The embryology of the lizard, which is probably next to the lowest form of amniota, resembles more closely the embryology of the elasmobranchs than that of any other forms of the icthyopsida. Moreover, the fact that the lizard has retained one organ — the pineal eye — in a condition much less degenerate than in all other living vertebrates shows that the lizard may be in some respects a very primitive form, in regard to this part of the nervous system, — even more primitive than the elasmobranchs. That other parts of the central nervous system would also be in a primitive condition seems a permissible deduction; but at the same time the retention of the pineal eye in the lizard shows how complicated is the subject of "higher and lower forms," and the determination of what is primitive, and also with what care one should receive deductions in this regard which are drawn from the supposed position in the phyllogenetic relationship. The history of the hypotheses in this connection, during the last decade, shows that we should not expect to find all the differ-

---

[1] *Gegenbaur.* — Das Kopfskelett der Selachier.

[2] Cf. *Gegenbaur's* review of *Goette's* "Entw.-gesch. d. Unke" in *Morphologisches Jahrbuch.* Vol. I.

ent organs in one animal to be primitive in the same degree. But wherever we find an organ in a condition which gives a clue to its original significance, and reasonably explains the largest number of variations of the organ in other animals, so that we may consider the variations as secondarily derived from the first condition,—such a condition would then deserve the attribute " primitive."

With this view in mind, my own work has naturally led me to a consideration of the different hypotheses as to the origin of vertebrates, and what bearing the evidence before me had on the theories. The comparison of my own results with those of other investigators suggested also explanations of some features generally obtaining in the embryological period with which I have dealt. I do not wish, however, to be understood as considering these theories or explanations in any way perfect or ultimately satisfactory. The discussion of theories of such wide bearing does not properly belong in scientific description; and for this reason, and partly for the sake of clearness, I have reserved these speculations for a separate part.

The hypothesis of the origin of the central nervous system from a pair of dorsally converged nerve-trunks is well known. It has received the approbation of *Balfour* and *Haeckel;* and *Hubrecht* also, for a time, supported it by forcible arguments. The value of the hypothesis lies therein, that it points out the Platyhelminthes as the group of invertebrates from which, on the one hand, by the dorsal convergence of the lateral nerves may be derived the vertebrate nervous system; and, on the other hand, by the ventral convergence of the lateral nerves may be derived the nervous system of *Huxley's* sub-kingdom annulosa. This theory has been strongly combated by the theory brilliantly expounded by *Dohrn* and his followers,—that the vertebrates are descended from annelid worms, accompanied by a process of inversion through which the ventral side became the dorsal side. Some of the arguments in favor of this latter theory concern the body-cavity and the distinct segmentations of the body; also in the annulosa the yolk-mass closes in on the dorsal side. The body-cavity is a fundamental anatomical feature in many animals, and in different groups its origin seems to vary, so that it is not necessary to suppose that it appeared at one time in one smaller group, from which it has been inherited. The same is true of the segmentation of the body, and is illustrated in the incipient rudimentary segmentation shown by *Hubrecht* to exist in the Nemertina. The aggregation of a yolk-mass is an embryonic feature, and appears much modified in closely allied forms. We must suppose that the character of a type is due to selection acting chiefly on older individuals, at least after the period when a yolk-mass is present. When the character of the type has been determined, the nutritious matter of the embryo seems simply to collect at that spot where it interferes least with the development of the important organs. In view of the variability of the yolk-mass in the vertebrata and annulosa, there seems to be no reason for supposing a connection in this regard between the two groups; no more than for supposing a connection between the so-called placenta of Salpa and the placenta of Mammals. While the above objections to the annelid-inversion theory have merely a negative force, there are certain positive objections, which are met with great difficulty. The first of these relates to the homologizing of the vertebrate brain with the œsophageal nerve-ring, and the supposition that the œsophagus once passed through the vertebrate brain. At one time this objection appeared to be met with the aid of the pituitary body and the pineal gland, but more recent researches have closed this means of escape and failed to open plausibly any other. The connection of epiblast and notochord ventral to the brain, which I have described, adds new strength to the objection, and makes it seem insurmountable. The second objection relates to the inversion of position. We cannot suppose here a lateral turning over after the gradual manner in which it is supposed that in certain forms of the echinodermata the vertical axis gradually became the longitudinal horizontal axis, and of which intermediate forms remain. The supposition that the lateral sides of the worm became dorsal and ventral leads to the conception of a form that is incompatible with our knowledge of the symmetry of animals and the locative relation of their paired organs to the line of the force of gravity. On the other hand, if we suppose the change to have been sudden, we meet with equal difficulty in conceiving a form of such peculiar instability that it could at once turn itself upside down, and place, relatively in a new position, organs which had arisen in their old position through a long course of phyllogenetic development. It seems, also, that peculiar changes of environment must be supposed in order to have made this sudden change of position permanent. Again, it might possibly be supposed that the ancestral worm gradually became insensible to, and unaffected by, the force of gravity; so that in motion and rest the morphological axes of his body bore no relation to the direction of gravity. But the influence of gravity on animals is so universal, that on the last supposition we are almost forced to imagine a temporary suspension of gravity. Perhaps the greatest objection to the annelid-inversion theory, no matter what method the inversion may be supposed to have followed, is the absence of intermediate forms, or traces of them. The most plausible methods — those of gradual, lateral, or longitudinal inversion, or gradual shifting of the organs — seem the most likely to have left intermediate forms or traces of them.

The theory of the dorsal approximation of lateral nerves has the advantage of being less specialized in its application. It is not dependent on such difficult tasks as showing how the œsophagus passed through the brain, or how a worm-like form became inverted. It can also refer to a general intermediate form. As a rule, those biological theories which are based on a few far-reaching facts, and allow greater scope for processes of which we are ignorant, but which are from analogies imaginable, are more trustworthy than those theories having perhaps equivalent facts, but which are yet absolutely dependent on detailed complicated processes of which we are equally ignorant, and which are less easily imaginable. The annelid theory has been skilfully adapted to explain certain particular details of vertebrate anatomy, — for instance, a relation of the vermicular locomotory appendages with setæ, to the paired and unpaired fins with their rays and spines. Such explanations give the theory a false appearance of strength; but it must be remembered that, until the main stumbling-blocks of the theory are cleared away, such explanations are comparatively valueless as support for the theory, and add almost nothing to our knowledge of the probabilities. The special application of the dorso-lateral nerve-theory has been attempted in no such degree as the above instance. Its possibilities of explanation remain chiefly to be tried. *Hubrecht*,[1] however, made valuable efforts in this direction, and indicated some of the possibilities.

The Nemertina have afforded the best basis for the application of the theory of the paired origin of the ventral nerve-cord, and also of the dorsal nerve-cord. *Gegenbaur*[2] says: "Although in most of them the longitudinal trunks run along the lateral edge of the body (imbedded within the muscular layers), in others (Oerstedia) they approach one another ventrally, and are distinguished by swellings at the joints, where nerve-branches are given off. *This is in anticipation of the future development of ventral ganglia*, the elements of which are already present in the longitudinal trunks. The ventral approximation of the longitudinal trunks shows us how the central nervous system got its ventral position, which becomes further developed by the formation of ganglia." *Hubrecht*[3] has found that there is a "sheath of ganglion-cells which uninteruptedly accompanies these trunks from their origin in the cephalic lobes down to the extremity of the tail in all genera without exception." *Hubrecht* has given reasons for considering the genus Carinella the most primitive of the nemertine group. Of the lateral nerve in this genus he says: "It is not surrounded by nerve-cells, as these form only an external coating to it. . . . This cellular portion in *Carinella* is also of a less compact nature than in those of more differentiated genera, and is everywhere in direct contact with the epidermoidal tissue." Here, then, we find a general resemblance to certain forms of the embryological development of the vertebrate medulla, in which each lateral half shows in cross-section a lens-shaped swelling of epidermoidal cells, on the inner surface of which, later, the longitudinal nerve-fibres develop. A glance at several different forms will make this clearer. *Balfour* (Comp. Embryol.) has given a figure, after *Kowalevsky*, of an amphioxus larva, in which the medullary plate is distinctly thinner along the median line. The same author (Elasmob. Fishes) has pictured the median thinner portion of the medullary plate of elasmobranch embryos with

---

[1] See *Hubrecht's* papers in recent volumes of the *Quart. Journ. of Mic. Sci.*

[2] *Gegenbaur.* — Elements of Comparative Anatomy. Translat.

[3] *Hubrecht.* — Zur Anat. und Physiol. des Nervensystems der Nemertinen. Kön. Akad. d. Wiss. Amsterdam — Researches on the Nervous System of Nemertines. — *Quart. Jour. of Mic. Sci.*, 1880.

about the same thickness as the general epiblast. Again (Comp. Embryol.), he has pictured the chick at eighteen hours with an epiblast of a single layer of cells, which only on each side of the median longitudinal portion is thickened to a double layer. In his paper, to which I have referred in the introduction, *Balfour* represents a somewhat similar condition as existing in Lacerta muralis, as does also *Weldon*. *Scott* and *Osborn*[1] figure the same in the newt, and I have observed it in Amblystoma. The most striking illustration, however, is that of Bombinator igneus, which is also very carefully described by *Goette*.[2] Few other authors have referred to this appearance in their text. It has apparently been usually considered that the medullary groove and canal were at this stage the primary feature, to which the nature of the walls was of secondary importance; yet it is more natural to consider the walls as primary and the lumen as incidental. *Goette* describes a double symmetrical rudiment of the nervous system. In the figure of the round cross-section of the embryo, the lateral halves of the rudiment appear as lens-shaped thickenings of the "nervous layer" of the epiblast. These thickenings are separated by a median portion of exactly the same appearance as the parts of the nervous layer adjoining the lateral edges of the thickenings. In the head the paired thickenings separate farther laterally, to unite as a transverse curved thickening in the most anterior part of the medullary plate. I give here, in his own words, *Goette's* explanation of this appearance: —

"Es lässt sich alsdann nicht verkennen, das der vom Axenstrange auf das obere Keimblatt ausgeübte Druck die Ursache für die ursprüngliche bilaterale Anordnung der Anschwellung desselben in ihrem mittleren Abschnitte ist. Aus der folgenden Entwickelung ergibt sich aber, dass damit keine wirkliche Doppelanlage im oberen Keimblatte gegeben ist. Denn indem jene Seitentheile auf Kosten der übrigen Ausbreitung der Grundschicht deutlicher anschwellen, nimmt dass sie über dem Axenstrange verbindende Mittelstück im Verhältniss zu jenen dünnen peripherischen Theilen an Machtigkeit zu, offenbart

---

[1] *Scott* and *Osborn.* — On some Points in the Early Development of the Common Newt. — *Quart. Jour. of Mic. Sci.*, Vol. XIX., N.S., 1879.

[2] *Goette.* — Entwickelungsgeschichte der Unke. Bombinator Igneus.

sich also als zu der gesammten Anschwellung der Grundschicht gehörig (Taf. III., Fig. 62)." P. 157.

Even in the rather compressed parts of the amphibian egg this pressure of the notochord is hypothetical. The existence of this originally bilateral arrangement of the nervous thickenings, in so many different forms, under different embryonic conditions, casts strong doubt on the explanation by pressure. It is also a questionable method of morphological reasoning, by which the original significance of a part is first explained by deductions from its ultimate condition. *Goette*, in his description of a later stage, refers to the subject again as follows: —

"Im Rumpftheile sind die seitlichen Anschwellungen soweit zusammengerückt, das sie als zwei mit ihren Rändern unmittelbar zusammenhängende Bäuche (Medullarplatten) erscheinen. Im Kopftheile, welcher sich viel langsamer und in geringerem Masse zusammenzieht, bleiben die seitlichen Anschwellungen mehr auf den Rand der Axenplatte beschränkt, während ein nach Breite und Dicke ansehnliches, nach unten konkav gebogenes Mittelstück die ursprüngliche Einheit der ganzen Platte gegenüber ihrer Entwickelung aus scheinbar getrennten Seitenhälften im Rumpftheile hervorhebt." P. 165.

This "Mittelstück" is the same part that I have described in the lizard as the anterior medullary fold. So far from disproving the bilateral separateness of the nerve-thickenings, it seems to me to strengthen that view. If there were no anterior union of the lateral nerve-thickenings, we should have in this case a nervous system without a homologue; but an anterior commissure is characteristic of the Platyhelminthes, and this affords ground for a comparison. I have shown in the lizard that the first nerve-fibres appear to develop in longitudinal bands along the internal surface of the lateral nerve-thickenings, and are likewise continuous with each other anteriorly. If we suppose a change in the chronological order of development, whereby the nerve-fibres should appear during the earliest growth of the lateral and anterior thickenings and before these latter had formed a tube, then we should have an appearance very similar to that described in Carinella, except that Carinella has the nerve-trunks lateral, while in the vertebrate embryo they are subdorsal or dorso-lateral. In the head, so great a similarity of the nervous systems of these two forms disappears, but the main feature — the anterior union of the paired trunks — remains. In both cases this anterior union of the paired trunks lies dorsal to the mouth, and in the vertebrate embryo it is also dorsal to the attachment of the notochord to the epiblastic hypophysis.

I have drawn the above comparison because it seemed to me to suggest a possible explanation of the primary condition of the nerve-fibres in the nervous systems of Amphibia and Reptilia, — in other groups observations on this point seem to be lacking, — a condition that appears later either to degenerate or to become so modified that it loses its primitive significance. The continuous band of transverse ventral fibres which I have described seems to be a secondary result of the close approximation of the lateral parts of the nervous system, and apparently is not derived from the median epiblast connecting the two parts. There are a number of minor points which seem to accord with this explanation, but it is unnecessary to enter into perhaps useless detail until the main features shall have been more widely and strictly tested.

Independent of any theory as to their origin, we have the fact of the primitive lateral-longitudinal and anterior band of nerve-fibres entering into peculiar relations with the optic organs. The condition which I have described suggests an explanation. The idea that the posterior or median wall of the optic vesicle may once have performed the function of sight has already been mentioned. Supposing this to have been the case, we would have, then, in each of the paired optic vesicles an organ homologous with the pineal eye of Lizards[1] and Petromyzon;[2] that is, there would be in each case a continuous part of the brain-wall lying between the true optic surface and the source of light. As the paired vesicles arise primarily within the region of the primitive longitudinal fibres, these fibres coming from behind would probably have run completely around the longitudinal periphery of the vesicle, and continued their course anteriorly to the lateral band of the opposite side. In this way the posterior median wall of the vesicle would be covered with fibres on its median surface, and, as is usual in simpler eyes, the cellular elements would lie between the nerve-fibres and the

---

[1] *Spencer.* — Pineal Eye in Lacertilia. — *Quart. Jour. of Mic. Sci.*, Vol. XXVII., N.S.

[2] *Beard.* — The Parietal Eye in Fishes. — *Nature*, July 14, '87, No. 927., Vol. 36.

light. The lens being developed in the epiblast would do away with a lenticular growth in the outer anterior wall of the vesicle. The outer anterior wall, as has been stated, is covered externally with fibres. If, going a step farther, we suppose the cellular elements of the outer anterior wall, being nearer the source of light, to have gradually assumed the optic function, we should then have an eye in which the nerve-fibres lay between the cellular elements and the light. The posterior median wall of the vesicle, having become useless, would degenerate, together with its nerve-fibres and the fibres connecting it with the brain along the posterior wall of the optic stalk. On the other hand, that part of the longitudinal fibres supposed to have been present on the outer anterior wall of the vesicle would remain as the optic nerve, and unite with the brain and anterior band of fibres along the anterior wall of the optic stalk. The origin of the remarkable conditions peculiar to the eyes of vertebrates is an extremely difficult subject to explain. The above explanation seems to me to accord best with the main facts, as I have found them in the lizard.

The cranial flexure is an almost universal feature in vertebrate embryos, and is of a nature so striking that it must have attracted the attention of all embryologists. One explanation of this feature generally given is, that it is due to unequal growth in the dorsal and ventral halves of the brain. But it remains a mystery what purpose this unequal growth subserves, and why it should cause such a peculiar curve in the entire anterior end of the embryo, — a curve which must later be rectified in part by the secondary flexure. I have remarked upon and figured certain transverse folds in the floor of the brain, where the flexure is greatest, which discountenance this theory as the sole explanation of the facts. Another explanation is, that the early and great development of the brain makes it necessary that it should partly roll itself together in order to accommodate itself to the space allowed it for storage. This seems hardly to explain why the curve should be almost universally of the same character, or why it should bend out of line the notochord and intestine. It is, moreover, improbable that a feature so fundamental in determining the shape of the adult brain and head should have been acquired simply to accommodate the wants of an early embryonic condition. The lateral twist of the head may be accounted for by this latter theory, but the twist is only necessitated by the cranial flexure, and all traces of it disappear in later stages.

Even the combination of these two explanations does not account altogether satisfactorily for the peculiarities of the cranial flexure. While they perhaps play a considerable rôle, there seems to be another primary element. The probabilities deduced from our knowledge of the facts point strongly to a primitive paired condition of the central nervous system. This is indicated by the facts which have previously been referred to, by deductions from the principles of phyllogeny, and by the paired condition of the adult cerebro-spinal system. This paired condition has been a recognized principle in nearly every theory of the origin of vertebrates.[1] It is best illustrated in Bombinator, where there are the two bands of thickened epiblast running dorso-laterally along the back, spreading apart in the head, and uniting anteriorly in a graceful curve. In all cases where we find a nervous system originating in the epidermis, and then, by sinking into the body, removing itself entirely from the external surface, we are forced to conclude that the primary motive is to protect the increasing delicacy of the nervous organ from the rough stimulus of contact with external objects. There is no reason to suppose a different primary motive for this process in vertebrates. The thinner median epiblast connecting the thickened bands is carried inward with the thickened parts, — probably owing to its relatively small size and its intimate association with the commissures connecting the lateral neural parts. The tendency of the lateral parts of the epiblast to unite above the neural parts is such that they carry with them toward the median line the lateral edges of the neural thickenings. Thus is formed first the medullary groove, to which so much attention has been paid, and finally the central canal. Why this canal should have remained open is utterly unknown, but it probably serves, or served, only a secondary purpose. During the period in which these changes take place the neural thickenings are the densest and most unyielding of the tissues of the

---

[1] *Hubrecht* ("Quar. Jour. of Mic. Sci.," March, 1887) describes a small median dorsal nerve in nemertines, and suggests its homology with the spinal cord. In view of the bilateral symmetry of the spinal cord, the attempt to derive it from a nerve so small and specialized seems hardly an advance toward the solution of the problem.

body. Observing thus the nature of these paired thickenings, and the curve in which they unite anteriorly, the question arises, May they not, to a certain extent, be influenced by the simple mechanical laws of flexion; and may not the anterior downward-bending be in part the result of the gradual approximation of the lateral edges of the paired thickenings? The following is *Goette's* description of these parts: —

"Am Schwanzende ist die Tiefe der Medullarfurche gering; in der Mitte des Rückens und beim Übergange in den Kopftheil nimmt sie merklich zu, indem die Rückenwülste in dem Masse als die ursprüngliche Rückenfläche einsank, sich heben. Bis zur Mitte des Kopfs flacht sich die Medullarfurche weider ab, indem die Hirnplatte an der Knickungsstelle gewissermassen hervorgedrängt, die Erhebung und Umwälzung der Wülste zurückgehalten wird. In der vorderen Kopfhälfte erheben sich die Wülste wieder bis zu ihrer vorderen bogenförmigen Vereinigung, wo ihre Umwälzung zugleich am stärksten ausgebildet, der Grund der umschlossenen Einsenkung am meisten in die Tiefe gedrückt ist. Jener hervortretende mittlere Theil der Hirnplatte verdeckt aber den Eingang zu der davor und darunter entstandenen Tasche und lässt die Richtung und Ausdehnung derselben, mithin die starke Umbiegung der Hirnplatte leicht übersehen. Da nun die Rückenwand des Embryo während der bisher geschilderten Entwickelung in ihrem Dickendurchmesser sich nicht wesentlich verändert, also ihre Axe sich der Oberfläche analog verhält, so kann man an dem medianen Umrisse der letzteren die Umbildung der ursprünglichen halbkreisförmigen Rückenaxe verfolgen. Wenn diese Bogenlinie in zwei gesonderten Abschnitte sich gerade streckt, d. h. mit den betreffenden Sehnen zusammenfällt, so müssen diese beiden geraden Linien unter einem Winkel zusammenstossen, die ganze ursprüngliche Linie ein Knie bilden." Pp. 169–170.

A small strip of paper, if not too stiff, will afford a means of comparing the above description with the same manner of bending a pliant body of a somewhat similar shape.

This is illustrated in Diagram II. At A is represented a flat strip with its ends (*s*) held parallel. By approaching the upper edges of these ends until they touch in a straight line, the form B is produced, — *a* representing the anterior curve. If now the lateral edges of the two stems be moved upward toward each other in the median line, the primary inner (shaded) surface becomes the external surface, while the anterior curve (*a*) bends as seen at C. The relations of the surfaces in the region of the curve, in C, are not the same as found in the embryo, for the primary outer surface still faces outward. If, however, the upper edge of the anterior curve be held inward at the same time that the two ends are brought flat together, a form is produced similar to that represented at D. Making allowances for the difference in texture and in the surrounding media, the form D permits a comparison with *Goette's* description of the neural growths in Bombinator. At *k* is seen the "Knickungsstelle" and "hervortretende Hirnplatte," and at *a* is the "Tasche" to which he refers. Could the primitive lateral and anterior bands of nerve-fibres which I have described in the nervous system of the lizard be removed entire, their form would correspond almost exactly with the form D. The supposition that the cranial flexure may have been partly caused in the manner just described, agrees with the fact that in the amphibian and lizard embryos the primary cranial flexure forms during the period of the closing in of the medullary groove. I judge, from *Balfour's* description, that this is also the case in the elasmobranch embryo. In other accounts relating to this subject, the attention not having been directed to this point, the descriptions of it are too obscure to admit of certainty. I have previously referred to mechanical influences in the secondary cranial flexure.

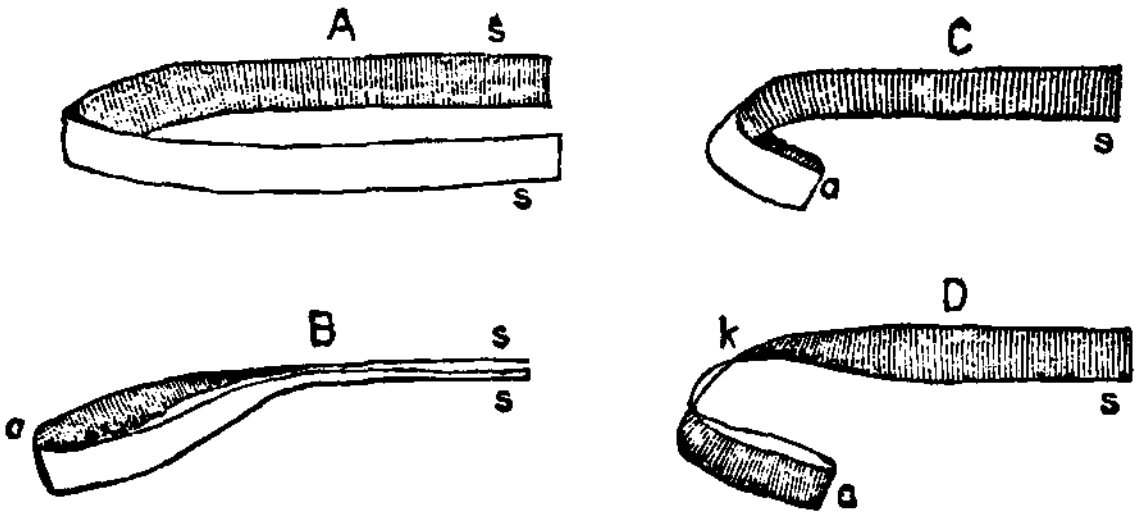

DIAGRAM II.

The connection of the notochord with the hypophysis in the lizard is a point worthy of mention. The exact relations of the anterior end of the notochord have rarely been traced out in all the early stages of development, and it is possible that more extended investigations of this part might throw light on the nature of the notochord. *Shipley* has recently described in Petromyzon the anterior end of the notochord as " being in contact with the posterior end of the nasal invagination." *Hubrecht*[1] has ingeniously suggested the derivation of the notochord from the proboscidean sheath of nemertines. If this view be accepted, the connection of the notochord and hypophysial invagination would apparently add weight to it, especially since *Heape*[2] has shown that at one period the notochord is tubular in the mole, and that its anterior end is also at first fused with the epiblast.

In conclusion, I wish to add, as apology for having entered the field of speculation, that in so doing my desire has been simply to call attention to points that seem worthy of future investigation.

---

[1] *Hubrecht.* — On the Ancestral Form of the Chordata. — *Quart. Jour. of Mic. Sci.*, Vol. XXIII., N. S. 1883.

[2] *Heape.* — The Development of the Mole (Talpa Europea). — *Quart. Jour. of Mic. Sci.*, Vol. XXIII., N. S. 1883.

EXPLANATION OF PLATES.

INDEX–LETTERS.

A. Artery.
AF. Anterior medullary fold.
AL. Alimentary canal.
Am. Amnion.
Ao. Aorta.
ar. Anterior spinal nerve root.
CC. Canalis centralis of the medulla.
c. Dorsal constriction in the region of the thalamencephalon.
Ch. Chiasma of optic nerves.
CS. Choroid slit.
[1] *CZ.* Coelenteric zone.
d. Dorsal point of union of medullary folds.
dL. Dorsal longitudinal fibres of the medulla.
E. Ear.
Ed. Epidermis.
Ep. Epiblast.
Eph. Epiphysis.
Ept. Epithelial wall.
Ey. Eye. Ey''. Outer wall of eye-cup. Ey'. Inner wall of eye-cup.
FB. Fore-brain. FB', rudiment of secondary fore-brain, and FB'', of thalamencephalon.
g, Ganglion of spinal nerve.
gc. Anterior gray column.
HB. Hind-brain.
HC. Head-cavity.
Hep. Liver-rudiment.
Hph. Hypophysis.
HT. Heart. *HTa.* Atrium. *HTv.* Ventricle of heart.
Hyp. Hypoblast.
in.FB. Infundibular region of fore-brain.
LF. Longitudinal fibres of walls of the medullary tube; LF'', the same uniting anteriorly.
LJ. Lower jaw.
M. Mouth.
MB. Mid-brain.
m.b. Muscle-bud.
Md. Medulla.
Mes. Mesoblast.
MF. Medullary folds.
MHp. Mass of indistinct mesoblast and hypoblast.
M.in. Mouth involution.
Mp. Muscle somites.
N. Notochord.
Na. Nasal thickening of epidermis, with rudiment of *N* olfactories adjoining.
Ne.c. Neurenteric canal.
NF. Nerve-fibres.
NM. Neuromeres. NM'. Neuromeres of fore-brain.
[1] *nIII*, *nV*, *etc.* Third, fifth, etc., cranial nerves. nV_1, nV_2. First and second branches of the fifth nerve.
o. External opening of the primary first ventricle.
Œ. Œsophagus.
og. Optic groove.
Op. Wall of optic vesicle. Op' posterior and Op'' anterior wall of optic stalk.
Opv. Optic ventricle.
O.st. Optic stalk with lumen.
Pan. Rudiment of pancreas.
PC. Pluero-pericardial cavity.
PCs. Posterior commissure.
P–S. Plane of section.
PT. Pleuroperitoneal cavity.
pte. Ventral downgrowths of spinal cord.
PV. Protovertebræ.
So. Somatopleure of mesoblast.
Sp. Splanchnopleure of mesoblast.
Spt. Neural septa.
T. Tail.
TF. Transverse ventral fibres.
TH. Thalamencephalon.
Thg. Thyroid gland.
Tr. Rudiment of tracheal tube.
v. Vein.
vL. Ventral longitudinal fibre.

---

[1] In Fig. 34, C., the index-letters *CZ* should stand in the place of *nIII*, and *nIII* should be in the place of *CZ*.

Wb. Wolffian body.
Wd. Wolffian duct.
wHC. Wall of head-cavity.
x. Break in the embryo.
y. Lateral nerve-cells giving rise to transverse fibres.
I, II, III, etc. Hyoid and following gill-clefts.
Iv'. Primary first ventricle.
IIv. Ventricle of mid-brain.
IIIv. Ventricle of hind-brain.

Where a number of figures represent sections, or the entire view, of the same individual embryo all those figures have the same letter affixed to their numbers.

All figures of sections have been drawn with the Abbey camera lucida and a Zeiss microscope, —*Z. 2. A.* means, Zeiss ocular 2 and objective *A*, etc.

PLATE XII.

FIG. 1, A. — Young embryo viewed from beneath, in which the medullary folds (*MF*) have coalesced only in the dorsal region. The tail (*T*) is broken at *x*. Iv^1, primary first ventricle. *MB*, mid-brain, *N*, notochord. *PV*, protovertebræ. *Mes*, unsegmented mesoblast.

FIG. 2, C. — Embryo much more advanced than Fig. 1, A. *FB*, *MB*, *HB*, fore-, mid-, and hind-brain. *HT*, heart. *Ey*, eye. *HC*, head-cavity. *Hph*, hypophysis. *NM*, neuromeres of the hind-brain. *E*, ear. *I*, *II*, *III*, hyoid and two succeeding gill-clefts. *M*, mouth. *P–S*, Plane of section for series of figures 24, C — 44, C.

FIG. 3 and FIG. 4. — Dorsal and side view of head of an embryo, showing secondary cranial flexure in the hind-brain with the concomitant distending of the walls. *HB*, hind-brain. *E*, ear. *TH*, thalamencepalon.

FIG. 5. — Left wall of the medullary tube in the region of the fifth and sixth nerves, shown in longitudinal-horizontal section. $nV_{1, 2, 3}$, not of the trigeminus nerve. *NM*, neuromeres. *Spt*, lines of division between the neuromeres. (These lines have not been strongly enough marked in the plate.) (*Z. 2. D.*)

FIG. 6. — Horizontal section dorsal and parallel to the axis of the primary fore-brain; showing the neuromeres (*NM*) of the thalamencephalon (*TH*). FB'', secondary fore-brain. *MB*, Mid-brain. This embryo is further advanced than that of series C. (*Z. 2. A.*)

1.A

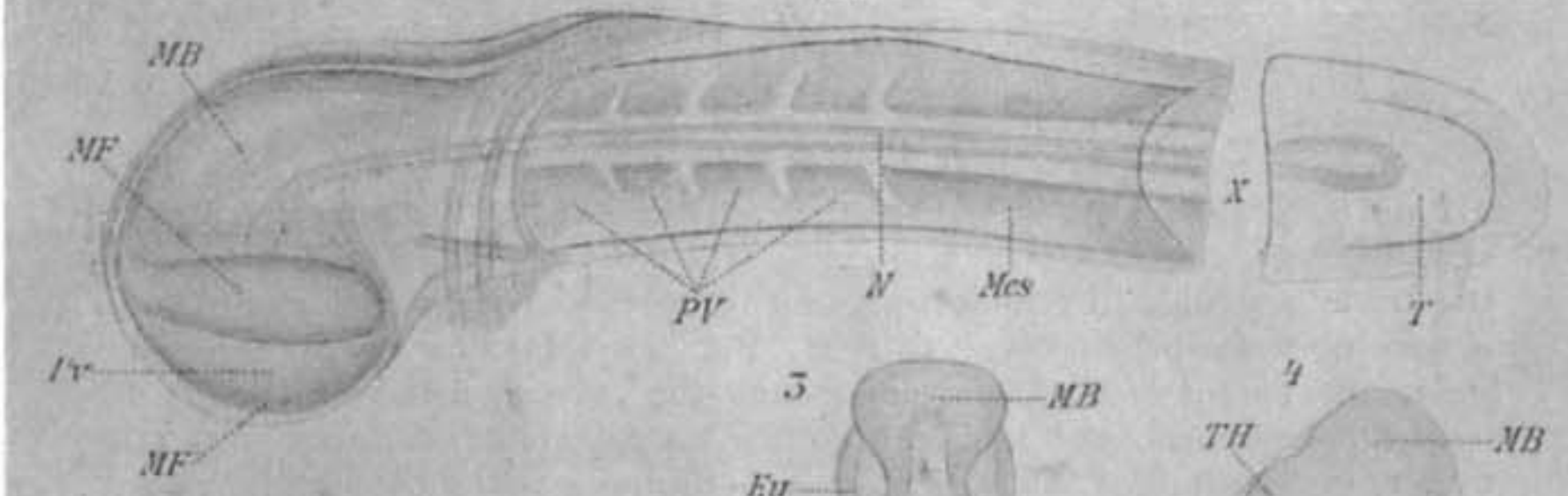

3.

4.

2.c

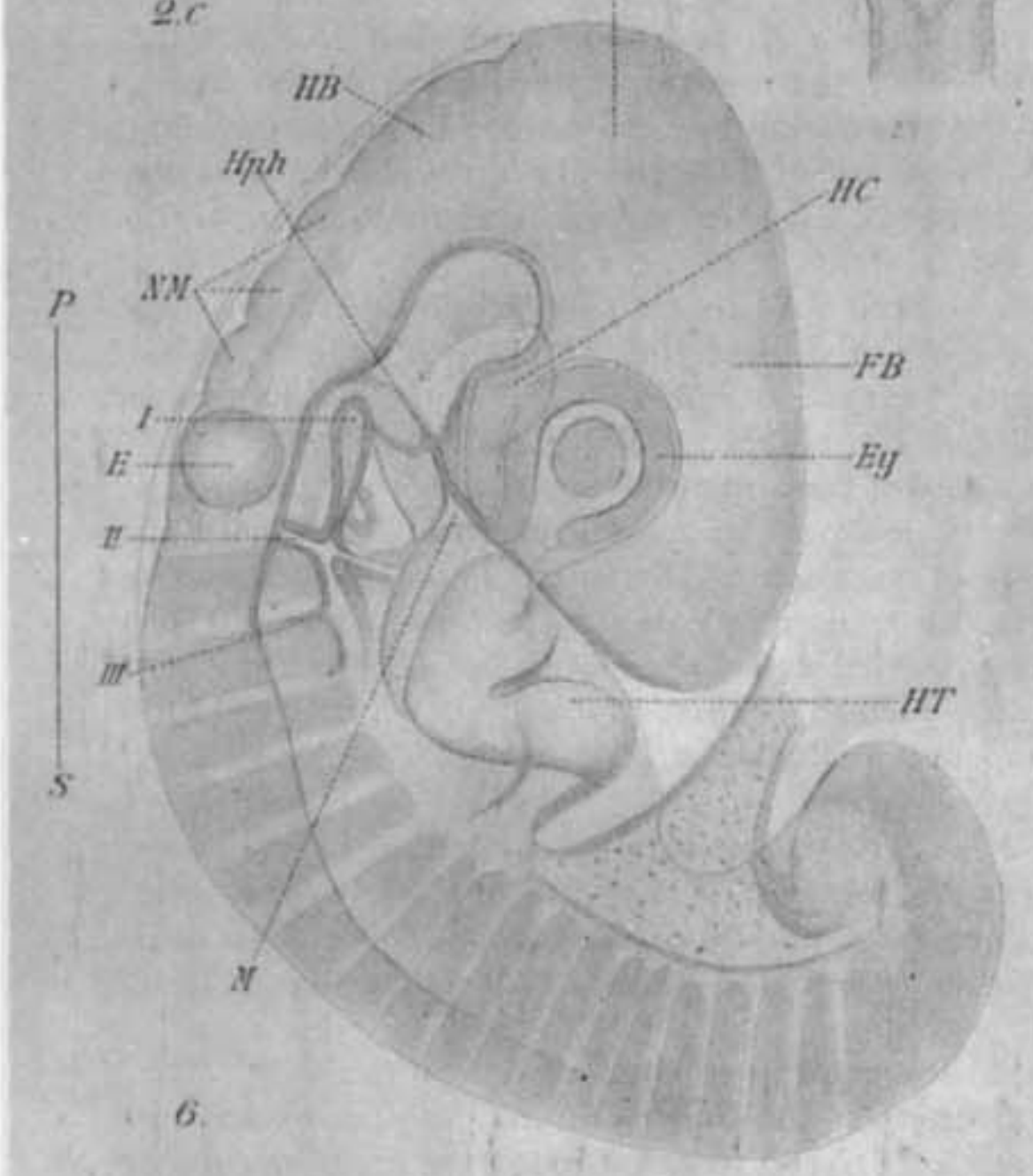

5.

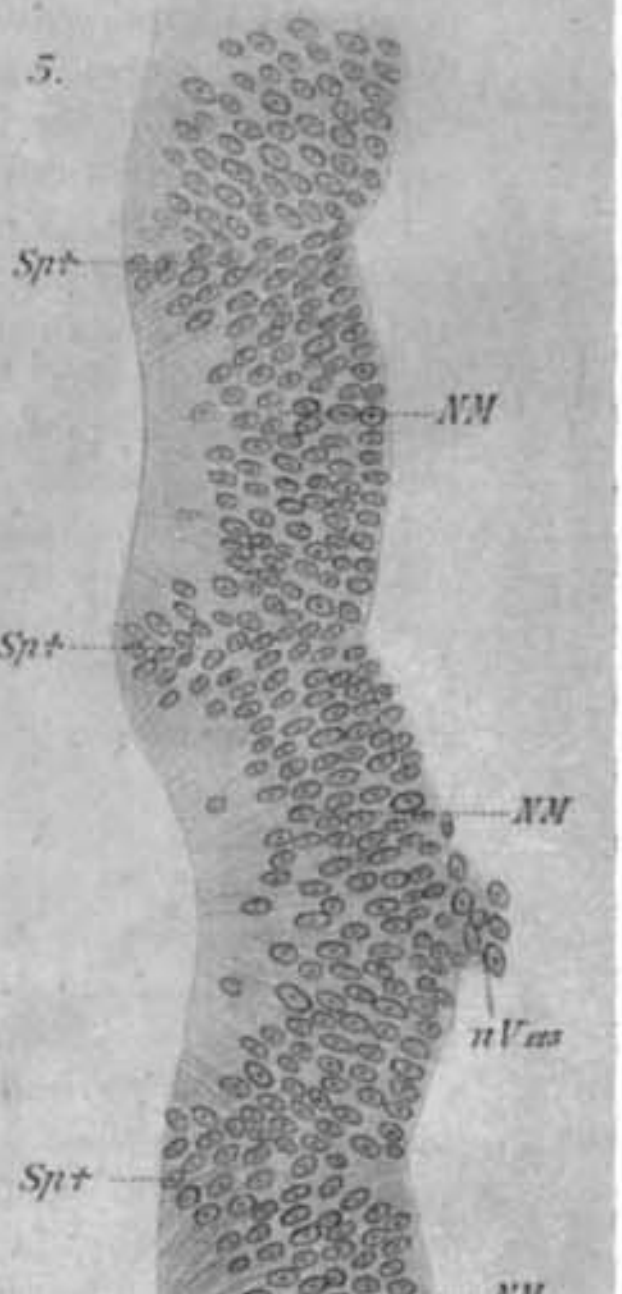

6.

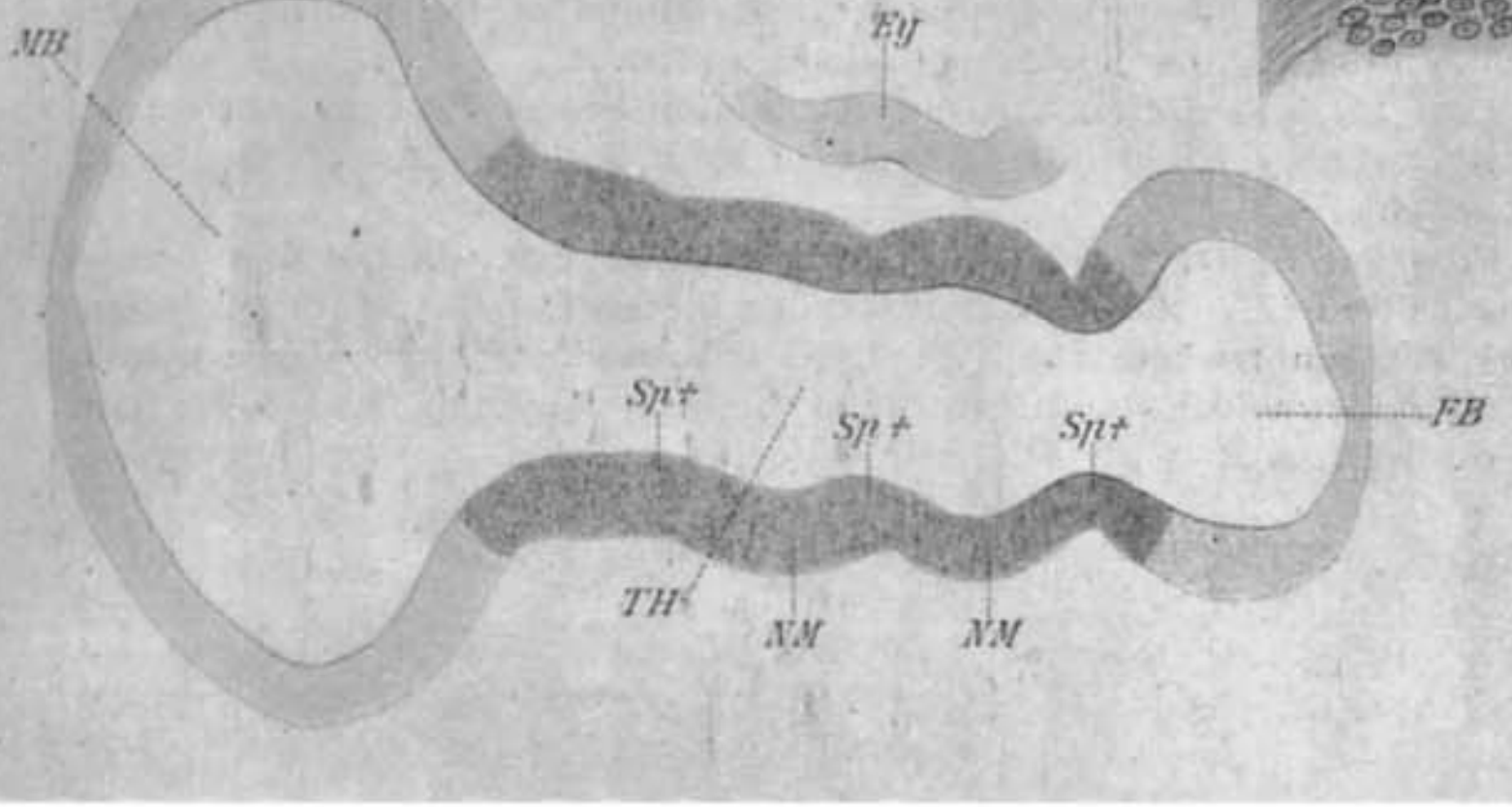

Orr ad nat. del.
Lith. Anst. v. Werner & Winter, Frankfurt a/M.

PLATE XIII.

FIGS. 7, A, 8, A, 9, A. — Sections through the head of the embryo figured at 1, A, cut transversely to the main long axis of the embryo. Fig. 7, A, shows the medullary folds (*MF*), meeting to enclose the cavity of the mid-brain, *o*, opening to the primary first ventricle. Fig. 8, A. — Section passing through the middle height of the canal connecting the primary first ventricle (*Iv'*) with the ventricle of the mid-brain (*IIv*). *Ep*, epiblast; *d*, dorsal point of union of the medullary folds. Fig. 9, A. — Section passing through the floor of the canal connecting the primary ventricle of the fore-brain with that of mid-brain. *Op*, hollowed part of the wall of fore-brain, which becomes later the optic vesicle. *Mes*, mesoblast. (*Z. 4. A.*)

FIGS. 10, A, 11, A, 12, A. — Series A, continued: sections in the same plane. 10, A. — Section touching the ventral outer surface of the brain, tangential to the curve of the ventral surface caused by the primary cranial flexure. *A*, artery. 11, A, 12, A. — Sections passing through the anterior curved portion of the notochord (*N*). *IIIv*, ventricle of hind-brain. *HC*, rudiment of head-cavity. (*Z. 4. A.*)

FIGS. 13, A, 14, A, 15, A. — Series A, continued: sections in the same plane, through the head in the region of the blind end of the alimentary canal and the mouth. *AL*, alimentary canal. *N*, notochord. *AF*, unpaired anterior medullary fold. *Am*, Amnion. *Ep*, epiblast. *HC*, part of rudiment of head-cavity fused with epiblast and wall of the alimentary canal. *Hph*, rudimentary roof of hypophysis. *Hyp*, hypoblast. *Mes*, mesoblast. *M.in*, mouth involution. *So*, somatic layer of mesoblast. *Sp*, splanchnic layer of mesoblast. *Ep*, in Fig. 14, A, is the epidermis covering externally the anterior medullary fold; it is also the proximal wall of the mouth involution; the distal wall of the mouth involution is formed by the amnion folds Am' (Fig. 14, A) bending outward and forward, and finally meeting, as in Fig. 15, A, about Am'. (*Z. 4. A.*)

FIGS. 16, A, 17, A, 18, A. — Series A, continued: sections in the same plane, through the regions of the heart (*HT*), of the opening of the head intestine to the yolk-sack, and of the middle of the back. *CC*, canalis centralis of spinal cord. Other letters the same as in preceding figures. (*Z. 4. A.*)

FIG. 19, B. — Series B is cut transversely to the long axis of the body. The embryo is older than that of series A; the embryo figured in series B having nine protovertebræ. The section (19, B) passes through the anterior curved part of the notochord (*N*), and through the head-cavities (*HC*), whose walls (at *CZ*) are prolonged towards the anterior end of the notochord. *HB*, hind-brain. *FB*, fore-brain. *A*, artery. (*Z. 2. A.*)

FIG. 20, B. — Section through the anterior end of the alimentary canal (*AL*). Other letters the same as in 19 B and the rest of the series. (*Z. 2. A.*)

FIGS. 21, B, 22, B, 23, B. — Sections in the region of the first visceral (hyoid) cleft (*I*). *Ed*, epidermis forming the roof of the mouth involution. *Hph*, the point where the hypophysis is formed. *M*, hypoblastic mouth. *M.in*, epidermoidal mouth involution between fore-brain and lower jaw. *E*, ear. (*Z. 2. A.*)

PLATE XIV.

FIGS. 24, C, 39, C. incl. — The figures represent, in the order of succession, a series of sections at almost regular intervals, through the head and anterior part of the body of the embryo figured at 2, C, Pl. XII. They are cut in the plane denoted by the line P–S (see Fig. 2, C) at right angles to the sagittal plane of the embryo. This same series is continued in Figs. 40, C, 41, C, and 42, C, on Plate XV. *v*, denotes the cardinal veins, uniting at *v* (Fig. 38, C) in the ductus cuvieri. *v'*, marks the hepatic veins in Fig. 40, C, which are continued from the mesenteric and vitelline veins, *v'*, Fig. 41, C.

For the other parts see Register of Index-letters. (*Z. 2.* obj. 1 inch, Browning.)

PLATE XV.

FIGS. 40, C, 41, C, 42, C. — See explanation of Plate XIV.

FIGS. 43, C, 44, C, showing coelenteric zone (*CZ*) and anterior end of the notochord (*N*). These sections are immediately consecutive. *A*, artery. *Ept*, epithelial lining of hypophysial invagination (*Hph*). *HC*, head-cavity. *wHC*, wall of head-cavity. (*Z. 2. D.*)

FIG. 45. — Frontal section through the brain of young embryo of Sphærodactylus, parallel to the brain-axis anterior to the cranial flexure. (This embryo is more advanced than that of series A.) The assymmetry is due to the twist of the embryo. *MF*, medullary-folds. *Mes*, mesoblast. *MB*, mid-brain. *FB*, fore-brain. *Opv*, optic vesicle, already pointing backward, the wall of the same (*Op*) lying immediately under the epiblast (*Ep*). *o*, external opening of the primary first ventricle at the anterior end of the neural axis. (*Z. 4. A.*)

FIG. 46. — Part of section through the fore-brain and eye in the same plane as Fig. 45. *L*, lens. *Opv*, optic ventricle. *O.st*, lumen of optic stalk. *wFB*, wall of fore-brain. (*Z. 2. A.*)

FIG. 47. — Sagittal section through the head of young embryo, immediately to one side of the median sagittal plane. *Ep*, epiblast. *in.FB*, infundibular region of fore-brain. *HC*, proximal end of head-cavity. *Hph*, hypophysial invagination. *Hyp*, hypoblast. *LJ*, lower jaw. *M*, mouth. (*Z. 4. A.*)

FIGS. 48, D, 49, D, 50, D. — Three sections, cut nearly in a sagittal plane, of an embryo slightly younger than that of series C.

FIG. 48, D, cuts the optic stalk (*O.st*) outside of the fore-brain; shows the mandibular arch (*A*); also the head-cavity; and passes through the median vertical plane at the thin points of the brain-roof where the mid-brain joins the fore-brain on one side and the hind-brain on the other. Fig. 49, D, passes through the median vertical plane at the point where the notochord touches the infundibular region of the fore-brain (*FB*). Fig. 50, D, passes through the median vertical plane at the extreme anterior dorsal region of the fore-brain, and also at a point low down in the hind-brain (*HB*). *I*, dorsal end of the hyoid-cleft. *og*, optic groove. For the other parts see Register of Index-letters. (*Z. 2. A.*)

FIG. 51, D. Diagrammatic median sagittal section of the embryo represented in series D (reconstructed from 22 drawings of consecutive sections). This figure shows the ventricles of the fore-, mid-, and hind-brain (*FB*, *MB*, *HB*), the first two separated by a lateral constriction posterior to *c*. It also illustrates the primary cranial flexure, the position of the notochord (*N*), and the first rudiment of the thyroid gland (*Th*).

FIG. 52, E. — Section passing through the anterior-dorsal wall of the mid-brain (*MB*) forward through the anterior wall of the primary fore-brain (*FB*) at right angles, immediately ventral to the eye-stalks. It shows nerve-fibres belonging to the main system of longitudinal fibres (*LF*) uniting anteriorly (*LF''*). Dorsal-wards are seen in oblique section the fibres of the posterior commissure (*PCs*). (*Z. 2. A.*)

FIGS. 53, E, 54, E. — Sections in the same plane as 52, E, cut a little farther forwards. Fig. 53, E, shows the posterior commissure (*PCs*) where its fibres pass around the dorsal summit of the brain, immediately in front of the mid-brain. Fig. 54, E, shows the first rudiment of the epiphysis (*Eph*). (*Z. 2. A.*)

FIG. 55. — Transverse section through the primary fore-brain, passing through the hypophysis (*Hph*) and the optic stalks (*O.st*). *LF*, cross-section of longitudinal fibres passing ventral to the eye-stalks. (*Z. 2. A.*)

FIGS. 56, 57, 58. — Transverse sections through the tail of an advanced embryo. Fig. 56 shows a section about the middle of the tail, Fig. 57, a section near the tip, and Fig. 58, a section just at the tip. *A*, artery. *Md*, medulla. *N*, notochord (in 58 remarkably pushed away from its usual central position). *AL*, rudiment of the caudal intestine. *vv*, veins. *mp*, muscle somites. *Mes*, mesoblast. *MHp*, indistinguishable mass of mesoblast and hypoblast. *Ne.c*, neurenteric canal. (*Z. 4. A.*)

PLATE XVI.

FIG. 59, B. — Transverse section of the young embryo of series B, showing the heart (*HT*) and the first formation of the ear (*E*). *AL*, alimentary canal. (*Z.* *2*. *A.*)

FIG. 60. — Section at right angles to the anterior surface of the fore-brain, through the eye and optic stalk of an embryo much more advanced than that in Fig. 2, C. *Ey'*, inner wall of the eye-cup. *Ey''*, outer wall of the eye-cup. *A*, artery entering the choroid slit. *Op''*, anterior wall of optic stalk, with nerve-fibres (*NF*) which run into the inner surface of the eye-cup. *Op'*, posterior wall of optic stalk. *l*, lumen of optic stalk. *FB*, wall of fore-brain. (*Z.* *4*. *A.*)

FIG. 61. — Section in the same plane as Fig. 60, through the optic stalk where its lumen communicates with that of the fore-brain. *wFB*, wall of fore-brain. For other letters see Fig 60. (*Z.* *4*. *A.*)

FIGS. 62, F, 63, F, 64, F. — Slightly oblique sagittal sections through the head of an embryo in which the paired lobes of the secondary fore-brain (*HM*) have appeared. Section 62, F, passes through the right lateral wall of the brain, cutting through the ventricles where they are most distended laterally. Section 63, F, shows the connection of all the ventricles. A line drawn through the hypophysis and posterior commissure would lie in the median sagittal plane of the embryo and in the plane of section; that part anterior to this imaginary line diverges very slightly to the right of the median plane. Fig. 64, F, represents, more highly magnified, the optic region of section 63, F. *Ch*, chiasma. *Ep*, epidermis. *HB*, hind-brain. *HM*, hemispheres. *LF*, longitudinal nerve-fibres. *LJ*, lower jaw. *œ*, œsophagus. *PCs*, posterior commissure. *Hph*, hypophysis. *In*, infundibulum. *TH*, thalamencephalon. 62, F, 63, F (*Z.* *2*. Obj. 2 inch, Ross), 64, F. (*Z.* *4*. *A.*)

FIG. 65. — Transverse section through the ventral wall of the mid-brain (*MB*), showing the exit of the third pair of nerves (*nIII*). *LF*, longitudinal fibres. *TF*, transverse fibres. (*Z.* *4*. *A.*)

FIGS. 66 and 67. — Transverse sections through the spinal medulla at an earlier (66) and a later (67) stage of development. *ar*, anterior nerve-root. *CC*, canalis centralis. *dL*, dorsal longitudinal fibres. *Ept*, epithelial floor of canalis centralis. *g*, ganglion of posterior nerve-root. *gc*, anterior gray column. *Mp*, muscle-plate. *N*, notochord. *pt*, ventral downgrowth of the lateral walls of the medulla, which enclose later the anterior fissure. *TF*, transverse fibres, which unite with the prolonged distal ends of the nerve-cells in the region marked *y*. *vL*, ventral longitudinal fibres. (The ventral longitudinal fibres in Fig. 66 are not quite so conspicuous in the plate as they are in the section.) (*Z.* *4*. *A.*)

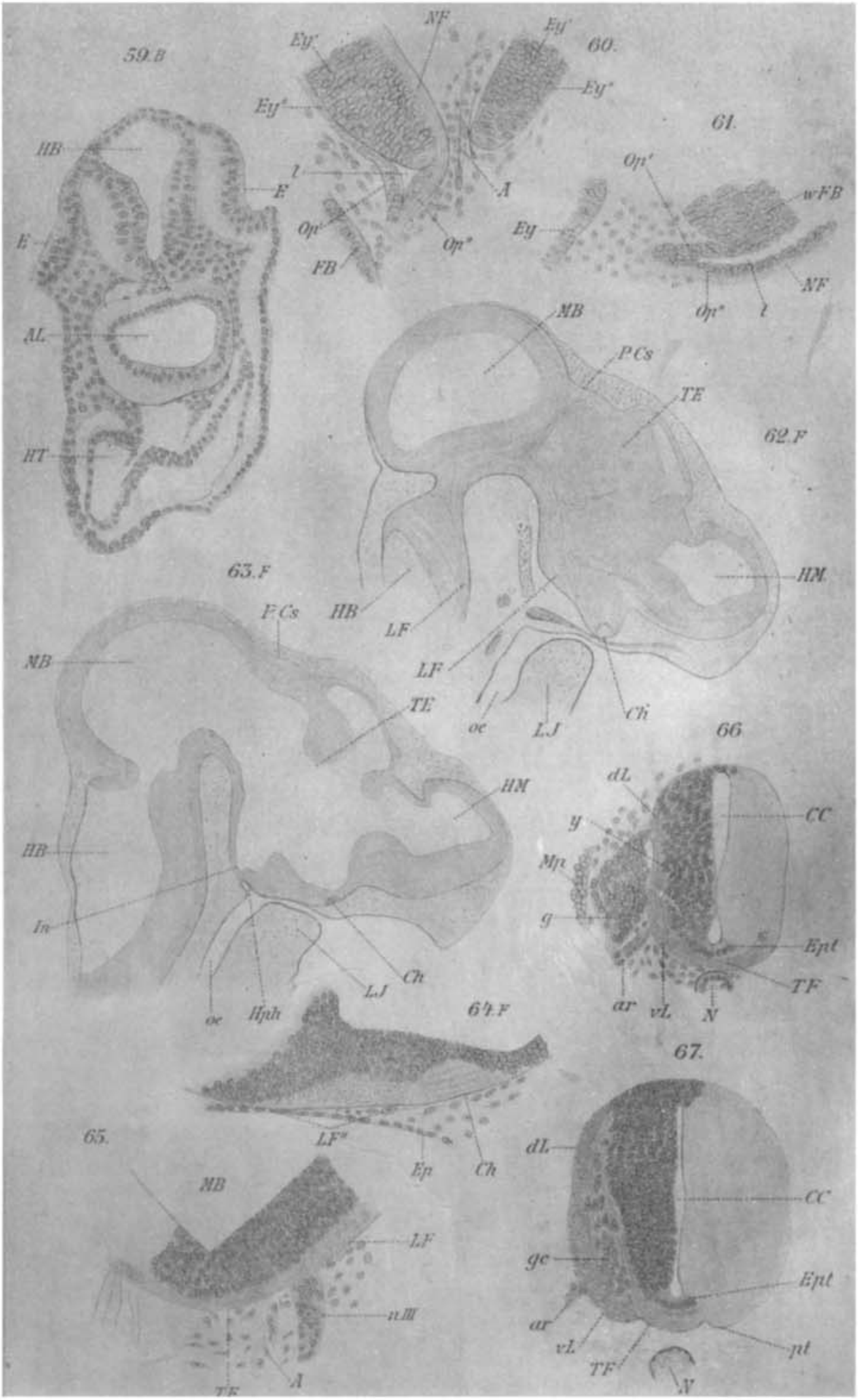

Orr ad nat. del.

Lith. Anst. v. Werner & Winter, Frankfurt a/M.