



PRESENT AND FUTURE OF ADRENAL CORTICAL CARCINOMA DIAGNOSTICS

A. CIOCE, R. FRANCO

Department of Mental and Physical Health and Preventive Medicine, Pathology Unit, Università degli Studi della Campania "Luigi Vanvitelli," Naples, Italy

KEYWORDS: Adrenal carcinoma, Helsinki score, Weiss score.

INTRODUCTION

Adrenal cortical carcinoma (ACC) is a rare aggressive tumor, with an annual incidence of 0.05-0.2/100.000 persons¹ and a bimodal age distribution, with two peaks, in the first and fifth decade of life. The 4th WHO Classification of Tumours of Endocrine organs edited in 2017 recognizes four histological variants of adult ACC: conventional, oncocytic, myxoid and sarcomatoid, in decreasing order of frequency¹.

Traditional diagnostic workup and potential pitfalls

The main differential diagnoses of adrenal cortical carcinoma include adrenal cortical adenoma, pheochromocytoma, renal cell carcinoma (primary and metastatic) and metastatic tumors. The differential diagnosis is usually straightforward, considering ACC distinctive gross and microscopic morphology and immunohistochemical staining, but it could sometimes

be challenging. Indeed, ACC shares positive staining for MELAN-A with melanocytic tumors and adrenal cortical adenomas (ACA), for Inhibin and SF-1 with adrenal cortical adenoma and like Pheochromocytoma it stains positively for Synaptophysin. Mete et al² reported that juxtannuclear insulin-like growth factor 2 (IGF-2) staining was the most useful diagnostic biomarker of adult ACCs because this pattern of staining was absent in adrenal cortical adenomas (Table 1).

The subtlest differential diagnosis remains with ACA. In the assessment of an adrenal cortical mass, in certain instances it could be challenging to establish a clearcut diagnosis, thus multiple features should be evaluated. Indeed, the scoring system proposed by Weiss, first developed in 1984, is widely the most used scoring system and represents the gold standard. The assessment is predicated on the recognition of nine distinct criteria, each of which carries a value of one point. An adrenal tumor with a Weiss score ≥ 3 is considered malignant, whereas a Weiss score of 0 or 1 is considered benign (Table 2). Neoplasms with a Weiss score of 2 or 3

TABLE 1. Immunoprofile of most frequent Adrenal tumors.

Immunohistochemistry	Carcinoma	Adenoma	Pheochromocytoma
SF-1	+	+	-
Calretinin	+	+	-
Inhibin	+	+	-
Melan-A	+	+	-
Synaptophysin	+	-	+
IGF-2	+	-	-



This work is licensed under a [Creative Commons Attribution-NonCommercial-ShareAlike 4.0 International License](https://creativecommons.org/licenses/by-nc-sa/4.0/)

DOI: 10.32113/wcrj_20233_2508



TABLE 2. The Weiss scoring system.

Weiss criteria
1 point is awarded for each criterion
Grade III-IV sec. Fuhrman
Necrosis
Clear cells < 25%
Mitoses > 5/10 mm ²
Atypical mitoses
Diffuse architecture > 33%
Vascular invasion
Sinusoidal invasion
Capsular invasion

Weiss score 0-1: Adrenal Cortical Adenoma.
Weiss score 2-3: Uncertain potential of malignancy.
Weiss score ≥ 3: Adrenal Cortical Carcinoma.

are considered borderline. For such tumors misclassification rate is calculated as 9–13% of the cases, mainly due to intra- and interobserver variability³ (Figure 1). Furthermore, Weiss system seems to be highly sensitive for conventional ACC, but difficultly applicable to the oncocytic variant.

As stated by Bisceglia et al⁴, the Weiss score in oncocytic tumors could be difficult to assess because at least three features (diffuse architecture, high nuclear grade sec. Fuhrman and eosinophilic cytoplasm) are intrinsically present in this tumor

TABLE 3. Lin-Weiss-Bisceglia criteria.

Major criteria	
Mitoses > 5/10 mm ²	
Atypical mitoses	
Venous invasion	
<hr/>	
Minor criteria	
Tumor size > 10 cm and/or weight > 200 g	
Necrosis	
Capsular invasion	
Sinusoidal invasion	

≥ 1 Major criteria: Adrenal Cortical Carcinoma.
1-4 Minor criteria: borderline tumor.

variant, resulting in a misleading overdiagnosis. Lin-Weiss-Bisceglia system is based on the recognition of Major and Minor criteria. In this case, a cortical oncocytic tumor is diagnosed as malignant when at least 1 Major criterion is present; tumors with 1 to 4 minor criteria are considered to have uncertain malignant potential (Table 3).

Due to prominent extracellular mucin deposition, some Weiss parameters (ex. lack of diffuse growth, nuclear atypia or lymphatic invasion) may be difficult to assess also in rare myxoid adrenal cortical neoplasms⁵.

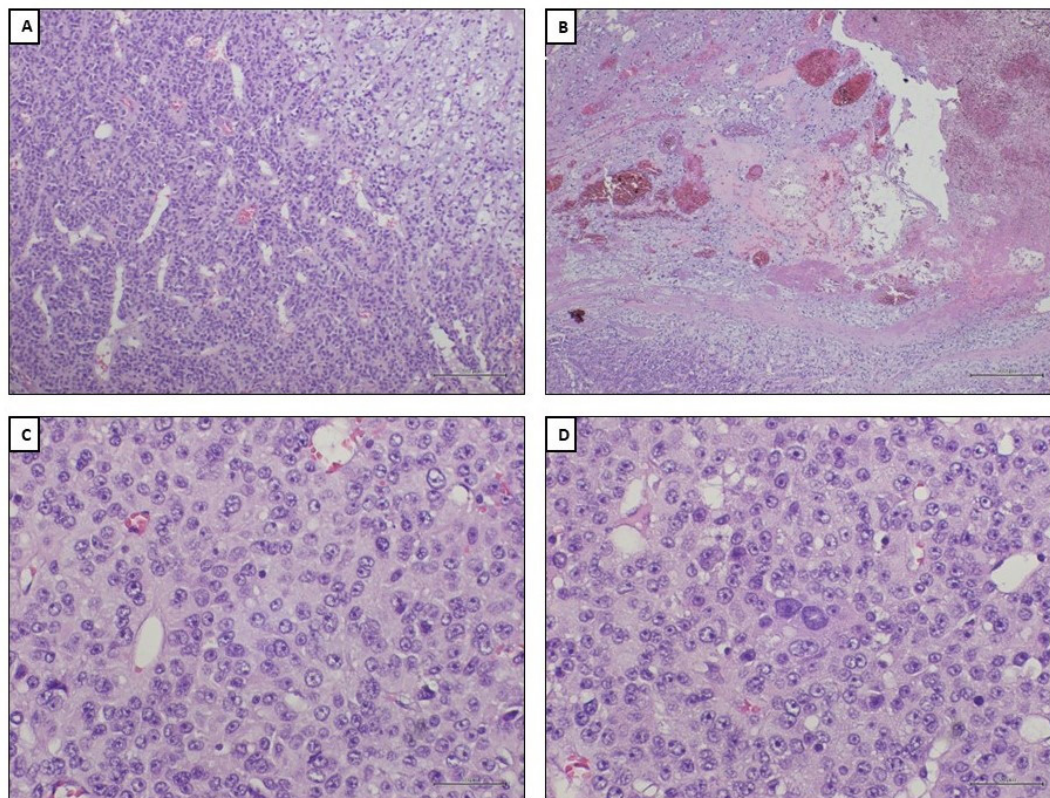


Fig. 1. The Weiss scoring system for Adrenal Cortical Carcinoma (ACC) diagnosis requires the presence of at least 3 criteria. These include: **A)** clear cells comprising less than 25% of the tumor cellularity, **B)** tumor necrosis which strongly correlates with malignancy in adrenal cortical lesions, **C)** the presence of more than 5 mitoses/10 mm² or atypical mitoses, and **D)** high nuclear grade with prominent nucleoli in large, irregular cells that are typically present in ACCs.

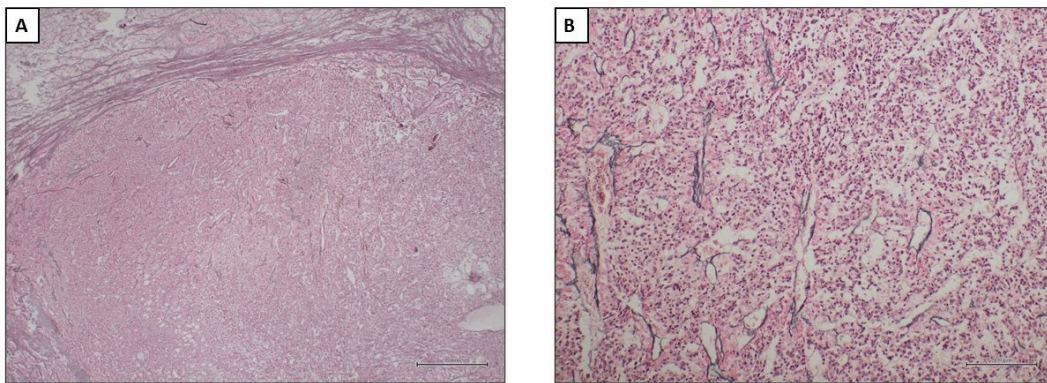


Fig. 2. A-B. A disrupted reticulin framework highlighted by the histochemical silver staining is an essential criteria of the Reticulin algorithm in the Adrenal cortical carcinoma diagnostic.

In 2009, some authors proposed a novel diagnostic algorithm based on the evidence that most ACC showed a disrupted reticulin framework on silver-based histochemical staining⁶. The Reticulin algorithm, validated in 2013, is helpful to classify an adrenal cortical tumor as malignant when it has an altered reticulin pattern associated to one of the following features: necrosis, mitotic rate $> 5/10 \text{ mm}^2$ and angioinvasion (already included in Weiss criteria). The reticulin algorithm has also proven to be a useful tool in the diagnostic workflow of both oncocytic and myxoid variants of ACC⁷ (Figure 2).

Updates on Adrenal cortical carcinoma diagnostic

Recently published overview of WHO classification of adrenal cortical tumors re-proposes the classic pathologic criteria for the diagnosis of ACC with slight improvements.

The new WHO classification redefines the significance of angioinvasion both for diagnostic and prognostic reasons. While macroscopic angioinvasion is easily detected in gross or clinical examina-

tion in advanced stages, microscopic angioinvasion is considered when tumor cells are admixed with fibrinoid material or form a thrombus inside the lumen or through the vessel wall. Therefore, the new classification emphasizes the role of CD61 (anti-GPIIIa) immunostaining as a helpful tool to detect platelets in sites of angioinvasion⁵.

The 2023 WHO classification introduces a tumor mitotic grading system for ACCs based on a cut-off of 20 mitoses/ 10 mm^2 . Low-grade ACCs have a mitotic rate ≤ 20 whereas high-grade ACCs show > 20 mitoses/ 10 mm^2 .

Along with above discussed diagnostic algorithms, the new classification introduces a multi-parameter weighted-point system: The Helsinki scoring system. First developed in 2015⁸ and validated in 2017⁹, the Helsinki score is the first diagnostic and prognostic system based on the combined evaluation of two morphological criteria (necrosis and mitoses $> 5/10 \text{ mm}^2$) and one immunohistochemical parameter (Ki-67 labeling index). This scoring system integrates the numeric value of Ki-67 labeling index by adding scores assigned to increased mitotic rate (score 3) and tumor necrosis (score 5). A Helsinki score > 8.5 is diagnostic

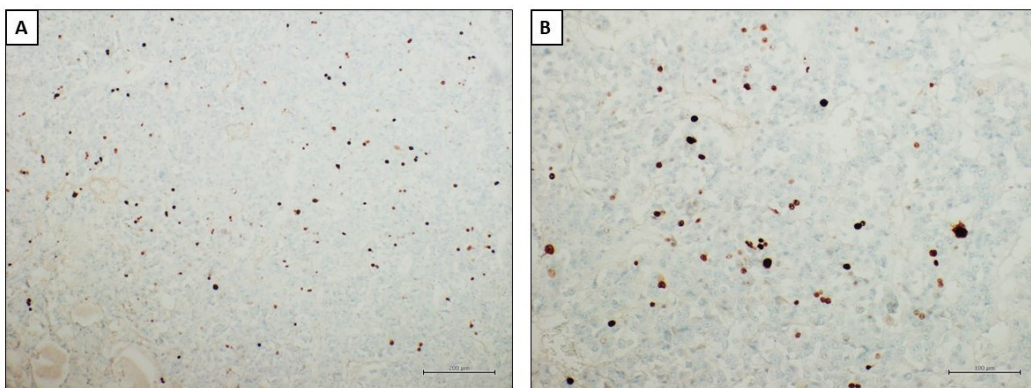


Fig. 3. A-B. Ki-67 labeling index evaluated by immunohistochemistry in the “hotspot” areas is crucial for the Helsinki scoring system both as diagnostic and prognostic factor.



TABLE 4. Helsinki scoring system.

Histological criteria	Score
Mitoses > 5/10 mm ²	3
Necrosis	5
Ki-67 labeling index	% of Ki-67 from the hotspot areas

Score 0 to 8.5: Adrenal cortical adenoma.

Score > 8.5: Adrenal cortical carcinoma.

Score > 17: adverse prognosis.

of ACC, and a score of > 17 has been suggested to correlate with adverse prognosis (Figure 3). Encouraging results have been reported using the Helsinki score in the diagnostic workup of conventional ACC and its variants¹⁰ (Table 4).

CONCLUSIONS

The new WHO classification lays the foundations for a more essential and reproducible diagnostic workup for the Adrenal Cortical neoplasms.

ETHICS APPROVAL:

As our study did not involve human subjects, ethics approval was not required.

INFORMED CONSENT:

As our study did not involve human subjects, informed consent was not required.

AVAILABILITY OF DATA:

The data used in this opinion paper were obtained through a comprehensive literature search conducted on PubMed. All references cited in this article are available in the public domain and can be accessed through PubMed.

FUNDING:

No funding is declared for this article.

AUTHOR CONTRIBUTIONS:

Conception and design of the study: Renato Franco, Alessandro Cioce; Acquisition of data: Alessandro Cioce; Supervision: Renato Franco.

ORCID ID:

Renato Franco – <https://orcid.org/0000-0002-8340-3184>.

Alessandro Cioce – <https://orcid.org/0000-0001-5850-8139>.

CONFLICT OF INTEREST:

The authors declare that they have no conflict of interest to disclose

REFERENCES

1. Fassnacht M, Kroiss M, Allolio B. Adrenocortical Carcinoma. In: Lloyd RV, Osamura RY, Klöppel G, Rosai J, eds. WHO Classification of Tumours of Endocrine Organs. 4th ed. Lyon, France: IARC Press 2017; pp. 181- 194.
2. Mete O, Gucer H, Kefeli M, Asa SL. Diagnostic and Prognostic Biomarkers of Adrenal Cortical Carcinoma. *Am J Surg Pathol* 2018; 42: 201- 213.
3. Viëtor CL, Creemers SG, van Kemenade FJ, van Ginhoven TM, Hofland LJ, Feelders RA. How to Differentiate Benign from Malignant Adrenocortical Tumors? *Cancers (Basel)* 2021; 13: 4383.
4. Bisceglia M, Ludovico O, Di Mattia A, Ben-Dor D, Sandbank J, Pasquinelli G. Adrenocortical oncocytic tumors: report of 10 cases and review of the literature. *Int J Surg Pathol* 2004; 12: 231- 243.
5. Mete O, Erickson LA, Juhlin CC, Papathomas TG, Suarez SM, Volante M, Tischler AS, Alves VA, Baloch ZW, Thompson LDR. Overview of the 2022 WHO Classification of Adrenal Cortical Tumors. *Endocr Pathol* 2022; 33: 155-196.
6. Volante M, Bollito E, Sperone P, Tavaglione V, Daffara F, Porpiglia F, Terzolo M, Papotti M. Clinicopathological study of a series of 92 adrenocortical carcinomas: from a proposal of simplified diagnostic algorithm to prognostic stratification. *Histopathology* 2009; 55: 535- 543.
7. Duregon E, Fassina A, Volante M, Pelizzo MR, Mantero F, Mastrangelo G, Berruti A, Papotti M. The reticulin algorithm for adrenocortical tumor diagnosis: a multicentric validation study on 245 unpublished cases. *Am J Surg Pathol* 2013; 37: 1433-1440.
8. Pennanen M, Heiskanen I, Sane T, Remes S, Mustonen H, Haglund C, Arola J, Haglund F, Salmenkivi K, Knuutila S, Aittomäki K. Helsinki score-a novel model for prediction of metastases in adrenocortical carcinomas. *Hum Pathol* 2015; 46: 404-410.
9. Duregon E, Cappellesso R, Maffei V, Zaggia B, Ventura L, Berruti A, Terzolo M, Fassina A, Papotti M. Validation of the prognostic role of the "Helsinki Score" in 225 cases of adrenocortical carcinoma. *Hum Pathol* 2017; 62: 1-7.
10. Minner S, Schreiner J, Saeger W. Adrenal cancer: relevance of different grading systems and subtypes. *Clin Transl Oncol* 2021; 23: 1350-1357.