

Rescue stenting after the failure of intravenous thrombolysis and bridging thrombolysis: an initial Vietnamese report

M.-T. LE¹, C.-C. TRAN¹, G. NGUYEN-LUU¹, M.-T. NGO¹, N.-H. NGUYEN-DAO¹, L. DUONG-HOANG¹, M. MAI-VAN¹, M.-D. NGUYEN²

¹Digital Subtraction Angiography Unit, Can Tho Stroke International Services General Hospital, Can Tho, Vietnam

²Department of Radiology, Pham Ngoc Thach University of Medicine, Ho Chi Minh City, Vietnam

Le Minh Thang and Tran Chi Cuong contributed equally to this article as co-first authors

Abstract. – OBJECTIVE: Intravenous (IV) recombinant tissue plasminogen activator is the standard of care for patients with acute ischemic stroke (AIS) who present to the hospital within 4.5 hours of symptom onset. However, IV thrombolysis, even bridging thrombolysis (combining intravenous thrombolysis and mechanical thrombectomy) has limited efficacy among patients who had occlusive lesions associated with high-grade arterial stenosis requiring revascularization to improve neurological deficits. We evaluated whether rescue stenting results in good outcomes among patients after the failure of intravenous thrombolysis and bridging thrombolysis.

PATIENTS AND METHODS: We retrospectively analyzed patients with AIS who underwent rescue stenting for large vessel occlusion with severe atherosclerotic stenosis between May 2020 and August 2022 at Can Tho S.I.S General Hospital. Primary outcomes included the incidence of hemorrhagic transformation and the rate of good outcomes (modified Rankin Scale < 3) at 3-month follow-up.

RESULTS: We identified 13 patients who received rescue stenting after the failure of IV alteplase and bridging thrombolysis, but only 11 patients met the inclusion criteria. All patients experienced successful recanalization, and 1 (9.1%) patient experienced new infarcts. Of these 11 patients, 10 (90.9%) had good outcomes 3 months after rescue stenting. Additionally, a loading dose of dual antiplatelet therapy (DAPT) applied concurrently with IV alteplase improved the recanalization rate for large target arteries but had no significant effect on the incidence of symptomatic intracranial hemorrhage.

CONCLUSIONS: Rescue stenting appears to represent an additional therapeutic option in cases that fail to resolve with IV alteplase, which may improve clinical outcomes.

Key Words:

Ischemic stroke, Rescue stenting, Intravenous thrombolysis, Dual antiplatelet therapy.

Introduction

Stroke is the second most common cause of death worldwide, with an annual mortality rate of approximately 5.5 million¹. Depending on the timing of presentation, intravenous (IV) administration of recombinant tissue plasminogen activator can be an effective treatment, but is most effective when used between 3 and 4.5 hours of symptom onset. Bridging thrombolysis, which describes the combination of IV thrombolysis and mechanical thrombectomy, can lead to long-term functional independence after 90 days with higher recanalization success rates than IV thrombolysis alone without increased risk^{2,3}. The HERMES meta-analysis of five trials (MR CLEAN, ESCAPE, REVASCAT, SWIFT PRIME, and EXTEND IA) indicated the potential benefits of mechanical thrombectomy (MT) in case of proximal circulation occlusions. The recanalization failure rate of this treatment, defined as a modified Thrombolysis in Cerebral Ischemia (mTICI) score of 2a or worse, remained high, ranging from 13% to 29%, and most patients experienced poor clinical outcomes^{4,5}. Permanent stent placement has been suggested as a potential approach for achieving successful recanalization, which is the goal of endovascular therapy in the early management of acute ischemic stroke (AIS)^{6,7}. However, the risk of intracranial hemorrhage associated

with the combined use of IV thrombolysis and a loading dose of dual antiplatelet therapy (DAPT) increases when rescue stenting is applied^{8,9}. We hypothesize that stent deployment might serve as a feasible treatment for large artery occlusion after the failure of intravenous thrombolysis and bridging thrombolysis.

Patients and Methods

Patient Selection

We retrospectively analyzed 11 consecutive patients aged ≥ 18 years with AIS who underwent rescue stenting for large vessel occlusions underlying severe atherosclerotic stenosis after the failure of IV alteplase and bridging thrombolysis therapy administered within 4.5 hours of symptom onset. Treated large vessels included the carotid artery, internal carotid artery (ICA), middle cerebral artery (MCA) M1 segment, intracranial segment of the vertebral artery, and basilar artery. All patients were treated at Can Tho S.I.S General Hospital between May 2020 and August 2022. Patients with either a premorbid modified Rankin Scale (mRS) ≥ 2 or who underwent the initial therapy 24 hours after symptom onset were excluded from this study (Figure 1).

The following variables were collected during this study: patient demographics, cerebrovascular risk factors, assessments of initial stroke severity

at admission using the National Institutes of Health Stroke Scale (NIHSS), mRS from the premorbid time point through 3-months follow-up, IV alteplase administration, Diffusion-Weighted Imaging-Alberta Stroke Program Early Computed Tomography Scores (DWI-ASPECTS), posterior circulation ASPECTS (pc-ASPECTS), procedural characteristics, and outcomes.

Informed consent was provided by all patients or their legally authorized surrogates after receiving a detailed explanation of the procedures. The study protocol was approved by the Ethics Council in biomedical research at Can Tho S.I.S General Hospital (7920C/QD-S.I.S, dated May 10, 2020).

Procedures

Prior to performing rescue stenting, all patients underwent baseline neurovascular magnetic resonance imaging (MRI) and magnetic resonance angiography (MRA). Eligible patients were those with AIS treated with IV alteplase within 4.5 hours of symptom onset in accordance with the standard protocol of the hospital (0.6 mg/kg or 0.9 mg/kg infused over 60 minutes, with 10% of the total dose as an initial IV bolus). After the treatment with IV alteplase, patients were monitored for neurological deterioration by using the NIHSS. Neurological deterioration was defined as a change in the NIHSS of ≥ 4 points within 24 hours. MRI and MRA were used to screen patients with recorded neurological deterioration (Figure 2). Patients with no evidence of intracerebral hemorrhage in MRI who presented with increased hyperintense lesions due to large vessel steno-occlusion were indicated for immediate recanalization.

General anesthesia was used during the procedure. If susceptibility-weighted imaging or cerebral angiography revealed large cerebral artery occlusion due to thrombus, direct aspiration alone or the Solumbra technique was first performed. Vessel recanalization was evaluated by using the modified Thrombolysis in Cerebral Infarction (mTICI) grade, with failed recanalization defined as mTICI grade 2a or lower. A loading dose of DAPT (300 mg clopidogrel and 162 mg aspirin) was administered through a nasogastric tube either after failed MT reperfusion attempts or during direct rescue stenting. During the procedure, all catheters were continuously infused with saline containing 2,000 IU/500 ml heparin; therefore, patients were only administered IV heparin if the procedure lasted longer than 60 minutes, consisting of a 3,000 IU bolus, followed by an infusion of 500 IU/hour. Residual in-stent recurrent stenosis $\geq 50\%$ diameter, as assessed by cerebral angiography, required retreatment by re-angioplasty.

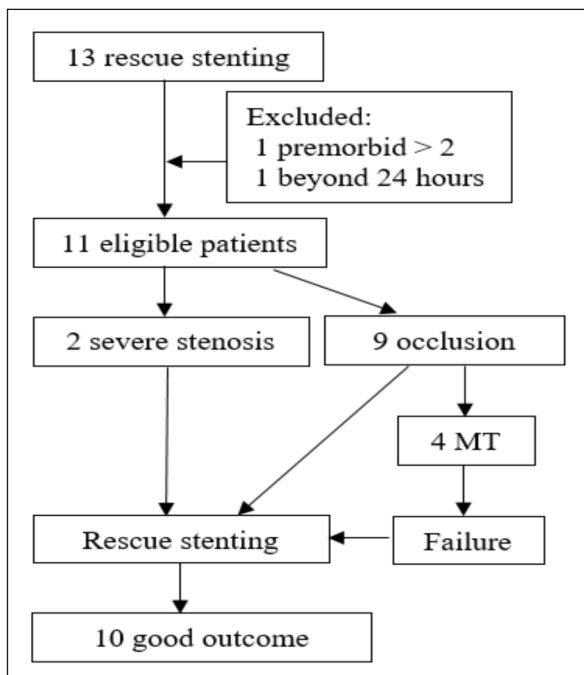


Figure 1. Flowchart of patient selection for the present study.

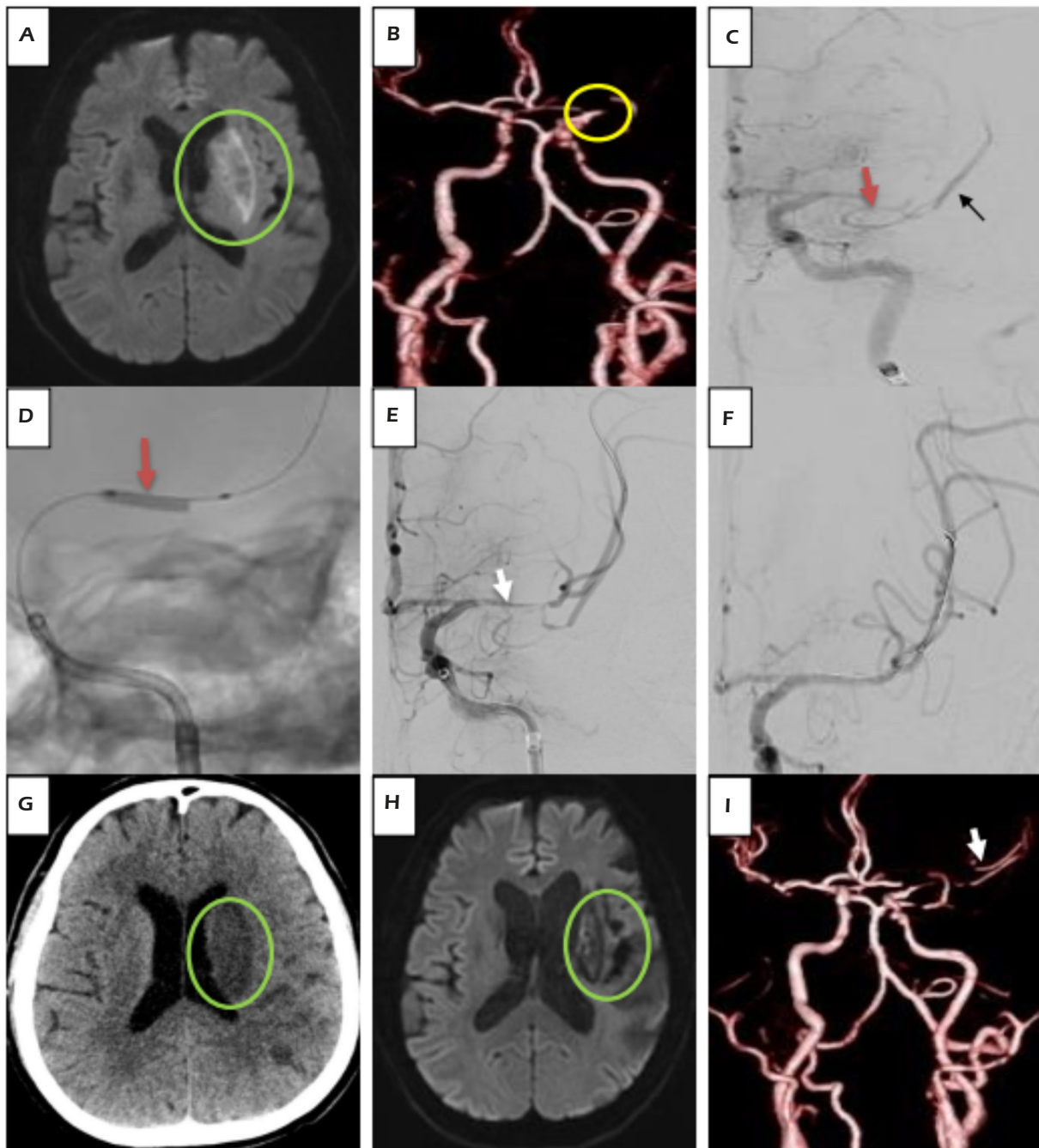


Figure 2. Sample case: **A**, Diffusion-Weighted Imaging-Alberta Stroke Program Early Computed Tomography Score of 7 (*green circle*). **B**, Magnetic resonance angiography revealed acute occlusion in the left middle cerebral artery (MCA) M1 segment (*yellow circle*). **C**, Digital subtraction angiography showed acute occlusion in the left MCA M1 segment (*red arrow*) and the distal M2 segment (*black arrow*). **D**, Angioplasty performed using a Gateway 2.0 × 15 (Stryker Neurovascular, Fremont, CA, USA) (*orange arrow*). **E**, Angiography following dilation (*white arrow*). **F**, Successful recanalization after the placement of a Wingspan 3.0 × 20 stent (Stryker Neurovascular, Fremont, CA, USA). **G**, Intracranial hemorrhage was excluded on the postoperative computed tomography scan (*green circle*). **H**, Left chronic infarct after 1 year (*green circle*). **I**, Left MCA M2 segment remained visible (*white arrow*).

Successful revascularization was defined as mTICI $\geq 2b$. After the procedure, patients were continuously maintained at a systolic blood pressure ranging from 120 to 140 mmHg. From the day after the pro-

cedure, daily DAPT (75 mg clopidogrel and 100 mg aspirin) was started and maintained for 3 months in patients with no evidence of parenchymal hematoma on head computed tomography or MRI and with

no vascular risk factors, such as high blood pressure, high cholesterol, or poor blood glucose control. A daily dose of 75 mg clopidogrel was prescribed after 3 months. Symptomatic intracranial hemorrhage (sICH) was defined as any evidence of hematoma on follow-up imaging after stroke onset and neurological deterioration, defined as a ≥ 4 -point increase on the NIHSS relative to baseline, according to the guidelines established by the European Cooperative Acute Stroke Study (ECASS) III¹⁰.

Outcomes

The primary outcome was assessed by using the mRS, with a good functional outcome defined as mRS of 0-2 at 3-month follow-up. Outcome data were collected through telephone interviews conducted by experienced neurologists.

Statistical Analysis

Statistical analyses were performed using Stata 16 (StataCorp LLC, Texas, USA). Data are expressed as the mean and standard deviation (SD) for continuous variables. Categorical variables are displayed as

frequencies and percentages. A $p < 0.05$ was considered statistically significant with a 95% CI.

Results

We identified 13 cases of rescue stent deployment during the defined study period, from May 2020 to August 2022, at Can Tho S.I.S General Hospital. A total of 11 patients met the eligibility criteria and were enrolled in this study. Patients ranged in age from 43 to 73 years. The mean age was 59.4 years, and 100% of enrolled patients were men. Patients with severe symptoms, as assessed by the NIHSS, accounted for 54.6% of the cohort. The mean baseline DWI-ASPECTS was 7.6 (SD, 0.4), and the mean baseline pc-ASPECTS was 5.5 (SD, 0.5). Neurovascular risk factors for ischemic stroke included hypertension (100%), smoking (72.7%), hyperlipidemia (18.2%), diabetes mellitus (36.4%), and myocardial infarction (36.4%). Among four patients treated with 0.6 mg/kg alteplase, three patients received both IV alteplase and groin punc-

Table I. Clinical and procedural characteristics of patients who underwent rescue stenting.

Treatment (mg/kg) + (I.U./kg)	Brain concentrations (µg/ml)
Patient characteristics	
Age in y, mean (SD)	59.4 (3.2)
Male sex, n (%)	11 (100%)
Diabetes mellitus, n (%)	4 (36.4%)
Smoking, n. (%)	8 (72.7%)
Hyperlipidemia, n (%)	2 (18.2%)
Myocardial infarction, n (%)	4 (36.4%)
Admission characteristics	
IV alteplase	
0.9 mg/kg, n (%)	7 (63.6%)
0.6 mg/kg, n (%)	4 (36.4%)
NIHSS > 21, n (%)	6 (54.6%)
Site of lesion	
Carotid artery, n (%)	1 (9.1%)
Internal carotid artery, n (%)	1 (9.1%)
Middle cerebral artery M1 segment, n (%)	7 (63.6%)
Intracranial vertebral artery, n (%)	1 (9.1%)
Basilar artery, n (%)	1 (9.1%)
Procedural characteristics	
Time from onset to groin puncture in hours, mean (SD)	6.5 (0.6)
Groin puncture performed within 4.5 hours of onset, n (%)	3 (27.3%)
Time between alteplase and loading dual in minutes, mean (SD)	270 (42)
Procedure time in minutes, mean (SD)	63.6 (5.9)
Procedural time > 60 minutes, n (%)	4 (36.4%)
Anterior circulation, n (%)	9 (81.8%)
Occlusive lesions, n (%)	9 (81.8%)
Self-expanding stent, n (%)	9 (81.8%)
Angioplasty time > 1, n (%)	5 (45.5%)
Procedure > 1, n (%)	4 (36.4%)
New infarcts, n (%)	1 (9.1%)

DAPT, dual antiplatelet therapy; SD, standard deviation; NIHSS, National Institutes of Health Stroke Severity; IV, intravenous.

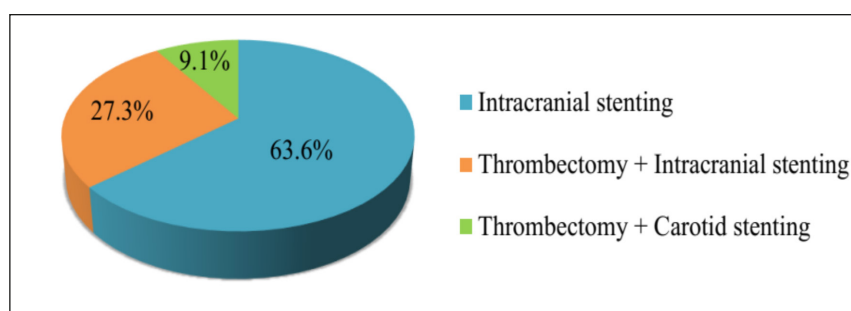


Figure 3. Proportions of procedures performed to achieve successful recanalization.

ture within 4.5 hours of symptom onset. Anterior circulation lesions (81.8%) were more commonly identified than posterior lesions (18.2%), particularly MCA M1 segment lesions (63.6%) (Table I). Besides, no significant difference between the cerebral circulations were found in poor outcome at 3 months ($p = 0.2$, Table II).

Although occlusive lesions were identified in 81.8% of patients, only 9.1% of patients experienced new infarcts after treatment (Table II).

More patients underwent rescue stenting alone (63.6%) than received rescue stenting in combination with other procedures, such as MT (9.13%) or carotid or intracranial stenting (27.3%; Figure 3).

Discussion

The time from symptom onset is a primary factor when deciding how to treat AIS. Patients

who present within 4.5 hours of symptom onset and are candidates for thrombolytic agents can benefit from the administration of IV alteplase, which binds to the fibrin surface of the thrombus and directly converts circulating plasminogen to plasmin. The updated American Stroke Association, American Heart Association, and European Stroke Organization guidelines approve the use of IV alteplase administration within 4.5 hours of ischemic stroke symptom onset^{11,12}. Early recanalization following IV alteplase in the ICA (MCA M1 segment; MCA M2 segment; and combined M1 and M2) resulted in MRA-assessed total (complete and partial) success rates of 51.9% (14.3% and 47.6%) after 24 hours and 66.7% (14.3% and 47.6%) after 7 days. However, the recanalization success rates for the MCA M2 segment were 91.6% (58.3% and 33.3%) at 24 hours and 100% (90.9% and 9.1%) 7 days¹³. These differences may be due to (1) larger emboli in larger vessels; (2) initially

Table II. Preprocedural and postprocedural characteristics according to functional outcomes at 3-month follow-up.

Baseline Variables	Good Outcome (n=10)	Poor Outcome (n=1)	p-value
Age \geq 70 years, n (%)	2 (18.2%)	1 (9.1%)	0.3
Diabetes, n (%)	4 (36.4%)	0	0.6
Smoking, n (%)	7 (63.6%)	1 (9.1%)	0.8
Hyperlipidemia, n (%)	2 (18.2%)	0	0.8
Myocardial infarction, n (%)	4 (36.4%)	0	0.6
IV alteplase 0.9 mg/kg, n (%)	6 (54.5%)	1 (9.1%)	0.6
NIHSS $>$ 21, n (%)	5 (45.5%)	1 (9.1%)	0.5
pc-ASPECTS $<$ 6 points, n (%)	0	1 (9.1%)	0.5
Posterior circulation, n (%)	1 (9.1%)	1 (9.1%)	0.2
Procedural time $>$ 60 minutes, n (%)	4 (36.4%)	0	0.6
Occlusive lesions, n (%)	8 (72.7%)	1 (9.1%)	0.8
Self-expanding stent, n (%)	8 (72.7%)	1 (9.1%)	0.8
Angioplasty $>$ 1, n (%)	4 (36.4%)	1 (9.1%)	0.5
Procedure $>$ 1, n (%)	3 (27.3%)	1 (9.1%)	0.4
New infarcts, n (%)	0	1 (9.1%)	0.1

Good outcome, modified Rankin Scale 0-2; Poor Outcome, modified Rankin Scale $>$ 2; NIHSS, National Institutes of Health Stroke Severity; IV, intravenous; pc-ASPECTS, posterior circulation Alberta Stroke Program Early Computed Tomography Score.

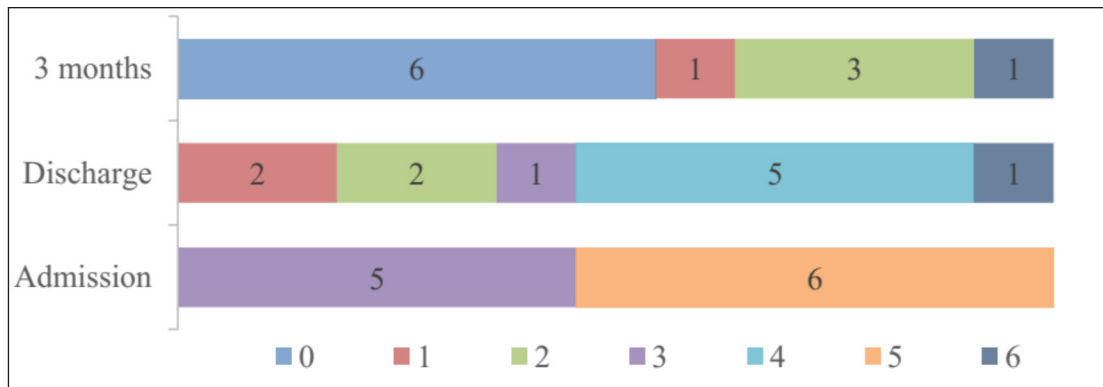


Figure 4. Distribution of modified Rankin Scale (mRS) values among patients before and after rescue stenting. The mRS scores are categorized as good outcome (mRS 0-2, blue, red and green, respectively), poor outcome (mRS 3-5, purple, azure and orange, respectively) and death (mRS 6, cobalt blue).

lysed thrombi causing microvascular thrombosis at distal arteries; (3) severe residual stenosis due to large artery occlusion; and (4) high wall shear rates associated with early platelet accumulation and activated coagulation proteins in arteries with residual stenosis^{8,13-16}. Although alteplase is eliminated by the liver with an initial half-life of approximately 5 minutes (free form) and a terminal half-life of 72 minutes (bound form), the use of antithrombotic therapy (other than IV aspirin) might be considered during the first 24 hours after treatment with IV alteplase or bridging thrombolysis (Class of Recommendation IIb - weak, Level of Evidence B-Nonrandomized)^{11,17}. In the Antiplatelet Therapy in Combination with rt-PA Thrombolysis in Ischemic Stroke (ARTIS) trial, the use of 300 mg IV aspirin within 90 minutes of IV alteplase administration increased the risk of intracranial hemorrhage and did not improve outcomes at 3-month follow-up compared with the use of standard alteplase without aspirin¹⁸. Successful recanalization is a critical factor leading to a favorable prognosis for patients with AIS^{5,6}. Therefore, rescue stent placement is often considered, although few studies^{6,9,19,20} have described the outcomes of rescue stent cases treated with preprocedural IV alteplase, followed by a loading dose of DAPT or a combination of IV glycoprotein IIb/IIIa inhibitor bolus and oral DAPT within 24 hours. Stracke et al²¹ reported that the administration of IV alteplase before rescue stenting did not influence hemorrhage risk ($p = 0.311$). Moreover, the Stenting and Angioplasty in Neurothrombectomy (SAINT) study reported that rescue stenting was associated with a substantial decrease in sICH occurrence among patients who

received IV thrombolysis (unadjusted odds ratio = 0.84; $p = 0.03$) and could represent a safe treatment option for large vessel occlusion underlying severe atherosclerosis ($p < 0.001$)⁷. In our study, none of the patients experienced hemorrhagic transformation, although the mortality rate (9.1%) of our study was higher than those reported by Sallustio et al⁸ (0%) or Kwon et al⁹ (5.7%). Based on the short half-life of alteplase within 72 minutes, we administered DAPT to prevent in-stent thrombosis after failed thrombolysis and MT. Additionally, the mean time to initiation of antiplatelet in our study (270 minutes, Table I) was three times as long as the protocol used for the ARTIS trial (90 minutes). Interestingly, the high prevalence of intracranial atherosclerosis among Asian populations was a deciding factor in the decision to perform direct stenting when reocclusion was detected after IV alteplase, with the average procedure time 63.6 minutes (Table I)²². The performance of direct stenting without attempting MT passes prevented any increased incidence of procedural complications (Figure 4).

Limitations

Our study had several limitations. This study was an observational retrospective study at a single center with a small number of patients, and the decision to perform rescue stenting depended on the experience of the interventionists. Therefore, our findings should be interpreted cautiously due to potential selection bias and the inability to assess whether our findings can be generalized to other countries. In the future, randomized controlled trials are necessary to investigate whether patients who undergo rescue stenting for recanal-

ization combined with DAPT compare favorably with patients treated using standard management strategies, especially the time to early antiplatelet therapy initiation within 24 hours following IV alteplase failure.

Conclusions

Permanent stent placement as a rescue recanalization strategy within 24 hours of IV alteplase and bridging thrombolysis failure, combined with a concomitant DAPT loading dose, improved the proportion of good clinical outcomes without increasing hemorrhagic complications.

Conflict of Interest

The Authors declare that they have no conflict of interests.

Availability of Data and Materials

The data that support the findings of this study are available from the corresponding author upon reasonable request.

Funding

The authors received no specific funding for this work.

Acknowledgments

The authors are grateful to the study participants and the medical staff for their assistance.

Informed Consent

Informed consent was provided by all patients or their legally authorized surrogates after receiving a detailed explanation of the procedures.

Ethics Approval

The study involving human participants was reviewed and approved by the Ethics Council in biomedical research in S.I.S Can Tho (7920C/QD-S.I.S, dated on May 10, 2020).

Authors' Contributions

M.-T. Le and C.-C. Tran gave a substantial contribution in acquisition, analysis, and data interpretation. M.-T. Le and M.-D. Nguyen prepared, drafted, and revised manuscript critically for important intellectual content. Each author gave the final approval of the version to be published and agreed to be accountable for all aspects of the work, ensuring that questions related to the accuracy or integrity of any part of the work are appropriately investigated and resolved.

ORCID ID

Nguyen Minh Duc: 0000-0001-5411-1492.

References

- 1) Feigin VL, Brainin M, Norrving B, Martins S, Sacco RL, Hacke W, Fisher M, Pandian J, Lindsay P. World Stroke Organization (WSO): Global Stroke Fact Sheet 2022. *Int J Stroke* 2022; 17: 18-29.
- 2) Wang Y, Wu X, Zhu C, Mossa-Basha M, Malhotra A. Bridging Thrombolysis Achieved Better Outcomes Than Direct Thrombectomy After Large Vessel Occlusion. *Stroke* 2021; 52: 356-365.
- 3) Chen ZJ, Li XF, Liang CY, Cui L, Yang LQ, Xia YM, Cao W, Gao BL. Comparison of Prior Bridging Intravenous Thrombolysis With Direct Endovascular Thrombectomy for Anterior Circulation Large Vessel Occlusion: Systematic Review and Meta-Analysis. *Front Neurol* 2021; 12: 602370.
- 4) Campbell BC, Hill MD, Rubiera M, Menon BK, Demchuk A, Donnan GA, Roy D, Thornton J, Dorado L, Bonafe A, Levy EI, Diener HC, Hernández-Pérez M, Pereira VM, Blasco J, Quesada H, Rempel J, Jahan R, Davis SM, Stouch BC, Mitchell PJ, Jovin TG, Saver JL, Goyal M. Safety and Efficacy of Solitaire Stent Thrombectomy: Individual Patient Data Meta-Analysis of Randomized Trials. *Stroke* 2016; 47: 798-806.
- 5) Karamchandani RR, Rhoten JB, Strong D, Chang B, Asimos AW. Mortality after large artery occlusion acute ischemic stroke. *Sci Rep* 2021; 11: 10033.
- 6) Tschoe C, Coffman S, Kittel C, Brown P, Kasab SA, Almouhoui E, Spiotta A, Howard B, Alawieh A, Arthur A, Goyal N, Kan P, Kim JT, Leacy RD, Rai A, Park M, Starke R, Jabbour P, Crosa R, Dumont T, Maier I, Osbun J, Fargen K, Wolfe S. Outcomes After Intracranial Rescue Stenting for Acute Ischemic Stroke. *Stroke Vasc Interv Neurol* 2022; 2: e000129.
- 7) Mohammaden MH, Haussen DC, Al-Bayati AR, Hassan A, Tekle W, Fifi J, Matsoukas S, Kuybu O, Gross BA, Lang MJ, Narayanan S, Cortez GM, Hanel RA, Aghaebrahim A, Sauvageau E, Farooqui M, Ortega-Gutierrez S, Zevallos C, Galecio-Castillo M, Sheth SA, Nahhas M, Salazar-Marioni S, Nguyen TN, Abdalkader M, Klein P, Hafeez M, Kan P, Tanweer O, Khaldi A, Li H, Jumaa M, Zaidi S, Oliver M, Salem MM, Burkhardt JK, Pukenas BA, Alaraj A, Peng S, Kumar R, Lai M, Siegler J, Nogueira RG. Stenting and Angioplasty in Neurothrombectomy: Matched Analysis of Rescue Intracranial Stenting Versus Failed Thrombectomy. *Stroke* 2022; 53: 2779-2788.
- 8) Sallustio F, Koch G, Rocco A, Rossi C, Pampana E, Gandini R, Meschini A, Diemedi M, Stanzione P, Di Legge S. Safety of early carotid artery stenting after systemic thrombolysis: a single center experience. *Stroke Res Treat* 2012; 2012: 904575.
- 9) Kwon DH, Jang SH, Park H, Sohn SI, Hong JH. Emergency Cervical Carotid Artery Stenting After Intravenous Thrombolysis in Patients With Hyper-

- acute Ischemic Stroke. *J Korean Med Sci* 2022; 37: e156.
- 10) Hacke W, Kaste M, Bluhmki E, Brozman M, Dávalos A, Guidetti D, Larrue V, Lees KR, Medeghri Z, Machnig T, Schneider D, von Kummer R, Wahlgren N, Toni D; ECASS Investigators. Thrombolysis with alteplase 3 to 4.5 hours after acute ischemic stroke. *N Engl J Med* 2008; 359: 1317-1329.
 - 11) Powers WJ, Rabinstein AA, Ackerson T, Adeoye OM, Bambakidis NC, Becker K, Biller J, Brown M, Demaerschalk BM, Hoh B, Jauch EC, Kidwell CS, Leslie-Mazwi TM, Ovbiagele B, Scott PA, Sheth KN, Southerland AM, Summers DV, Tirschwell DL. Guidelines for the Early Management of Patients With Acute Ischemic Stroke: 2019 Update to the 2018 Guidelines for the Early Management of Acute Ischemic Stroke: A Guideline for Healthcare Professionals From the American Heart Association/American Stroke Association. *Stroke* 2019; 50: e344-e418.
 - 12) Berge E, Whiteley W, Audebert H, De Marchis GM, Fonseca AC, Padiglioni C, de la Ossa NP, Strbian D, Tsvigoulis G, Turc G. European Stroke Organisation (ESO) guidelines on intravenous thrombolysis for acute ischaemic stroke. *Eur Stroke J* 2021; 6: I-LXII.
 - 13) Kimura K, Iguchi Y, Shibazaki K, Aoki J, Uemura J. Early recanalization rate of major occluded brain arteries after intravenous tissue plasminogen activator therapy using serial magnetic resonance angiography studies. *Eur Neurol* 2009; 62: 287-292.
 - 14) LeBreton H, Topol E, Plow EF. Evidence for a pivotal role of platelets in vascular reocclusion and restenosis. *Cardiovasc Res* 1996; 31: 235-236.
 - 15) Liu J, Hu X, Wang Y, Guan X, Chen J, Liu H. The safety and effectiveness of early anti-platelet therapy after alteplase for acute ischemic stroke: A meta-analysis. *J Clin Neurosci* 2021; 91: 176-182.
 - 16) Casa LDC, Ku DN. Thrombus Formation at High Shear Rates. *Annu Rev Biomed Eng* 2017; 19: 415-433.
 - 17) El-Gengaihy AE, Abdelhadi SI, Kirmani JF, Qureshi AI. Thrombolytics. *Comprehensive Medicinal Chemistry II*. Elsevier Ltd 2006; 6: 763-781.
 - 18) Zinkstok SM, Roos YB; ARTIS investigators. Early administration of aspirin in patients treated with alteplase for acute ischaemic stroke: a randomised controlled trial. *Lancet* 2012; 380: 731-737.
 - 19) Chang Y, Kim BM, Bang OY, Baek JH, Heo JH, Nam HS, Kim YD, Yoo J, Kim DJ, Jeon P, Baik SK, Suh SH, Lee KY, Kwak HS, Roh HG, Lee YJ, Kim SH, Ryu CW, Ihn YK, Kim B, Jeon HJ, Kim JW, Byun JS, Suh S, Park JJ, Lee WJ, Roh J, Shin BS, Kim JM. Rescue Stenting for Failed Mechanical Thrombectomy in Acute Ischemic Stroke: A Multicenter Experience. *Stroke* 2018; 49: 958-964.
 - 20) Baek JH, Kim BM, Heo JH, Kim DJ, Nam HS, Kim YD. Outcomes of Endovascular Treatment for Acute Intracranial Atherosclerosis-Related Large Vessel Occlusion. *Stroke* 2018; 49: 2699-2705.
 - 21) Stracke CP, Fiehler J, Meyer L, Thomalla G, Krause LU, Lowens S, Rothaupt J, Kim BM, Heo JH, Yeo LLL, Andersson T, Kabbasch C, Dorn F, Chapot R, Hanning U. Emergency Intracranial Stenting in Acute Stroke: Predictors for Poor Outcome and for Complications. *J Am Heart Assoc* 2020; 9: e012795.
 - 22) Chen HX, Wang LJ, Yang Y, Yue FX, Chen LM, Xing YQ. The prevalence of intracranial stenosis in patients at low and moderate risk of stroke. *Ther Adv Neurol Disord* 2019; 12: 1756286419869532.