

# Comparison of laparoscopic evaluation of hepatosteatosi s with ultrasound findings

C. PEKSEN<sup>1</sup>, T.V. AKTOKMAKYAN<sup>1</sup>, O.A. SAVAS<sup>1</sup>, B. EDIZ<sup>2</sup>, A. SUMER<sup>3</sup>

<sup>1</sup>Department of General Surgery, Faculty of Medicine, Istinye University, Istanbul, Turkey

<sup>2</sup>Department of Biostatistics, Faculty of Medicine, Istinye University, Istanbul, Turkey

<sup>3</sup>Department of General Surgery, Beykent University Hospital, Istanbul, Turkey

**Abstract. – OBJECTIVE:** Nonalcoholic fatty liver disease (NAFLD) is a condition characterized by abnormal liver function because of lipid accumulation. NAFLD can range from simple fatty liver, which is usually harmless, to a more severe condition called non-alcoholic steatohepatitis (NASH), which involves inflammation, liver cell damage, cirrhosis, and liver cancer. Liver biopsy is considered the gold standard for diagnosing and staging hepatosteatosi s, but it is an invasive and expensive procedure. Non-invasive methods, such as ultrasound, and magnetic resonance imaging (MRI), can provide useful information without the need for an invasive procedure. This study aimed to compare laparoscopic findings of hepatosteatosi s with ultrasound data to create a classification that can identify individuals with NASH in operated patients.

**PATIENTS AND METHODS:** 120 patients who applied to the General Surgery Department of Istinye University Faculty of Medicine between 06/2022 and 12/2022 were included in the study. They were evaluated for hepatosteatosi s with preoperative ultrasound. Demographic, physical examination (BMI), laboratory, and radiological findings of the patients were recorded retrospectively. In addition, laparoscopy video recordings were reviewed retrospectively, and the findings were evaluated. Statistical analysis of the findings was made. The *p*-value was calculated using the Chi-square test; *p*-value <0.05 was considered statistically significant.

**RESULTS:** The mean age of 120 patients was 39.04 years, the mean BMI was 34.9 kg/m<sup>2</sup>, and 63.3% of them were female patients. Cholecystectomy was performed in 60 of 120 patients, and sleeve gastrectomy in 60 of them. It has been observed that there is a high correlation between the ultrasound grade and the laparoscopic stage of hepatosteatosi s (*r*=0.849) (*p*<0.05).

**CONCLUSIONS:** Laparoscopy results to be an effective method in the diagnosis and classification of NASH.

#### Key Words:

Hepatosteatosi s, Nonalcoholic Fatty Liver Disease, Ultrasonography, Laparoscopy.

## Introduction

Hepatic steatosi s, also known as fatty liver, is defined as the abnormal accumulation of fat within liver cells. It occurs when there is an imbalance between the uptake and synthesis of fatty acids and their export or oxidation within the liver. Non-Alcoholic Fatty Liver Disease (NAFLD) can further progress into non-alcoholic steatohepatitis (NASH) when there is inflammation, liver cell damage, and the potential for fibrosis or scarring. NASH is a more severe form of hepatic steatosi s that can lead to complications like cirrhosis, liver failure, and hepatocellular carcinoma. Characteristic imaging findings or histological confirmation of fatty changes in at least 5% of hepatocytes is required to diagnose fatty liver disease<sup>1-3</sup>.

It encompasses a morphological spectrum of fatty liver disease (FLD), hepatic steatosi s (fatty liver), and steatohepatitis, whether alcoholic FLD (AFLD) or non-alcoholic FLD (NAFLD). FLD tends to progress toward the development of cirrhosis and hepatocellular carcinoma. Despite the distinctions implied by these etiological definitions, it is often difficult to distinguish AFLD from NAFLD on purely morphological grounds<sup>4</sup>.

NAFLD prevalence (up to 30%) is strongly associated with an increased prevalence of obesity<sup>5</sup>. Obesity is the leading cause of NAFLD, but it can also be seen in normal Body Mass Index (BMI) people. Lipids stored in the abdominal region, particularly in the visceral area surrounding organs, are more metabolically active and release higher levels of free fatty acids and inflammatory substances. Centripetal obesity, also known as visceral or abdominal obesity, is considered to be more metabolically detrimental compared to peripheral obesity<sup>6</sup>.

Liver biopsy and histological evaluation have been considered to be the gold standard for diagnosing and assessing the severity of steatosi s, including NAFLD. Nevertheless, it contains risks, including

bleeding, infection, and damage to surrounding organs. However, the necessity of an invasive procedure is still controversial due to the lack of specific treatment for NAFLD. Therefore, liver biopsy is usually reserved for cases where there is uncertainty about the diagnosis or when additional information is needed for treatment decisions<sup>7</sup>.

Imaging methods such as ultrasonography, computed tomography scanning, and magnetic resonance imaging can be used to detect the fat ratio in the liver. Abdominal ultrasound (US) is the most commonly used imaging modality for diagnosing the presence of fat in the liver. Being widely available, relatively inexpensive, and not exposing the patient to ionizing radiation, it is the preferred initial imaging tool for assessing hepatic steatosis<sup>8</sup>.

Specific laparoscopic findings can contribute to the differential diagnosis of chronic liver diseases, providing visual information to differentiate between various conditions such as viral hepatitis, alcoholic liver disease, autoimmune hepatitis, primary biliary cirrhosis, and metabolic liver diseases<sup>9-12</sup>. Tanaka et al<sup>13</sup> reported a patient who developed cirrhosis due to NASH. On laparoscopy, diffuse small nodules were seen on the liver surface, with findings like alcoholic liver cirrhosis. However, the findings of laparoscopic NASH are not summarized or have not been characterized.

In the literature, another study by Tanaka et al<sup>14</sup> evaluated non-alcoholic steatohepatitis with laparoscopic findings and compared them with histological findings. By comparing these findings between NASH, alcoholic liver disease, and autoimmune hepatitis (AIH), they were able to identify some NASH-specific laparoscopic features<sup>14</sup>.

Our study was conducted to investigate the validity of the laparoscopic staging of hepatosteatosis, with the data collected from the surgeries performed by Istinye University, Faculty of Medicine, Department of General Surgery. We compared the preoperative abdominal ultrasound results with laparoscopic findings for the diagnosis of hepatosteatosis.

## Patients and Methods

This retrospective study was conducted according to the principles of the Helsinki Declaration and was approved by the Human Ethics Committee of the Istinye University, School of Medicine. All participants were informed about the study. Signed informed consent was given by all participants.

## Patients

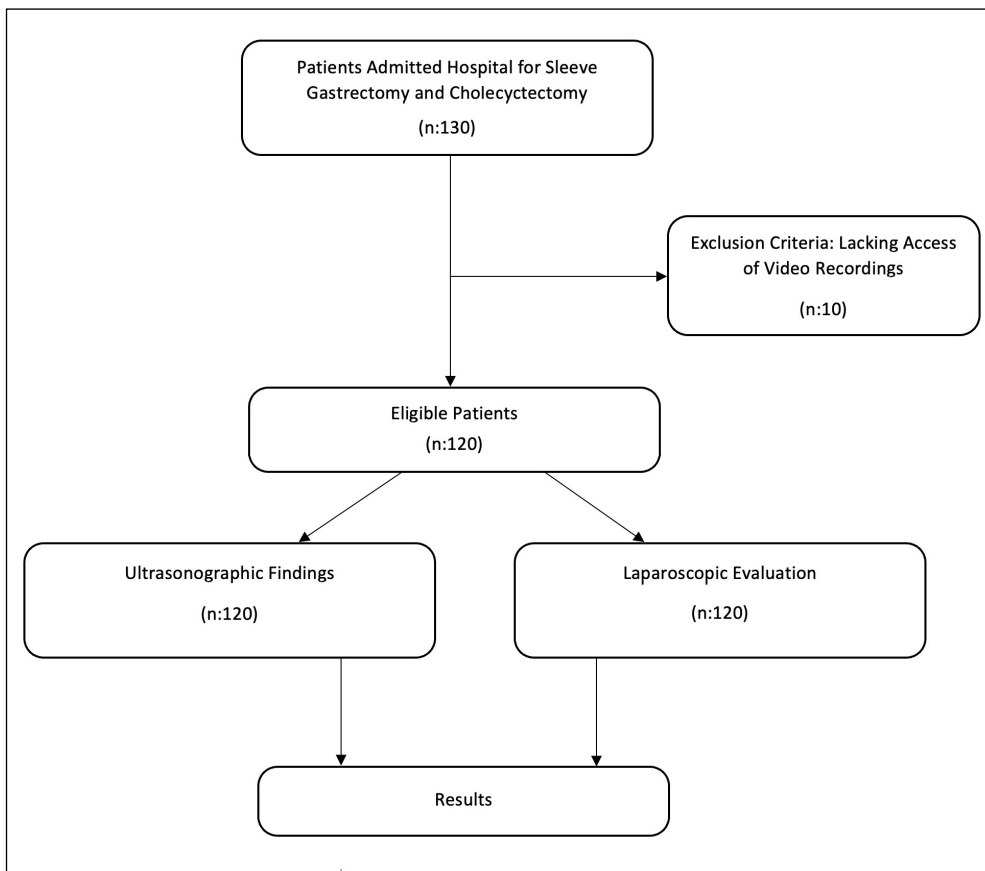
The study group consisted of patients from a retrospective database of the General Surgery Department of Istinye University, Faculty of Medicine. Patients registered in the database between June 30, 2022, and December 31, 2022, formed the working group. During this period, our hepatosteatosis registry enrolled 130 patients. Because of the lack of access to the laparoscopic video recording of 10 patients, 120 patients were included in the study group. We recorded the scores of the patients who were diagnosed with hepatosteatosis according to the preoperative ultrasound results. Then, the laparoscopy video records of these patients were reviewed retrospectively, and the view of the liver was compared with the ultrasound results. In addition, demographic information (age, gender), BMI results, and laboratory findings (AST, ALT, lipid profile, serological tests) of the patients in the study group were retrospectively analyzed and evaluated (Figure 1).

Anthropometric measurements were made in all patients included in the study. The patients' heights were measured on a standard height board, and their weight was measured with the aid of a standard scale, without shoes, only wearing light clothes. BMI was calculated as weight (in kilograms) divided by the square of height (in meters).

Laboratory evaluations included serum hepatic profile including aspartate aminotransferase (AST), alanine aminotransferase (ALT), serologic tests for hepatitis B and C, cholesterol, and triglyceride. All these tests were completed before surgery. ALT, AST, total cholesterol, and triglyceride values were classified as normal if they were within the laboratory reference range, and as high if they were above (Reference values; ALT: 0-55 U/L, AST: 5-34 U/L, Total Cholesterol <200 mg/dl Triglyceride 0-150 mg/dl). HBsAg, Anti-HBs, and Anti HCV values were classified as positive or negative (Reference values; HBsAg COI (neg < 1 < pos), Anti-HBs IU/L (neg < 10 < pos), Anti HCV COI (neg < 1 < pos).

## Ultrasonographic Evaluation

Ultrasonography is a safe, radiation-free, easily accessible, and inexpensive method that can be used in the diagnosis of hepatosteatosis. The normal liver parenchyma typically appears as a homogeneous tissue with equal or slightly greater echogenicity (brightness) than that of the renal cortex and spleen on ultrasound imaging. However, as fatty infiltration increases in the liver, it can lead to a change in echogenicity. As a result of hepatosteatosis, the liver becomes brighter or hyperechoic compared to the renal cortex and spleen on ultrasound.



**Figure 1.** Flowchart of the study.

A commonly used grading system divides steatosis into grades I, II, and III. The grades are defined based on the degree of echogenicity and the extent of obscuration of certain landmarks. Grade I steatosis refers to a mild increase in echogenicity, where the liver appears slightly brighter than the renal cortex and spleen. Grade II steatosis indicates a moderate increase in echogenicity, where the liver becomes brighter and obscures the echogenic walls of portal vein branches. Grade III steatosis represents a significant increase in echogenicity, where the liver is so bright that it obscures the diaphragmatic outline. However, there can be variability in interpretation between different observers<sup>15</sup>.

The patients were evaluated in the radiology clinic preoperatively. Mindray DC-85 device (Shenzhen Mindray Bio-Medical Electronics Co., Ltd., Shenzhen, China) was used during the evaluation. The examinations were performed using a 2-5 MHz convex transducer. Hepatosteatosi s grades were determined using echo differences of liver and kidney.

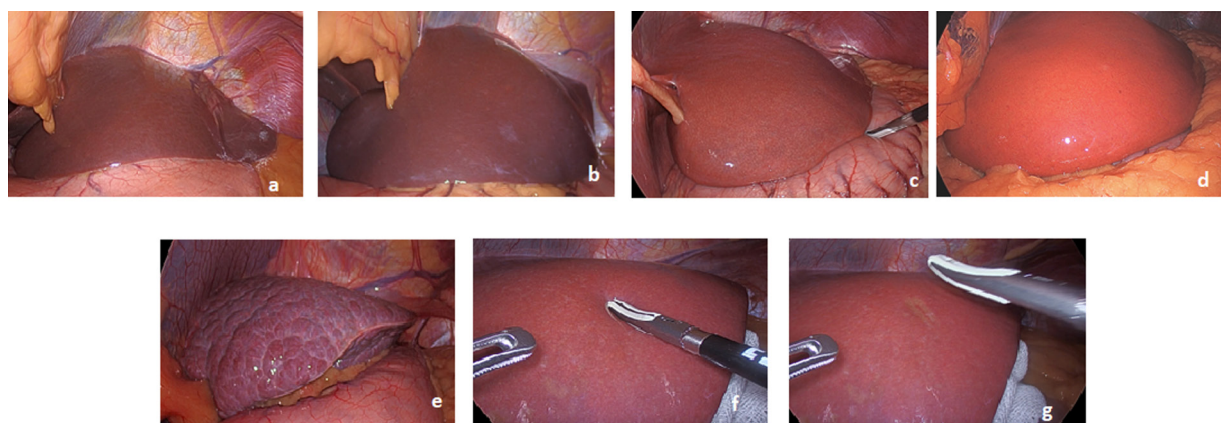
### **Laparoscopic Evaluation**

After the preoperative preparations were completed, the patients were taken to the operating room. The surgeries were performed under general anesthesia. The same endovision system (Stryker<sup>®</sup>, Kalamazoo, USA) was used for all surgeries. Laparoscopic sleeve gastrectomy operations were performed using standard 4 or 5 trocars. Laparoscopic cholecystectomy operations were performed using standard 4 trocars. After abdominal insufflation and trocar placement, the liver was evaluated for color, nodularity, edge sharpness, lipid deposit density, and duration of color change with pressure. The laparoscopic staging system created by us is summarized in Table I.

Images of our laparoscopy records regarding the criteria in the classification are shown in Figure 2. Different levels of liver tissue appearances, from normal liver tissue to cirrhosis and also color change time with pressure, have been found.

**Table I.** Laparoscopic classification.

	Normal	Grade 1	Grade 2	Grade 3	Cirrhosis
Color of the liver surface	Dark brown	Light brown	Yellowish	Yellowish- white	Whitish
Loss of edge sharpness	None	Mild	Moderate	Completely	Irregular
Yellow/white deposits	-	-	+	++	+++
Color change time with pressure	-	<2 seconds	2-5 seconds	>5 seconds	Rigidity
Nodularity	-	-	-	-	+
Ascites	-	-	-	-	+

**Figure 2.** a, Normal. b, Grade 1. c, Grade 2. d, Grade 3. e, Cirrhosis. f, Color change time under pressure. g, Color change time after relieving pressure.

### Statistical Analysis

Data were analyzed using the IBM Statistical Package for the Social Sciences statistical program, version 26 (IBM Corp., Armonk, NY, USA). Arithmetic mean, standard error, min, and max descriptive statistics of numerical data (age, height, weight) and frequency values of our other data with categorical values were found. The correlations between categorical variables were compared with Spearman's correlation analysis using the Chi-square tests. In the Spearman correlation test, the correlation coefficient ( $r$ ) is evaluated between 0 and 1. The closer the  $r$  value is to 1, the higher the relationship between the variables is interpreted. The significance level for the  $p$ -value was taken as 0.05 in our comparisons and in determining the relationship levels.

### Results

120 patients were available for the study, with an average age of 39.04 years (range 13-83), an average BMI of 34.9 kg/m<sup>2</sup> (range 18.7-57.28), and 76 female patients (63.3%). There was no

difference between the ages of men and women ( $p > 0.05$ ). Men's height and weight were significantly different from women's ( $p < 0.001$ ). Cholecystectomy was performed in 60 of 120 patients, and sleeve gastrectomy in 60 of them. The distribution of patients according to BMI classification is given in Table II.

It was observed that 12 (10%) of 120 patients had high ALT, and 10 (8.3%) had high AST values. The rate of patients with high total cholesterol value was 37.5% ( $n=45$ ), and the rate of patients with high triglyceride value was 34.2% ( $n=41$ ). It was observed that the HBsAg value was not positive in any of the 120 patients, and the anti-HCV

**Table II.** Distribution of patients by BMI classification.

BMI	Frequency	Percentage
18 - 24: Normal Weight	11	9.2
25 - 29: Overweight	32	26.7
30 - 34: Class 1 Obesity	16	13.3
35 - 39: Class 2 Obesity	23	19.2
≥ 40: Class 3 Obesity	38	31.7
Total	120	100.0

**Table III.** Classification of hepatosteatosis by ultrasound.

	Frequency	Percentage
<b>Normal</b>	36	30.0
<b>Grade 1</b>	26	21.7
<b>Grade 2</b>	30	25.0
<b>Grade 3</b>	28	23.3
<b>Total</b>	120	100.0

value was not positive in any of them. In addition, the number of patients with positive Anti-HBs values was found to be 30 (25%).

69 of 120 patients had normal liver size in ultrasound measurement, and 51 were abnormal. Usually, if the liver size is lower than 150 mm, it is considered normal, and if it is 150 mm or more, it is considered abnormal.

The classification of hepatosteatosis rates of the patients included in the study by ultrasonography is presented in Table III, and the classification by laparoscopy is presented in Table IV.

It was observed that ultrasound classification and laparoscopic classification were equal in 80 of 120 patients. While the grade of hepatosteatosis was higher in 19 patients, according to ultrasound findings, the grade of laparoscopic hepatosteatosis was found to be higher than ultrasound in 21 patients (Table V).

As the BMI increases, the rate of hepatosteatosis increases. Relationships between BMI and ultrasonographic and laparoscopic classification are shown in Tables VI and VII. When the tables are examined, it can be seen that the ultrasound rate is higher for HS normal or grade 3, and laparoscopic evaluation is higher for grade 1 and grade 2.

Statistically significant correlations were found between ultrasonographic and laparoscopic hepatosteatosis findings and other parameters (Table VIII). When the table is examined, it can be seen that the highest correlation is between the USG HS grade and the laparoscopic stage ( $r=0.849, p=0$ ).

**Table IV.** Classification of hepatosteatosis by ultrasound.

	Frequency	Percentage
<b>Normal</b>	23	19.2
<b>Grade 1</b>	38	31.7
<b>Grade 2</b>	41	34.2
<b>Grade 3</b>	18	15.0
<b>Total</b>	120	100.0

**Table V.** HS grade difference rates according to US and laparoscopy.

	Frequency	Percentage
<b>US grade higher than laparoscopy grade</b>	19	15.8
<b>Laparoscopy grade higher than US grade</b>	21	17.5
<b>Laparoscopy grade same as US grade</b>	80	66.7
<b>Total</b>	120	100.0

## Discussion

In this study, we aimed to evaluate the diagnostic accuracy of ultrasound in assessing hepatosteatosis and compare it with laparoscopic findings. Our results revealed a substantial agreement between ultrasound and laparoscopic classification of hepatosteatosis in the majority of cases. Moreover, we observed a significant correlation between body mass index (BMI) and the severity of hepatosteatosis, with laparoscopy demonstrating better grading in high BMI patients. The study highlights the potential of ultrasound as a cost-effective and non-invasive tool for hepatosteatosis diagnosis while emphasizing the safety and effectiveness of laparoscopy in providing direct visual evidence of liver conditions. These findings offer valuable insights into improving diagnostic approaches for hepatosteatosis.

In clinical practice, differentiating between NASH and simple steatosis is crucial because NASH represents the more aggressive form of NAFLD. NASH carries a higher risk of disease progression and can lead to liver fibrosis, cirrhosis, and ultimately end-stage liver disease<sup>16,17</sup>. Identifying individuals with NASH allows for closer monitoring, appropriate risk stratification, and targeted interventions to prevent or slow down disease progression. Ultrasound has been extensively used to evaluate hepatic steatosis due to its accessibility and descriptive sonographic findings that have been established since the 1980s<sup>18,19</sup>. While ultrasound is sensitive and specific for detecting liver steatosis, its sensitivity can be lower in cases of mild fat infiltration, as well as in morbidly obese patients with excessive amounts of adipose tissue<sup>20</sup>. Liang et al<sup>16</sup> do not agree with this view, as they stated that the use of ultrasound is effective in morbidly obese patients. Pulzi et al<sup>21</sup> showed that ultrasound alone can detect 76% of cases but with low sensitivity (46%).

**Table VI.** Relationship between ultrasonographic hepatosteatosi grade and BMI.

BMI	Grade of hepatosteatosi				Total
	Normal	Grade 1	Grade 2	Grade 3	
18 - 24: Normal Weight	9	1	1	0	11
25 - 29: Overweight	17	11	4	0	32
30 - 34: Class 1 Obesity	5	6	4	1	16
35 - 39: Class 2 Obesity	3	6	6	8	23
≥ 40: Class 3 Obesity	2	2	15	19	38
Total	36	26	30	28	120

**Table VII.** Relationship between laparoscopic hepatosteatosi grade and BMI.

BMI	Grade of hepatosteatosi				Total
	Normal	Grade 1	Grade 2	Grade 3	
18 - 24: Normal Weight	6	5	0	0	11
25 - 29: Overweight	14	15	3	0	32
30 - 34: Class 1 Obesity	2	8	5	1	16
35 - 39: Class 2 Obesity	1	7	11	4	23
≥ 40: Class 3 Obesity	0	3	22	13	38
Total	23	38	41	18	120

**Table VIII.** Correlation between ultrasonographic and laparoscopic HS findings.

	HS Grade by US		HS Grade by laparoscopy	
	<i>r</i>	<i>p</i>	<i>r</i>	<i>p</i>
Type of operation	.653**	0.000	.631**	0.000
BMI Grade	.681**	0.000	.732**	0.000
US liver size	.438**	0.000	.348**	0.000
HS Grade by US	1.000		.849**	0.000
HS Grade by laparoscopy	.849**	0.000	1.000	
ALT	.244**	0.007	.323**	0.000
AST	0.157	0.087	0.168	0.067
Total cholesterol	.379**	0.000	.403**	0.000
Triglyceride	.228*	0.012	.228*	0.012
HbsAg				
Anti-HBs	-0.161	0.079	-0.094	0.309
Anti-HCV				

(Spearman's correlations)

However, they stated that the sensitivity increased to 88.6% with the addition of some biochemical parameters to the ultrasound findings. Thus, in severely obese patients with lower US specificity, the inclusion of the score significantly improved the identification of these cases. To improve the non-invasive diagnosis of NAFLD, other scores aimed at the correlation between isolated laboratory findings have been defined<sup>21</sup>. In our study, it was observed that ultrasound classification and laparoscopic classification were equal in 80 out of 120 patients. Statistically, a high correlation between USG HS grade and laparoscopic stage ( $r=0.849$ ,  $p=0.000$ ) was found.

Iwamura previously described the laparoscopic findings of fatty liver disease as uneven thickening of the capsule and parenchymal depression in Kalk's classification<sup>22,23</sup>. The first laparoscopic classification of NASH was presented by Tanaka et al<sup>14</sup> in 2006. They compared the laparoscopic findings of 24 patients with the histological data. According to their results, the laparoscopic appearance of NASH was classified as chronic inactive hepatitis, as well as a whitish liver. They reported that the liver surface became less yellowish and more whitish as hepatic fibrosis developed.

Inui et al<sup>24</sup> described that when hepatic steatosis and fibrosis are combined, it becomes difficult to see the surface as mottled and yellow. The discoloration that occurs in patients with NASH may not only be related to capsule thickening but may also be due to hepatocyte damage and fibrosis. According to Tanaka et al<sup>14</sup>, a whitish change in the capsule is a strong promoter of NASH.

In our study, we defined a new laparoscopic classification system. We classified the liver surface from dark brown to yellowish white. We evaluated the loss of edge sharpness, yellow-white deposition rate, time of color change with pressure, and increase in nodularity in the liver.

Many studies<sup>21,25,26</sup> indicate that obesity is a metabolic disease that is associated with NASH and steatosis. However, according to the findings of Dixon et al<sup>25</sup> and Beymer et al<sup>26</sup>, this relationship is not absolute. According to these studies<sup>25,26</sup>, regardless of BMI, insulin resistance, the presence of hypertension, and high ALT values can predict the presence of NASH. Similarly, Pulzi et al<sup>21</sup> reported that there was no difference in BMI between groups with and without NASH.

Seki et al<sup>27</sup> reported that the prevalence of NASH in Japanese morbidly obese patients who

underwent bariatric surgery was 77.5% (79 out of 102 patients) based on intraoperative liver biopsies. Nikai et al<sup>28</sup> showed that 43 of 68 patients who underwent sleeve gastrectomy had NASH.

Similarly, we also found a significant correlation between the increase in BMI and the increase in laparoscopic grade of HS ( $r=0.732$ ,  $p=0$ ) and ultrasonographic HS grades ( $r=0.681$ ,  $p=0$ ). In addition, a higher correlation between BMI increase and grade increase with laparoscopy than with ultrasound was detected. Even so, laparoscopy was shown to be better than the US for grading high BMI patients with hepatosteatosis.

According to Pulzi et al<sup>21</sup>, only ALT is slightly elevated in liver enzymes and all NAFLD cases. They reported there was no significant correlation between the liver enzyme elevation level and the histopathological degree of steatosis. In contrast to patients with alcohol-induced liver disease, the AST/ALT ratio (AAR) among NAFLD patients is usually lower than 1<sup>20</sup>. Evidence that this ratio may reverse with advanced fibrosis or cirrhosis has been reported<sup>20,29,30</sup>.

According to our study, there was a significant correlation between the increase in ALT level and both ultrasonographic grade ( $r=0.244$ ,  $p=0.007$ ) and laparoscopic grade of hepatosteatosis ( $r=0.323$ ,  $p=0.000$ ). No significant correlation was found with the increase in AST level ( $p>0.05$ ).

Liver biopsy and histological evaluation have been considered the gold standard for diagnosing and assessing the severity of steatosis, including NAFLD. Nevertheless, it contains risks, including bleeding, infection, and damage to surrounding organs. It has a 3% morbidity rate and 0.03% mortality rate. Biopsy is contraindicated in coagulopathy, and relatively contraindicated in obesity<sup>30</sup>. Biopsy from all patients is not essential for staging NAFLD<sup>21</sup>.

In this study, we classified NASH by laparoscopy and examined the rates of agreement of ultrasound classification with our findings. This study has addressed a significant gap in the literature by comparing the efficacy of laparoscopic evaluation of hepatosteatosis with ultrasound findings. By examining the correlation between preoperative abdominal ultrasound results and laparoscopic findings, the study has provided valuable insights into the accuracy and reliability of these diagnostic methods. Additionally, the introduction of a new laparoscopic staging system for hepatosteatosis classification represents an innovative contribution to the field.

Furthermore, this research sheds light on the challenging differentiation between non-alcoholic steatohepatitis (NASH) and simple steatosis, which is crucial for effective clinical management. The findings of the study offer a practical approach to utilizing ultrasonography as a cost-effective and accessible method for grading NASH. Simultaneously, the study highlights the significance of laparoscopy as a reliable tool for direct visualization and diagnosis of NASH and cirrhosis.

By establishing a strong correlation between increasing body mass index (BMI) and higher grades of hepatosteatosis, the study provides important insights into the relationship between obesity and NASH development. The identification of specific laparoscopic features associated with NASH and cirrhosis contributes to enhancing the diagnostic accuracy and differentiation of various chronic liver conditions.

Future studies in this field can explore larger patient populations to further validate the laparoscopic staging system introduced in this research. Additionally, investigating the effectiveness of combining ultrasound and specific biochemical parameters for more accurate hepatosteatosis diagnosis can be a valuable avenue. Furthermore, prospective randomized clinical trials can be conducted to confirm the reliability of these diagnostic methods, ultimately enhancing their clinical utility in the management of hepatosteatosis and related liver conditions.

### **Limitations**

Limitations in our study should be mentioned. First, intraoperative liver biopsy was not taken from the patients included in the study, and histological investigation was not performed. Laparoscopic classification was made according to the gross appearance of the liver and includes subjective data. Another limitation of the study is that only US was used as a radiological imaging method.

### **Conclusions**

Ultrasonography is an inexpensive, simple, and non-invasive method that can grade NASH. Also, laparoscopy appears to be safe and effective in the diagnosis of NASH. According to the results of our study, the laparoscopy scoring system defined by our clinic is effective in the diagnosis of NASH and cirrhosis, as it provides the

advantage of direct patterning of the liver surface. Further prospective randomized clinical trials are needed to confirm these preliminary results.

---

### **Informed Consent**

Signed informed consent was given by all participants.

---

### **Ethics Approval**

The ethics approval was provided by the Human Ethics Committee of the Istinye University, School of Medicine, with protocol no. 23-165.

---

### **Conflict of Interest**

The authors declare they have no potential conflict of interest.

---

### **ORCID ID**

Caghan Peksen 0000-0003-3956-6282  
Talar Vartanoglu Aktokmakyan 0000-0003-0583-6440  
Osman Anil Savas 0000-0002-9696-5080  
Bulent Ediz 0000-0001-7337-2372  
Aziz Sumer 0000-0003-3938-3363

---

### **Authors' Contributions**

Conception: Aziz Sumer  
Writer: Caghan Peksen  
Supervision: Talar Vartanoglu Aktokmakyan, Aziz Sumer  
Data Collection: Osman Anil Savas, Bulent Ediz  
Design: Caghan Peksen  
Analysis: Bulent Ediz  
Critical Review: Talar Vartanoglu Aktokmakyan  
Literature Review: Osman Anil Savas

---

### **Funding**

None.

### **References**

- 1) Chalasani N, Younossi Z, Lavine JE, Charlton M, Cusi K, Rinella M, Harrison SA, Brunt EM, Sanyal AJ. The diagnosis and management of nonalcoholic fatty liver disease: Practice guidance from the American Association for the Study of Liver Diseases. *Hepatology* 2018; 67: 328-357.
- 2) EASL-EASD-EASO. EASL-EASD-EASO Clinical Practice Guidelines for the management of non-alcoholic fatty liver disease. *J Hepatol* 2016; 64: 1388-1402.
- 3) Roeb E, Steffen HM, Bantel H, Baumann U, Canbay A, Demir M, Drebbler U, Geier A, Hampe J, Hellerbrand C, Pathil-Warth A, Schattenberg JM, Schramm C, Seitz HK, Stefan N, Tacke F,



- Tannapfel A, Lynen Jansen P, Bojunga J. S2k-Leitlinie nicht alkoholische Fettlebererkrankungen [S2k Guideline non-alkoholic fatty liver disease]. *Z Gastroenterol* 2015; 53: 668-723.
- 4) Reddy JK, Rao MS. Lipid Metabolism and Liver Inflammation. II. Fatty liver disease and fatty acid oxidation. *Am J Physiol Gastrointest Liver Physiol* 2006; 290: 852-858.
  - 5) Powell EE, Wong VW, Rinella M. Non-alkoholic fatty liver disease. *Lancet* 2021; 397: 2212-2224.
  - 6) Reid AE. Nonalcoholic steatohepatitis. *Gastroenterology* 2001; 121: 710-723.
  - 7) Sanyal AJ. AGA technical review on nonalcoholic fatty liver disease. *Gastroenterology* 2002; 123: 1705-1725.
  - 8) Mottin CC, Moretto M, Padoin AV, Swarowsky AM, Toneto MG, Glock L, Repetto G. The role of ultrasound in the diagnosis of hepatic steatosis in morbidly obese patients. *Obes Surg* 2004; 14: 635-637.
  - 9) Tanimizu M, Ukida M, Ito T, Yamamoto K, Kobayashi H, Kakio T. Peritoneoscopic findings of autoimmune hepatitis: comparison of hepatitis C virus negative autoimmune hepatitis and hepatitis C virus positive autoimmune hepatitis. *Dig Endosc* 1994; 6: 170-175.
  - 10) Dagnini G. Alcoholic liver disease. In: Dagnini G, eds. *Clinical Laparoscopy*. Pauda: Piccin Medical Books 1980; 127-144.
  - 11) Fujioka S, Yamamoto K, Okamoto R, Miyake M, Ujike K, Shimada N, Terada R, Miyake Y, Nakajima H, Piao CY, Iwasaki Y, Tanimizu M, Tsuji T. Laparoscopic features of primary biliary cirrhosis in AMA-positive and AMA-negative patients. *Endoscopy* 2002; 34: 318-321.
  - 12) Minami Y, Seki K, Nishikawa M, Kawata S, Miyoshi S, Imai Y, Tarui S, Kakiuchi Y, Shinji Y, Kiyonaga G. Laparoscopic findings of the liver in the diagnosis of primary biliary cirrhosis: "reddish patch", a laparoscopic feature in the asymptomatic stage. *Endoscopy* 1982; 14: 203-208.
  - 13) Tanaka N, Ichijo T, Okiyama W, Muto H, Misawa N, Matsumoto A, Yoshizawa K, Tanaka E, Kiyosawa K. Laparoscopic findings of liver cirrhosis due to non-alkoholic steatohepatitis. *Dig Endosc* 2003; 15: 348-351.
  - 14) Tanaka N, Ichijo T, Okiyama W, Muto H, Misawa N, Matsumoto A, Yoshizawa K, Tanaka E, Kiyosawa K. Laparoscopic findings in patients with non-alkoholic steatohepatitis. *Liver International* 2006; 26: 32-38.
  - 15) Singh D, Das CJ, Baruah MP. Imaging of Non-Alcoholic Fatty Liver Disease: A Road Less Travelled. *Indian J Endocrinol Metab* 2013; 17: 990-995.
  - 16) Liang RJ, Wang HH, Liew PL, Lin JT, Wu MS: Diagnostic value of ultrasonography examination for nonalcoholic steatohepatitis in morbidly obese patients undergoing laparoscopic bariatric surgery. *Obes Surg* 2007; 17: 45-56.
  - 17) Angulo P. Nonalcoholic fatty liver disease. *N Engl J Med* 2002; 346: 1221-1231.
  - 18) Quinn SF, Gosink BB. Characteristic sonographic signs of hepatic fatty infiltration. *Am J Roentgenol* 1985; 145: 753-755.
  - 19) Di Lelio A, Cestari C, Lomazzi A, Beretta L. Cirrhosis: diagnosis with sonographic study of the liver surface. *Radiology* 1989; 172: 389-392.
  - 20) Adams LA, Talwalkar JA. Diagnostic Evaluation of Nonalcoholic Fatty Liver Disease. *J Clin Gastroenterol* 2006; 40: 34-38.
  - 21) Pulzi FB, Cisternas R, Melo MR, Ribeiro CM, Malheiros CA, Salles JE. New clinical score to diagnose nonalcoholic steatohepatitis in obese patients. *Diabetol Metab Syndr* 2011; 3: 3.
  - 22) Kalk H, Wildhirt E. Die Fettleber. In: Kalk H, Wildhirt E, eds. *Lehrbuch und Atlas der Laparoskopie und Leberpunktion*, 2 Auflage. Stuttgart: Georg Thieme Verlag 1962; 164-168.
  - 23) Iwamura K. Clinical and pathophysiological aspects of fatty liver of unknown etiology in modern Japan. *Tokai J Exp Clin Med* 1989; 14: 61-85.
  - 24) Inui Y, Kawata S, Tarui S. Laparoscopic findings of fatty liver using multiple regression analysis. "Spotty" and "diffuse" yellow color. *Endoscopy* 1990; 22: 27-30.
  - 25) Dixon JB, Bhathal PS, O'Brien PE. Nonalcoholic fatty liver disease: predictors of nonalcoholic steatohepatitis and liver fibrosis in the severely obese. *Gastroenterology* 2001; 121: 91-100.
  - 26) Beymer C, Kowdley KV, Larson A, Edmonson P, Dellinger EP, Flum DR. Prevalence, and predictors of asymptomatic liver disease in patients undergoing gastric bypass surgery. *Arch Surg* 2003; 38: 1240-1244.
  - 27) Seki Y, Kakizaki S, Horiguchi N, Hashizume H, Tojima H, Yamazaki Y, Sato K, Kusano M, Yamada M, Kasama K. Prevalence of nonalcoholic steatohepatitis in Japanese patients with morbid obesity undergoing bariatric surgery. *J Gastroenterol* 2016; 51: 281-289.
  - 28) Nikai H, Ishida K, Umemura A, Baba S, Nitta H, Sugai T, Sasaki A. Effects of Laparoscopic Sleeve Gastrectomy on Non-Alcoholic Steatohepatitis and Liver Fibrosis in Japanese Patients with Severe Obesity. *Obes Surg* 2020; 30: 2579-2587.
  - 29) Sass DA, Chang P, Chopra KB: Nonalcoholic fatty liver disease: A clinical review. *Dig Dis Sci* 2005; 50: 171-180.
  - 30) Piccinino F, Sagnelli E, Pasquale G, Giusti G. Complications following percutaneous liver biopsy: a multicenter retrospective study on 68276 biopsies. *J Hepatol* 1986; 2: 165-173.