

# Is testicular fixation to the scrotum necessary in patients with undescended testis? A comparative study

M. AZIZOĞLU<sup>1</sup>, S. SAGIR<sup>2</sup>

<sup>1</sup>Necmi Kadioğlu Esenyurt State Hospital, Pediatric Surgery Clinic, Istanbul, Turkey

<sup>2</sup>Department of Urology, Artuklu University Medical School, Mardin, Turkey

**Abstract. – OBJECTIVE:** This study aimed to compare the outcome of undescended testicle patients with and without transparenchymal sutures.

**PATIENTS AND METHODS:** Patients were divided into two distinct groups for evaluation: Group 1 (Testicular Fixation +): this group comprised 41 patients who underwent a procedure that involved testicular fixation. Group 2 (Testicular Fixation -): this group included 47 patients who had not undergone any testicular fixation.

**RESULTS:** The age difference between these groups was not statistically meaningful ( $p>0.05$ ). As for the presence of hypospadias, 2 patients (4.8%) in Group 1 and 3 patients (6.4%) in Group 2 were affected, showing no significant difference ( $p>0.05$ ). Post-surgical local infection was evident in 9.8% of Group 1 and 8.5% of Group 2 patients, showcasing no significant difference ( $p>0.05$ ). When assessing recurrence, both groups bore almost identical rates, 7.3% for Group 1 and 6.4% for Group 2 ( $p>0.05$ ). Atrophy was observed in 2.4% of Group 1 and 2.1% of Group 2, with no marked distinction ( $p>0.05$ ).

**CONCLUSIONS:** Both groups exhibited similar outcomes, suggesting that no fixation method was also a good option.

*Key Words:*

Orchidopexy, Undescended testis, Children, Atrophy.

## Introduction

The historical origins of orchidopexy are found in the late 18<sup>th</sup> century, with John Hunter pioneering foundational knowledge on the subject. In 1762, he detailed the first account of fetal testes descent, which illuminated understandings of testicular retractility, testicular undescend, and ectopia. During this period, the prevailing management for unresolved testicular descent involved the use of devices such as trusses, with some cases resorting to castration<sup>1</sup>. Progress in the field was later marked by Hunter's nephew, Thomas B.

Curling, a surgeon who displayed a keen interest in the domain. Curling, in 1871, became a frontrunner in attempting orchidopexy<sup>2</sup>. Notably, some of his techniques are still embedded within contemporary orchidopexy procedures. The establishment and broader acceptance of the procedure, however, coincided with the onset of antiseptic methodologies and was underscored by Thomas Annandale's documented successful orchidopexy in 1877<sup>3,4</sup>. Over the years, various innovative techniques were introduced, such as Torek's thigh fixation and Cabot's rubber band method. Currently, Petrivalsky's method using the dartos scrotal pouch seems to be the preferred choice<sup>3,4</sup>.

Nowadays, conditions like cryptorchidism and torsion are addressed by repositioning the testis within the inguinal area and securing it with a scrotal pouch. In many major medical institutions, a prevalent variation involves using a suture that traverses the fibrous layer surrounding the testes, known as the tunica albuginea. Research by Coughlin et al<sup>5</sup> indicates that when the suture material comes into contact with the inner testicular tissue, it can harm the intricate tubules, potentially impacting fertility in previously cryptorchid individuals. Both the fixation of the testis and not fixing it are acceptable in either scenario<sup>5,6</sup>. Yet, Ritchey and Bloom<sup>6</sup> presented an alternative method without the need for transparenchymal suture fixation. Their approach gained clinical significance with the evidence provided by Coughlin et al<sup>5</sup>.

This study aimed to compare the outcome of undescended testicle patients with and without transparenchymal sutures.

## Patients and Methods

### Patients and Groups

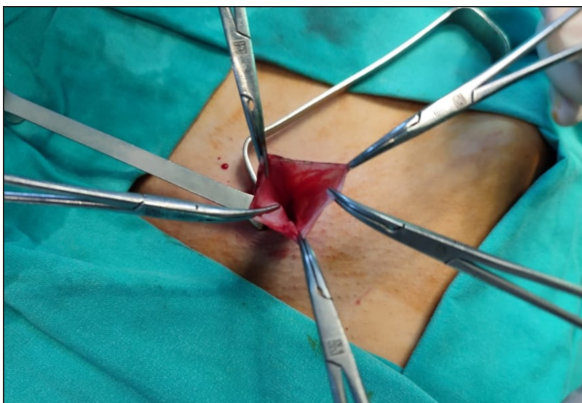
Using our institution's electronic database, we conducted a retrospective review of patient files.

We identified a total of 88 patients diagnosed with palpable undescended testis, as visualized in Figure 1. Patients were divided into two distinct groups for evaluation: Group 1 (Testicular Fixation +): this group comprised 41 patients who underwent a procedure that involved testicular fixation. Group 2 (Testicular Fixation -): this group included 47 patients who had not undergone any testicular fixation. The patients were evaluated retrospectively in terms of age, comorbidities, sociocultural levels of families, nationality, recurrence development, and progression to atrophy.

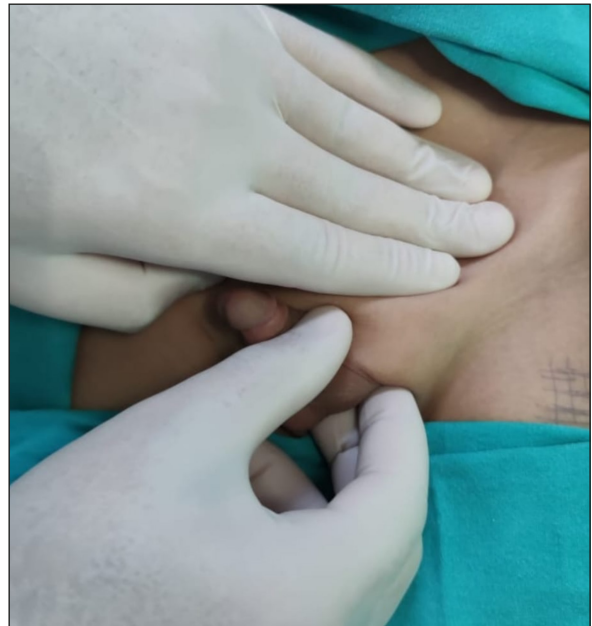
### ***Surgical Technique***

The operations were performed as an outpatient procedure under general anesthesia. The patient was positioned supine. A 2 cm incision was made along one of the Langer lines over the internal ring. The external oblique aponeurosis was incised in the direction of its fibers, avoiding injury to the ilioinguinal nerve. Once located, the testis and spermatic cord are freed from the canal and any cremasteric and ectopic gubernacular attachments. The tunica vaginalis was then dissected off the vas deferens and spermatic vessels. The proximal sac is dissected free, suture ligated, and ligated (Figure 2).

Sufficient dissection was performed until the testis could reach the scrotum (Figure 3). A tunnel was created from the inguinal canal into the scrotum by using a finger or a large clamp. A sub-dartos pouch was created by making an incision in the scrotum and using a hemostat inserted just under the skin to spread inferiorly. A clamp was carefully passed through this scrotal incision up into the inguinal canal, and the adventitial tissue around the testis was secured, taking care not to grasp the testis or vas deferens.



**Figure 2.** Dissection of the proximal hernia sac (patent processus vaginalis).

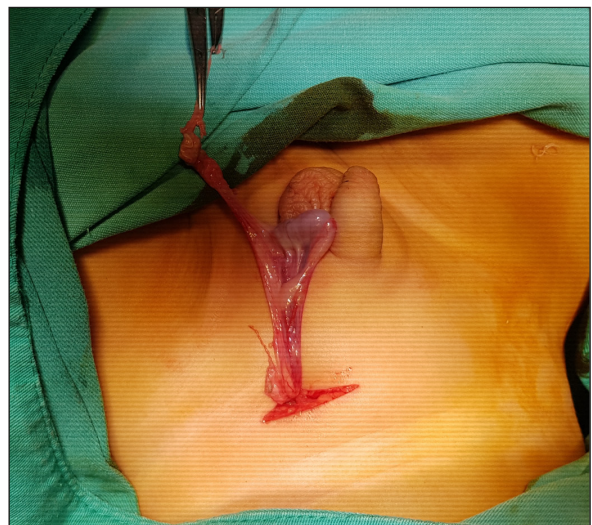

**Figure 1.** Physical examination of the palpable undescended testis.

At that time, in all patients (in both groups), the testis was thereby delivered into the dartos pouch, and a suture was used to narrow the neck of the pouch to prevent testicular retraction. Then, in Group 1 (Fixation +), the testis was fixed to the lower scrotal pouch with a single 5/0 vycril suture. Group 2 (Fixation -): the testis was not fixed to the lower scrotal pouch.

### ***Inclusion Criteria***

Cases of the unilateral undescended testis with palpable testis in the inguinal canal were



**Figure 3.** Dissection of the testis and relevant tissues.

included. Patients treated with the inguinal approach were included.

### **Exclusion Criteria**

Patients with soft tissue diseases or poor tissue healing, recurrence cases, or patients whose retrospective data could not be obtained were excluded from the study. The non-palpable testes, bilateral undescended testis (UDT), and patients treated with the laparoscopy and/or scrotal approach were excluded.

### **Ethical Approval**

Ethical approval was obtained from the Local Ethical Committee of Artuklu University (No.: 023/8-1 and date: 07.08.2023).

### **Statistical Analysis**

Statistical analysis was performed for patient data, including descriptive statistics, frequency, and other characteristics for all items. Continuous data were expressed as mean  $\pm$  standard deviation and non-continuous data as median (IQR). Continuous variables were analyzed with the Shapiro-Wilk and Kolmogorov-Smirnov tests to determine whether the data had a normal distribution. Continuous and normally distributed variables were compared using Student's *t*-test. Non-parametric tests were chosen when the data did not fit the normal distribution. Categorical variables were evaluated with a Chi-square test when necessary, and some data with the Fisher's exact test. Analyses were performed using SPSS Statistics for Windows, Version 26.0 (IBM Corp., Armonk, NY, USA). Statistical significance was recognized for  $p < 0.05$ .

## **Results**

The study encompassed a total of 88 patients, divided into Group 1 ( $n=41$ ) and Group 2 ( $n=47$ ). Delving into the specifics, the median age at surgery for Group 1 was 51 (8-86) months, while for Group 2, it was 49 (7-74) months. The age difference between these groups was not statistically meaningful ( $p > 0.05$ ). As for the presence of hypospadias, 2 patients (4.8%) in Group 1 and 3 patients (6.4%) in Group 2 were affected, showing no significant difference ( $p > 0.05$ ). The incidence of comorbidities was comparable between the two groups, with 4.9% in Group 1 and 4.3% in Group 2, again without a significant difference ( $p > 0.05$ ).

Evaluating the socio-cultural levels, Group 1 had 43.9% at a low level, 31.7% at a middle level, and 24.4% at a high level. In contrast, Group 2 comprised 46.8% low, 27.7% middle, and 25.5% high level, with no notable statistical variance ( $p > 0.05$ ). Nationality-wise, Turkish patients constituted 56.1% in Group 1 and 57.4% in Group 2, whereas Syrian patients made up 43.9% and 42.6% of the respective groups. The distribution was statistically indistinguishable ( $p > 0.05$ ).

Post-surgical local infection was evident in 9.8% of Group 1 and 8.5% of Group 2 patients, showcasing no significant difference ( $p > 0.05$ ). When assessing recurrence, both groups had almost identical rates, 7.3% for Group 1 and 6.4% for Group 2, and were statistically similar ( $p > 0.05$ ). Atrophy was observed in 2.4% of Group 1 and 2.1% of Group 2, with no marked distinction ( $p > 0.05$ ). Finally, concerning the follow-up durations, the median follow-up in Group 1 was 24 (6-45) months, while Group 2 stood at 22 (7-49) months ( $p > 0.05$ ) (Table I).

## **Discussion**

This study is a retrospective investigation into whether testes should be fixed to the scrotum during undescended testis surgery, or if such fixation is unnecessary. The results of our study found similar outcomes in both groups.

Cryptorchidism represents the most prevalent congenital anomaly of the urinary system, potentially impacting reproductive capabilities and elevating the risk of testicular tumors. Moreover, it acts as a significant risk factor for testicular torsion, emphasizing the need for prompt intervention<sup>7,8</sup>. For those exhibiting palpable cryptorchidism, the go-to treatment involves facilitating testicular descent and fixation through a groin-based method. While this technique is well-established and effective, it often results in a noticeable post-operative scar in the groin<sup>9,10</sup>.

A significant number of pediatric surgeons opt for transparenchymal sutured fixation of the rescued testis during torsion of testis surgical interventions<sup>11</sup>. Furthermore, about 75% of these surgeons also employ sutured fixation for the opposite testis<sup>12</sup>. Yet, the application of a transparenchymal suture during standard orchiopexies for cryptorchidism remains a topic of debate. Some professionals argue it offers added stability, while others consider it superfluous and linked to considerable complications<sup>13,14</sup>.

**Table I.** Comparison of groups.

	Group 1 (n=41)		Group 2 (n=47)		p-value
	n	%	n	%	
<b>Age at surgery (month)*</b>	51 (8-86)		49 (7-74)		>0.05
<b>Hypospadias</b>	2	4.8	3	6.4	>0.05
<b>Comorbidities</b>	2	4.9	2	4.3	>0.05
<b>Socio-cultural level</b>					
<i>Low</i>	18	43.9	22	46.8	>0.05
<i>Middle</i>	13	31.7	13	27.7	
<i>High</i>	10	24.4	12	25.5	
<b>Nationality</b>					
<i>Turkish</i>	23	56.1	27	57.4	>0.05
<i>Syrian</i>	18	43.9	20	42.6	
<b>Local infection</b>	4	9.8	4	8.5	>0.05
<b>Recurrence</b>	3	7.3	3	6.4	>0.05
<b>Atrophy</b>	1	2.4	1	2.1	>0.05
<b>Follow-up (month)*</b>	24 (6-45)		22 (7-49)		>0.05

\*median (IQR).

Potential hazards include testicular infarction and abscess development, which can eventually disrupt spermatogenesis and lead to reduced fertility. Although studies<sup>13</sup> on animals have underscored the detrimental fertility implications of suture fixation, research on humans<sup>14</sup> presents mixed findings.

The rate of cryptorchidism recurrence has been reported<sup>1,2,14</sup> from 0.2% to 13%. Analyzing various studies on testicular surgeries, differing recurrence rates emerge between transparenchymal suture and non-suture techniques. Meyer and Höcht<sup>15</sup> showcased a notably higher recurrence in the suture group (9.17%) compared to the non-suture group (4.25%). Similarly, Uijldert et al<sup>16</sup> reported a more pronounced recurrence rate for the suture group at 19.23%, compared to 10% for the non-suture group. In contrast, Hoseinpour et al<sup>17</sup> demonstrated minimal recurrence for the suture group at 2.86% and none for the non-suture group. Furthermore, Atici et al<sup>18</sup> presented zero recurrences for both groups. Our study aligned with Atici et al<sup>18</sup>'s findings, revealing no significant difference in recurrence between both techniques. Collectively, while some studies hint at the superiority of the non-suture method, consistent outcomes across all research emphasize the evolving nature of surgical best practices<sup>14-16</sup>.

The rate of testicular atrophy post-surgery across various studies<sup>14-16</sup> offers insight into the efficacy and safety of transparenchymal suturing vs. the no-suture technique. Notably, Meyer et al<sup>15</sup> and our study found comparable

atrophy rates for both groups, suggesting equivalent safety profiles for the two techniques. However, Uijldert et al<sup>16</sup> indicated a higher atrophy rate for the suture group. Meanwhile, Atici et al<sup>18</sup> and Hirner et al<sup>19</sup> reported no atrophy for their study groups. Cumulatively, most studies<sup>18,19</sup>, including ours, emphasize a low risk of testicular atrophy, regardless of the surgical technique. However, individual patient factors and surgical nuances remain crucial for achieving optimal outcomes.

### Limitations

In our study, notable limitations include its retrospective nature, the confined sample size of patients, and its singular focus on those who applied to our hospital's pediatric surgery service. Moreover, being centered on a single institution further constrains the scope of our findings. However, a significant strength of our research is the inclusion of both Turkish and Syrian children, which enhances the validity of our results.

### Conclusions

Conclusively, our retrospective study evaluated testicular fixations during undescended testis surgery. Both groups exhibited similar outcomes, suggesting that no fixation methods are also a good option. Despite its limited sample size, our study contributes valuable insights into orchiopexy best practices, while emphasizing the significance of individualized patient care.

### Conflict of Interest

The authors report no conflict of interest.

### Funding

No funding was required.

### Ethics Approval

Ethical approval was obtained from the Local Ethical Committee of Artuklu University (No.: 023/8-1 and date: 07.08.2023).

### Informed Consent

Written informed consent was obtained from all individual participants and/or their guardians.

### Data Availability

The datasets generated during and/or analyzed during the current study are available from the corresponding author upon reasonable request.

### Authors' Contributions

Research concept and design: MA, SS  
 Data analysis and interpretation: MA, SS  
 Collection and/or assembly of data: SS  
 Writing the article: MA  
 Critical revision of the article: MA, SS  
 Final approval of the article: MM, SS.

### ORCID ID

M. Azizoğlu: 0009-0000-3563-1230  
 S. Sagir: 0000-0001-5300-8071.

## References

- Moore SL, Chebbout R, Cumberbatch M, Bondad J, Forster L, Hendry J, Lamb B, MacLennan S, Nambiar A, Shah TT, Stavrinides V, Thurtle D, Pearce I, Kasivisvanathan V. Orchidopexy for Testicular Torsion: A Systematic Review of Surgical Technique. *Eur Urol Focus* 2021; 7: 1493-1503.
- Piñón-Solis EO, Jiménez-Ríos MA, Scavuzo A, Martínez-Cervera PF. Oncological outcomes of retroperitoneal node dissection for residual masses after chemotherapy in germ cell tumor. *Retrospective analysis of 15 years. Cir Cir* 2021; 89: 703-709.
- Arslan S, Azizoglu M, Kamci, TO, Basuguy E, Aydogdu B, Okur MH, Karabel M, Onen A. The value of hematological inflammatory parameters in the differential diagnosis of testicular torsion and epididymo-orchitis in children. *Exp Biomed Res* 2023; 6: 212-217.
- Karkin K, Gürlen G. Does COVID-19 cause testicular damage? A cross-sectional study comparing hormonal parameters. *Eur Rev Med Pharmacol Sci* 2022; 26: 3745-3750.
- Coughlin MT, Bellinger MF, LaPorte RE, Lee PA. Testicular suture: a significant risk factor for infertility among formerly cryptorchid men. *J Pediatr Surg* 1998; 33: 1790.
- Ritche ML, Bloom DA. Modified dartos pouch orchiopexy. *Urology* 1995; 45: 136.
- Taran I, Elder JS. Results of orchiopexy for the undescended testis. *World J Urol* 2006; 24: 231-239.
- Stec AA, Tanaka ST, Adams MC, Pope JC 4th, Thomas JC, Brock JW 3rd. Orchiopexy for intra-abdominal testes: factors predicting success. *J Urol* 2009; 182: 1917-1920.
- Pyörälä S, Huttunen NP, Uhari M. A review and meta-analysis of hormonal treatment of cryptorchidism. *J Clin Endocrinol Metab* 1995; 80: 2795-2799.
- Durell J, Johal N, Burge D, Wheeler R, Griffiths M, Kitteringham L, Stanton M, Manoharan S, Steinbrecher H, Malone P, Griffin SJ. Testicular atrophy following paediatric primary orchidopexy: A prospective study. *J Pediatr Urol* 2016; 12: 243.e1-4.
- Koh YH, Granger J, Cundy TP, Boucaut HA, Goh DW. Sutured point-fixation versus Jaboulay fixation for salvaged testicular torsion in children. *J Pediatr Surg* 2019; 54: 2631-2635.
- Frank JD, O'Brien M. Fixation of the testis. *BJU Int* 2002; 89: 331-333.
- Jafarova Demirkapu M, Karabag S, Akgul HM, Mordeniz C, Yananli HR. The effects of etomidate on testicular ischemia reperfusion injury in ipsilateral and contralateral testes of rats. *Eur Rev Med Pharmacol Sci* 2022; 26: 211-217.
- Anand S, Singh A, Bajpai M. Transparenchymal testicular suture: A systematic review and meta-analysis highlighting the impact of additional fixation suture during routine orchiopexy. *J Pediatr Urol* 2021; 17: 183-189.
- Meyer T, Höcht B. Langzeitergebnisse nach Orchidopexie: Transskrotale Fixierung versus Dartostasche [Long term results of orchidopexy: transscrotal fixation versus Dartos-pouch]. *Zentralbl Chir* 2004; 129: 476-479.
- Uijldert M, Meißner A, Kuijper CF, Repping S, de Jong TPVM, Chrzan RJ. Orchidopexy for bilateral undescended testes: A multicentre study on its effects on fertility and comparison of two fixation techniques. *Andrologia* 2019; 51: e13194.
- Hoseinpour M, Memarzadeh M, Sadeqi A. Comparative investigation of two surgical techniques of orchiopexy in the post-operative recurrence rate and testicular size in children in clinical trial study. *Adv Biomed Res* 2015; 4: 171.
- Atici A, Celikkaya ME, Akcora B. Is fixation suture necessary in undescended testicle surgery? *Ann Med Res* 2019; 26: 1275-1278.
- Hirner L, Rübber I, Lax H, Hirner C, Panic A, Darr C, Krafft U, Hadaschik B, Niedworok C, Rehme C. The value of an additional scrotal suture during orchidopexy. *J Pediatr Urol* 2021; 17: 82.e1-82.e5.