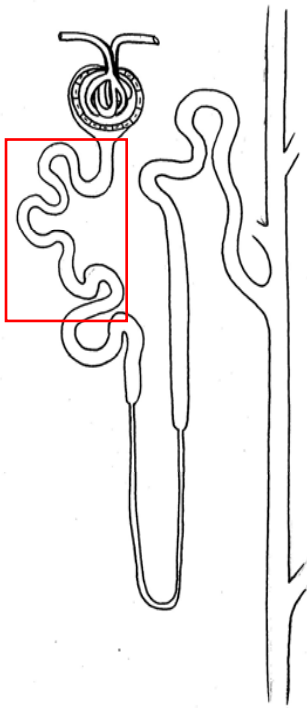
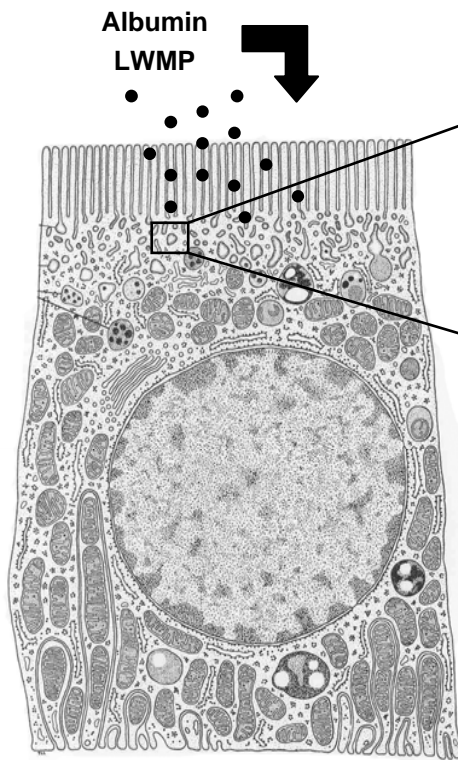


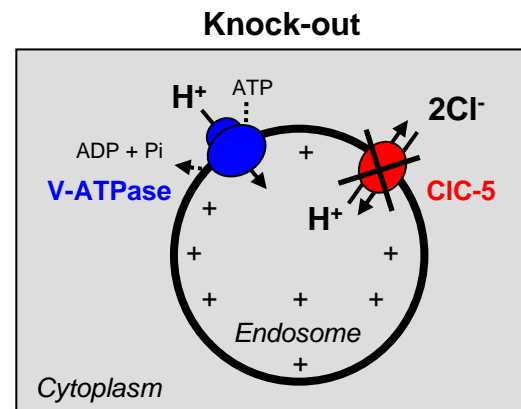
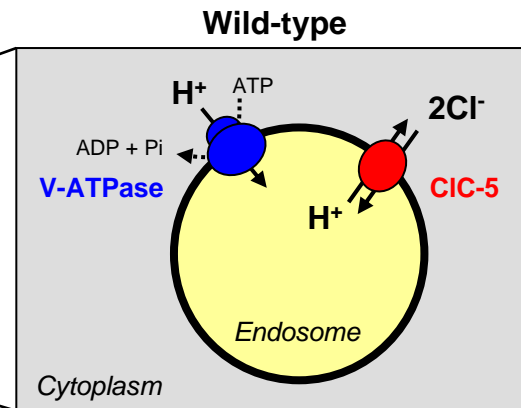
Nephron



Proximal tubule cell



Apical endosome



CIC-5	Vesicular acidification	Traffic of apical receptors	Endocytosis	Dent's disease phenotype
Wild-type	Normal	Normal	Normal	Absent
Knock-out	Impaired	Impaired	Impaired	Present