

CLINICAL REVIEW

Laser refractive eye surgery

Andrew Bastawrous *specialty registrar in ophthalmology*¹, Alexander Silvester *foundation year 2 doctor in ophthalmology*², Mark Batterbury *consultant ophthalmologist*¹

¹St Paul's Eye Unit, Royal Liverpool and Broadgreen University Hospitals NHS Trust, Liverpool L7 8XP, UK; ²Royal Liverpool and Broadgreen University Hospitals NHS Trust, Liverpool L7 8XP

Early attempts at refractive surgery used partial thickness corneal incisions to alter the curvature of the cornea, with the most popular technique being radial keratotomy. In 1990 the Prospective Evaluation of Radial Keratotomy study found that outcomes were unpredictable and unstable, and this led to the use of ablative laser refractive surgery instead.¹

We review evidence for the efficacy of laser refractive surgery mainly from randomised controlled trials and discuss suitability, contraindications, and potential complications of the procedure to help generalists in answering patients' queries.

Refractive error

Refractive error was recently reviewed in the *BMJ*.² Refraction (measured in dioptres) is the process by which light is focused on the retina. The optical components of the eye are the lens, the length of the eyeball, and the cornea. The cornea provides three quarters of the overall refractive power of the eye.

If the eyeball is too long or the cornea too curved ("steep"), light will focus in front of the retina and result in short sightedness (myopia; fig 1). If the eyeball is too short or the cornea is too flat, light will focus behind the retina and result in long sightedness (hyperopia). Myopia is therefore corrected by placing a concave lens in front of the eye or by surgically flattening the cornea, and hyperopia is corrected by using a convex lens or steepening the cornea. In astigmatism the refractive power of the eye is not the same in all meridians. Astigmatic errors can be partially corrected by flattening or steepening the cornea in the axis where refractive capacity is great or weak, respectively.

Laser treatment ablates (removes) corneal tissue. In myopia the aim is to flatten the centre of the cornea. In hyperopia ablating a mid-peripheral ring of cornea causes the centre to protrude (steepen).

Who is suitable for laser eye surgery and who is not?

Patients over 21 years with myopia (up to about 10 dioptres), hyperopia (up to about 4 dioptres) or moderate astigmatism and

a stable spectacle prescription (<0.5 dioptres change after one year) may be suitable for laser refraction surgery.

Box 1 lists the absolute and relative contraindications to laser eye surgery. Patients with intraocular inflammation, keratoconus, or active infection are not suitable for laser refractive surgery. Herpes simplex virus may be reactivated by the laser in patients with previous keratitis caused by the virus and those with active herpes simplex virus may be at risk of corneal perforation.³ Patients with dry eyes should be identified and treated before laser refractive surgery because dry eye syndrome is a common postoperative complication. Laser assisted in situ keratomileusis has been associated with a transient rise in intraocular pressure, so patients with glaucoma are at risk of further nerve damage. Such patients should be offered photorefractive keratectomy as an alternative refractive procedure,⁴ or advised against any type of cosmetic refractive laser surgery. Furthermore, corneal thinning after laser refractive surgery will make intraocular pressure measurements more difficult, which would affect the future management of glaucoma. Patients with pre-existing cataracts should not have refractive laser surgery because progressive cataract can cause refraction to shift. Modern cataract surgery carried out in a good NHS treatment centre has a long track record of predictable unaided vision.

People over the age of 40 are likely to develop presbyopia. Presbyopia is a normal ageing process caused by loss of flexibility of the crystalline lens within the eye. As presbyopia develops so does the need for reading glasses or a reading addition to existing glasses. Laser refractive surgery has no effect on the crystalline lens and the eye's ability to focus at both near and far distances, so it is not recommended for presbyopia. "Monovision" can be attempted in some patients with pre-existing refractive error and presbyopia; in this situation one eye is in focus for near vision and the other is in focus for distance vision.

How should suitability be assessed?

Careful preoperative assessment is necessary to determine whether a patient is suitable for laser refractive surgery, and if so which technique is most appropriate. It is useful to inquire

Summary points

- Refractive errors are common
- Laser eye surgery is an effective alternative to refractive correction with spectacles or contact lenses
- Glasses do not cause long term corneal problems, but contact lenses carry a small risk
- Serious complications of laser eye surgery are rare and can be minimised through patient selection and advances in technology
- Less serious complications are common and often under-reported as “side effects” or “symptoms”
- Data on long term safety and stability are lacking largely because techniques are still evolving

Sources and selection criteria

We searched PubMed for articles in English on laser refractive surgery. We also consulted guidelines issued by the Royal College of Ophthalmologists, the American Academy of Ophthalmologists, and the National Institute for Health and Clinical Excellence. We identified systematic reviews and randomised controlled trials as well as informative and relevant level C research. Search terms were “laser assisted in situ keratomileusis”, “laser epithelial keratomileusis”, “photoreactive keratotomy”, “myopia”, “hyperopia”, “astigmatism”, and “laser surgery”.

Box 1 Contraindications to laser eye surgery*Absolute*

- Unstable refraction
- Keratoconus
- Active infection
- Intraocular inflammation
- Uncontrolled glaucoma

Relative (precludes the patient from having surgery in most situations)

- Dry eye syndrome
- Thin cornea
- Blepharitis
- Cataract
- Glaucoma
- History of herpes simplex keratitis
- Ocular trauma
- Previous ocular surgery

about the patient’s expectations, to see whether they are realistic. Take a careful ophthalmic history; in particular ask about previous ocular surgery, history of glaucoma, infection, and dry eyes. Inquire about the patient’s occupation and lifestyle to assess the risk of flap injury after laser assisted in situ keratomileusis (for example, during contact sports). Examination should include measurements of visual acuity, refraction, curvature of the cornea (keratometry), corneal thickness (pachymetry), and pupil size. Slit lamp examination of the eye, including intraocular pressure measurement, and dilated funduscopy should be performed. Advise patients not to wear hard contact lenses for four weeks and soft contact lenses for two weeks before assessment.⁵ They may also need to abstain from wearing contact lenses for up to eight weeks before the final measurement and treatment.

It is now routine practice to perform a more detailed test of refraction known as wavefront aberrometry. This can refine and further personalise the laser treatment and can improve visual outcomes.

What do the procedures involve?

In laser assisted in situ keratomileusis a hinged partial thickness corneal flap is cut by a microkeratome or a femtosecond laser; the flap is then folded backwards, the underlying stromal bed is ablated, and the flap is replaced (fig 2). Microkeratome flap creation has excellent predictability in the central area for flap thickness but a greater disparity between the central thickness and peripheral thickness compared with femtosecond laser flap creation.⁶ Specific corneal and eye socket morphologies as well as available technology may lead a surgeon to choose one technique over another.

In photorefractive keratotomy and laser epithelial keratomileusis—both surface laser techniques—the epithelium is removed to expose the corneal stroma, which is then ablated (fig 2). In laser epithelial keratomileusis the epithelium is preserved as a sheet, which is replaced and held in place with a soft contact lens (fig 2). In both situations new epithelium grows back within a week.

The operations are performed as day cases with local anaesthetic eye drops and take 15-20 minutes.

What results can be expected?

Newer technologies allow more accurate measurements of the eye and more precise laser treatment. The healing response is unpredictable, however, so that scarring and refractive error vary and results are impossible to guarantee.

A Cochrane review of photorefractive keratotomy versus laser assisted in situ keratomileusis for myopia in 2005 analysed results from six randomised controlled trials and concluded that final uncorrected visual acuity after laser assisted in situ keratomileusis and photorefractive keratotomy is comparable at 12 months after treatment.⁷ Both techniques were equally effective at achieving a post-treatment refraction within ± 1.00 dioptres of target refraction at six and 12 months. Safety was measured as the proportion of eyes that lost two or more lines of best spectacle corrected visual acuity at six months or more after treatment; no difference in this outcome was found between the two treatments. The review found that laser assisted in situ keratomileusis was associated with less postoperative pain and more intraoperative discomfort and that visual recovery is more rapid after this technique than after photorefractive keratotomy.

A more recent meta-analysis compared photorefractive keratotomy with epithelial keratomileusis and found that the efficacy and accuracy outcomes were comparable at one month and 12 months.⁸ It also found no differences in post-procedural discomfort and corneal haze intensity between the two procedures.

A systematic review of the patient reported outcome of satisfaction after laser assisted in situ keratomileusis found that most patients (95.4%) were satisfied with the results.⁹ Dissatisfaction was associated with postoperative complications, such as dry eye, pain, glare, and halos.

In general, the bigger the refractive error the less accurate the result will be; high astigmatism may not respond well to treatment and cannot always be fully eliminated; and surface laser techniques produce better results for thin corneas.

How well can patients see after surgery?

Chief outcome measures are unaided visual acuity, best corrected visual acuity (with spectacles), and deviation from planned postoperative refraction.

Uncorrected visual acuity has been reported at 6/12 or better (driving standard in the UK approximates to 6/10 with both eyes open) in 46-100% of eyes, depending on the study and degree of myopia (box 2).¹⁰ Higher refractive errors have less predictable results and more undercorrections and overcorrections are seen.^{11 12}

Results for hyperopia are similar to myopia, although visual recovery is slower, with a higher incidence of regression and need for retreatment.

Retreatment is reported after 10% of procedures as a result of initial undertreatment or overtreatment (in high refractive errors intentional undertreatment is common) or regression.¹³

Retreatment is usually performed after three months, once refraction stabilises.

Some loss (for example, one line) of best corrected visual acuity is common but may not be noticed by the patient because the improvement in uncorrected visual acuity can be so profound.

It should be noted that postoperative 6/6 vision may be subjectively different from preoperative 6/6 best corrected visual acuity because of reduced contrast sensitivity, so patients with high visual demands should be cautioned when interpreting data.

What are the possible complications after surgery?

Box 3 lists the potential complications after laser surgery. Patients are routinely prescribed topical antibiotics (usually chloramphenicol) after surgery to reduce the risk of infection. Immediately after the procedure, patients are advised to wear sunglasses (because of mild photophobia) and to arrange for someone to drive them home. Patients should contact the clinic or hospital if they develop loss of vision, increasing redness, or more than mild pain. They are advised not to play contact sports or swim for at least four weeks. Serious complications from refractive surgery are rare but can occur.

Excessive ablation can result in the loss of corneal stability and lead to the serious sight threatening complication of corneal ectasia. A systematic review by the National Institute for Health and Clinical Excellence (NICE) reported a median 0.2% (range 0-0.87%) risk of ectasia after laser assisted in situ keratomileusis; no risk estimates were reported for photorefractive keratotomy.

The risk of infectious keratitis can be reduced by preoperative preparation (lid hygiene and disinfection of skin and eyelids with iodine) and postoperative antibiotics. The incidence of this complication after laser assisted in situ keratomileusis in published studies of more than 1000 cases ranged from 0% to 0.19%.¹⁴ These figures are comparable to the incidence of microbial keratitis in contact lens wearers (daily wear soft contact lenses 1/2000 a year (0.05%), rigid gas permeable lenses 1/3000 a year (0.03%), and overnight wear lenses 1/500 a year (0.2%).¹⁵

Long term safety data are lacking largely because the techniques are rapidly evolving, so assumptions have to be made about the safety of the most up to date techniques. In a computer model simulating 30 years of contact lens wear versus laser assisted in situ keratomileusis in which multiple variables were tested, rigid gas permeable lenses were safer than laser treatment in every analysis. The safety of laser assisted in situ keratomileusis exceeded that for daily wear soft lenses only when assumptions were most favourable to laser treatment, whereas the safety of laser treatment always exceeded that for extended wear lenses except when assumptions were least favourable to laser treatment.¹⁶

Complications associated with flap formation in laser assisted in situ keratomileusis include thin, incomplete, and irregular flap creation. The introduction of the femtosecond laser, which is more precise, has reduced these.

Less serious complications are more common. Dry eye syndrome occurs in more than half of patients,¹⁷ is often transient, can be treated with conventional treatment including artificial tears, and improves over weeks to months.¹⁸ Problems with haze, glare, and night vision have been associated with photorefractive keratotomy and are less common after laser assisted in situ keratomileusis.

NICE guidance

NICE issued guidelines on laser surgery for the correction of refractive errors in 2006.¹⁹ The guidelines stated that photorefractive (laser) surgery for the correction of refractive errors is safe and efficacious in selected patients; they also acknowledged that laser treatment is a "fast moving area" and that new techniques are emerging. The guidelines made no recommendations about selection, indications, or contraindications, however, but stated that "doctors should be

Box 2 Visual acuity

Visual acuity is a measure of the spatial resolution of the visual processing system. It is measured using a high contrast (black on white) chart at a distance that approximates to infinity; the standard distance is taken as 6 m or 20 ft. This distance is the numerator in the expression of visual acuity (6/X or 20/X). The denominator is the distance at which the optotypes (usually letters but can be symbols or pictures) can be seen with "normal" vision or corrected vision. For example, someone with normal vision, "6/6," should be able to read the top letter of the chart at 60 m, so the denominator would be 60. Hence someone who can see the top letter at only 6 m or closer would have a Snellen visual acuity of 6/60. The terms "20/20" (more common in the United States) and "6/6" (more common in the United Kingdom) vision are the same, with "6/6" being the metric expression.

Box 3 Complications of laser eye surgery*Serious*

- Infectious keratitis
- Diffuse lamellar keratitis
- Flap related complications
- Corneal ectasia

Less serious

- Dry eyes
- Haze
- Reduced best corrected visual acuity

sure that the treatment is suitable for that particular eye of the person." They acknowledged the difficulty that patients have in identifying properly trained practitioners for the procedure; the Royal College of Ophthalmologists responded by outlining standards for laser refractive surgery.²⁰ The college recommended that laser refractive surgeons should hold the Certificate in Laser Refractive Surgery; they must be members of a medical defence organisation or maintain professional indemnity insurance; and they should undertake postoperative evaluation and provide guidance for patients, information on the consent process, and advertising and marketing material on the premises in which the surgery is undertaken.

Contributors: AB had the idea for the article; all authors contributed equally to preparing and editing the manuscript. AB is guarantor.

Funding: No special funding received.

Competing interests: All authors have completed the unified competing interest form at www.icmje.org/coi_disclosure.pdf (available on request from the corresponding author) and declare: no support from any organisation for the submitted work; no financial relationships with any organisation that might have an interest in the submitted work in the previous three years; and no other relationships or activities that could appear to have influenced the submitted work.

Provenance and peer review: Not commissioned; peer reviewed.

- 1 Waring GO, Lynn MJ, Fielding B, Asbell PA, Balyeat HD, Cohen EA, et al. Results of the Prospective Evaluation of Radial Keratotomy (PERK) study 4 years after surgery for myopia. *JAMA* 1990;263:1083-91.
- 2 Cochrane GM, du Toit R, Le Mesurier RT. Management of refractive errors. *BMJ* 2010;340:c1711.
- 3 Vrabcic MP, Durrie DS, Chase DS. Recurrence of herpes simplex after excimer laser keratotomy. *Am J Ophthalmol* 1992;114:96-7.

- 4 Kasetsuwan N, Pangilinan RT, Moreira LL, DiMartino DS, Shah SS, Schallhorn SC, et al. Real time intraocular pressure and lamellar corneal flap thickness in keratomileusis. *Cornea* 2001;20:41-4.
- 5 US Food and Drug Administration. LASIK. www.fda.gov/MedicalDevices/ProductsandMedicalProcedures/SurgeryandLifeSupport/LASIK/ucm061270.htm.
- 6 Ahn H, Kim JK, Kim CK, Han G, Seo K, Kim E, et al. Comparison of laser in situ keratomileusis flaps created by 3 femtosecond lasers and a microkeratome. *J Cataract Refract Surg* 2011;37:349-57.
- 7 Shortt AJ, Allan BDS. Photorefractive keratectomy (PRK) versus laser-assisted in situ keratomileusis (LASIK) for myopia. *Cochrane Database Syst Rev* 2006;2:CD005135.
- 8 Cui M, Chen X, Lu P. Comparison of laser epithelial keratomileusis and photorefractive keratectomy for the correction of myopia: a meta-analysis. *Chin Med J* 2008;121:2331-5.
- 9 Solomon K, Fernandez de Castro L, Sandoval H, Biber JM, Groat B, Neff KD, et al. LASIK world literature review; quality of life and patient satisfaction. *Ophthalmology* 2009;116:691-701.
- 10 Sugar A, Rapuano CJ, Culbertson WW, Huang D, Varley GA, Agapitos PJ, et al. Laser in situ keratomileusis for myopia and astigmatism: safety and efficacy: a report by the American Academy of Ophthalmology. *Ophthalmology* 2002;109:175-87.
- 11 Lindstrom RL, Hardten DR, Chu YR. Laser in situ keratomileusis (LASIK) for the treatment of low, moderate, and high myopia. *Trans Am Ophthalmol Soc* 1997;95:285-96.
- 12 Siganos DS, Popescu CN, Siganos CS, Margarithis VN. Seven years experience with LASIK for myopia. *Ophthalmologia* 1999;47:50-2.
- 13 American Academy of Ophthalmology. Basic and clinical science course. *Refractive Surgery* 2006-2007. 2007:119.
- 14 Chang M, Jain S, Azar D. Infections following laser in situ keratomileusis: an integration of the published literature. *Surv Ophthalmol* 2004;49:269-80.
- 15 Dart JK, Radford CF, Minassian D, Verma S, Stapleton F. Risk factors for microbial keratitis with contemporary contact lenses: a case-control study. *Ophthalmology* 2008;115:1647-54.
- 16 McGee H, Mathers W. Laser-assisted in situ keratomileusis versus long-term contact lens wear: decision analysis. *J Cataract Refract Surg* 2009;35:1860-7.
- 17 Ambrosio R, Tervo T, Wilson S. LASIK-associated dry eye and neurotrophic epitheliopathy: pathophysiology and strategies for prevention and treatment. *J Refract Surg* 2008;24:396-407.
- 18 De Paiva CS, Chen Z, Koch DD, Hamill MB, Manuel FK, Hassan SS, et al. The incidence and risk factors for developing dry eye after myopic LASIK. *Am J Ophthalmol* 2006;141:438-45.
- 19 National Institute for Health and Clinical Excellence. Photorefractive (laser) surgery for the correction of refractive errors. 2006. www.nice.org.uk/guidance/IPG164.
- 20 Royal College of Ophthalmologists. Standards for laser refractive surgery. 2009. www.rcophth.ac.uk/page.asp?section=451§ionTitle=Clinical+Guideline.

Accepted: 29 March 2011

Cite this as: *BMJ* 2011;342:d2345

Areas of ongoing research

The use of wavefront aberrometry to improve outcomes
 Femtosecond laser treatment
 Improvements in laser assisted in situ keratomileusis flap creation
 Femtosecond laser intrastromal vision correction: “flapless” refractive laser surgery
 Femtosecond laser assisted refractive cataract surgery
 The treatment of presbyopia with excimer and femtosecond lasers

Additional educational resources*Resources for healthcare professionals*

Royal College of Ophthalmologists (www.rcophth.ac.uk/page.asp?section=368§ionTitle=Excimer±Laser±Refractive±Surgery)—Guidelines on various forms of laser refractive surgery
 National Institute for Health and Clinical Excellence (www.nice.org.uk/guidance/IPG164)—Clinical guidelines on photorefractive (laser) surgery for the correction of refractive error
 US Food and Drug Administration (www.fda.gov/MedicalDevices/ProductsandMedicalProcedures/SurgeryandLifeSupport/LASIK/default.htm)—Advice on laser assisted in situ keratomileusis
 International Society of Refractive Surgery (www.aao.org/isrs/)—Contains patient information leaflets, videos and information for doctors (US based)

Resources for patients

Royal College of Ophthalmologists (www.rcophth.ac.uk/page.asp?section=368&search)—A patient’s guide to excimer laser refractive surgery
 Medline Plus (www.nlm.nih.gov/medlineplus/lasereyesurgery.html)—Information on laser assisted in situ keratomileusis from the US National Library of Medicine

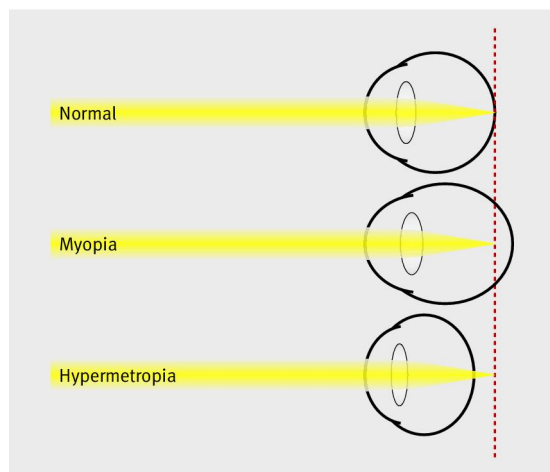
Figures

Fig 1 Diagram depicting emmetropic (normal), myopic, and hypertropic eyes. In myopia, light focuses in front of the retina, usually because of a long axial length, a steep corneal curvature, or a combination of the two. In hypermetropia, the converse is true—light focuses behind the retina, usually because of a short axial length, a flat corneal curvature, or a combination of the two

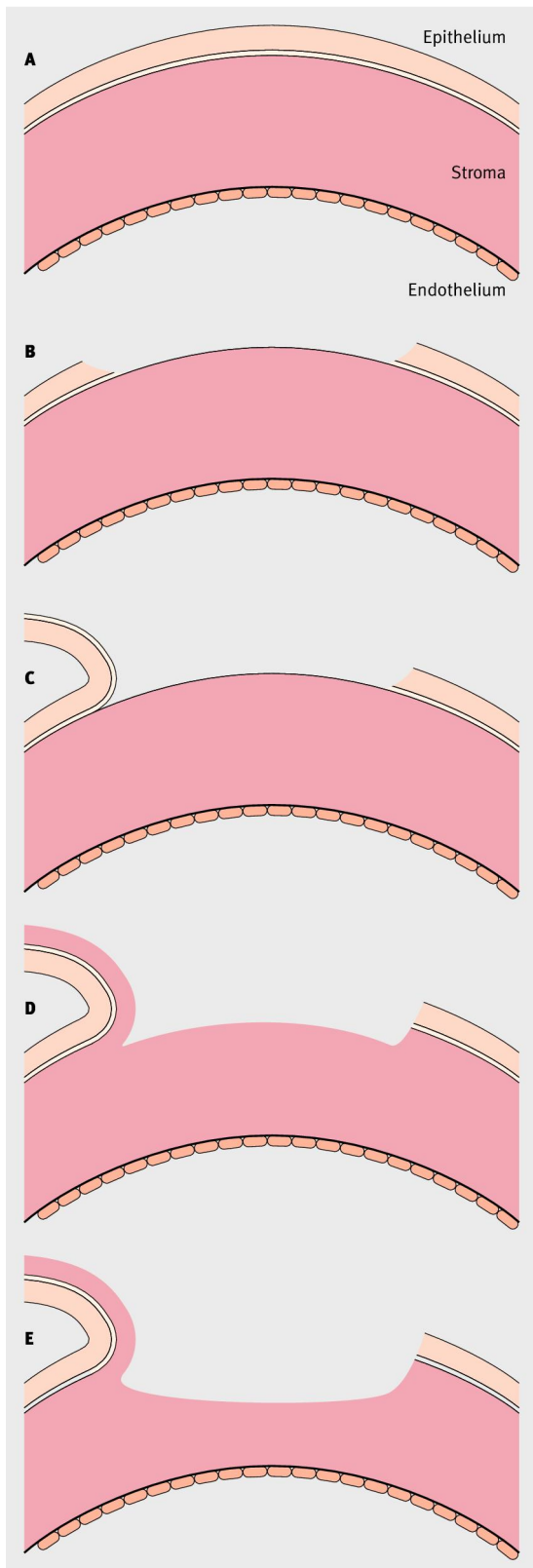


Fig 2 (A) Intact cross section of the cornea. (B) Photoreactive keratotomy: epithelium is removed, exposing the corneal stroma, which is then ablated. (C) Laser epithelial keratomileusis: as for photoreactive keratotomy except that the sheet of epithelium is preserved and replaced. (D) Laser assisted in situ keratomileusis: a hinged partial thickness corneal flap is cut by a microkeratome or a femtosecond laser, the flap is folded backwards, and the underlying stromal bed is ablated; the flap is then replaced. (E) Centrally flattened cornea after myopic treatment