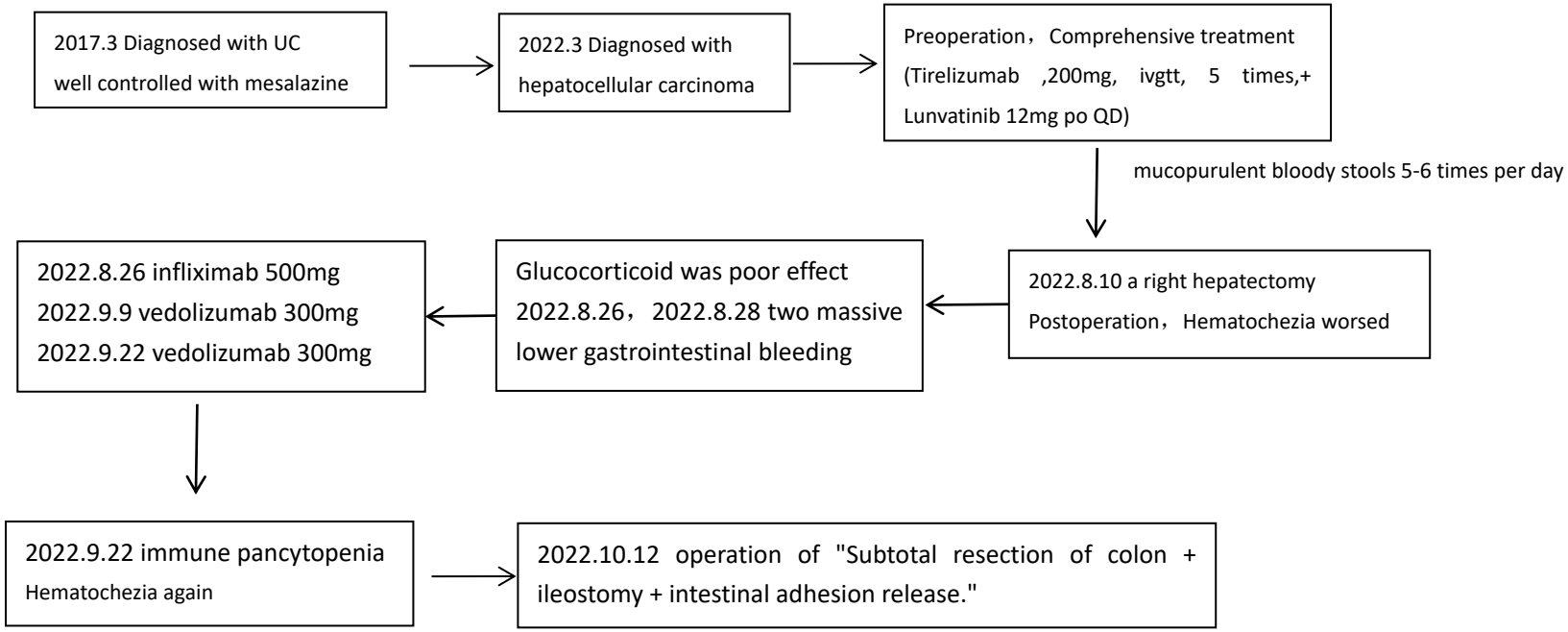
2017.3 Diagnosed with UC
well controlled with mesalazine
2022.3 Diagnosed with
hepatocellular carcinoma
Preoperation，Comprehensive treatment
(Tirelizumab ,200mg, ivgtt, 5 times,+
Lunvatinib 12mg po QD)
mucopurulent bloody stools 5-6 times per day
2022.8.10 a right hepatectomy
Postoperation，Hematochezia worsed
Glucocorticoid was poor effect
2022.8.26，2022.8.28 two massive
lower gastrointestinal bleeding
2022.8.26 infliximab 500mg
2022.9.9 vedolizumab 300mg
2022.9.22 vedolizumab 300mg
2022.9.22 immune pancytopenia
Hematochezia again
2022.10.12 operation of "Subtotal resection of colon +
ileostomy + intestinal adhesion release."