

UCSF

UC San Francisco Previously Published Works

Title

Parvovirus B19 Infection in Children With Arterial Ischemic Stroke

Permalink

<https://escholarship.org/uc/item/4v35q0bt>

Journal

Stroke, 48(10)

ISSN

0039-2499

Authors

Fullerton, Heather J
Luna, Jorge M
Wintermark, Max
et al.

Publication Date

2017-10-01

DOI

10.1161/strokeaha.117.018272

Peer reviewed

Parvovirus B19 Infection in Children With Arterial Ischemic Stroke

Heather J. Fullerton, MD, MAS; Jorge M. Luna, MS, MPH, MPhil; Max Wintermark, MD; Nancy K. Hills, PhD; Rafal Tokarz, PhD; Ying Li, MD; Carol Glaser, DVM, MD; Gabrielle A. DeVeber, MD, MSc; W. Ian Lipkin, MD; Mitchell S.V. Elkind, MD, MS; and the VIPS Investigators*

Background and Purpose—Case-control studies suggest that acute infection transiently increases the risk of childhood arterial ischemic stroke. We hypothesized that an unbiased pathogen discovery approach utilizing MassTag-polymerase chain reaction would identify pathogens in the blood of childhood arterial ischemic stroke cases.

Methods—The multicenter international VIPS study (Vascular Effects of Infection in Pediatric Stroke) enrolled arterial ischemic stroke cases, and stroke-free controls, aged 29 days through 18 years. Parental interview included questions on recent infections. In this pilot study, we used MassTag-polymerase chain reaction to test the plasma of the first 161 cases and 34 controls enrolled for a panel of 28 common bacterial and viral pathogens.

Results—Pathogen DNA was detected in no controls and 14 cases (8.7%): parvovirus B19 (n=10), herpesvirus 6 (n=2), adenovirus (n=1), and rhinovirus 6C (n=1). Parvovirus B19 infection was confirmed by serologies in all 10; infection was subclinical in 8. Four cases with parvovirus B19 had underlying congenital heart disease, whereas another 5 had a distinct arteriopathy involving a long-segment stenosis of the distal internal carotid and proximal middle cerebral arteries.

Conclusions—Using MassTag-polymerase chain reaction, we detected parvovirus B19—a virus known to infect erythrocytes and endothelial cells—in some cases of childhood arterial ischemic stroke. This approach can generate new, testable hypotheses about childhood stroke pathogenesis. (*Stroke*. 2017;48:2875-2877. DOI: 10.1161/STROKEAHA.117.018272.)

Key Words: case-control studies ■ carotid artery, internal ■ heart diseases ■ middle cerebral artery ■ parvovirus B19, human ■ polymerase chain reaction ■ stroke

Mounting evidence suggests that common infections transiently increase risk for childhood arterial ischemic stroke (AIS), perhaps by causing an inflammatory state that promotes coagulation or endothelial injury. The NIH-funded VIPS study (Vascular Effects of Infection in Pediatric Stroke) confirmed a robust association between infection in the prior week and childhood AIS; the most common prestroke infections were upper respiratory (present in 50%).¹ Serological assays for herpesviruses demonstrated a high prevalence of acute, mostly subclinical herpes infections.²

These findings present a paradox: childhood infection is common, whereas childhood stroke is rare. Although one possible explanation is an idiosyncratic immune response to infection contributing to stroke pathogenesis, another possibility is that unusual infections or combination of infections increase stroke risk. Although VIPS focused on herpesviruses, other infections could conceivably play a role. New MassTag-polymerase chain

reaction (PCR) techniques allow for efficient, simultaneous testing for a large number of pathogens. We performed a pilot study using this unbiased pathogen discovery approach to generate new hypotheses about the role of infection in childhood AIS.

Methods

The VIPS network of 37 enrolling sites enrolled and centrally confirmed 355 AIS cases and 354 stroke-free controls (2009–2014).^{1–3} Trauma controls, frequency matched on age, were children presenting with minor trauma and undergoing venous access for clinical purposes. We collected blood samples within 3 weeks of the stroke or at the time of enrollment in controls. Approval was obtained from ethics review committees at each site.

For this pilot study, we selected plasma samples from the first 161 cases and 34 trauma controls enrolled into VIPS and used MassTag PCR for DNA and RNA to detect 28 common childhood respiratory pathogens (Methods in the [online-only Data Supplement](#)).⁴ We confirmed infection by performing standard serologies (IgG and IgM) to detect an immune response to the pathogen.

Received June 6, 2017; final revision received July 7, 2017; accepted August 1, 2017.

From the Department of Neurology (H.J.F.), Department of Pediatrics (H.J.F.), and Department of Biostatistics and Epidemiology (N.K.H.), University of California, San Francisco; Department of Epidemiology (J.M.L., R.T., W.I.L., M.S.V.E.) and Department of Neurology (M.S.V.E.), Columbia University College of Physicians and Surgeons, New York, NY; Department of Radiology, Stanford University, Palo Alto, CA (M.W., Y.L.); Department of Pediatrics (Infectious Disease), Kaiser Permanente, Oakland, CA (C.G.); and Department of Neurology, Hospital for Sick Children, Toronto, Canada (G.A.D.).

*A list of all VIPS Investigators is given in the Appendix in the [online-only Data Supplement](#)

The online-only Data Supplement is available with this article at <http://stroke.ahajournals.org/lookup/suppl/doi:10.1161/STROKEAHA.117.018272/-/DC1>.

Correspondence to Mitchell S.V. Elkind, MD, MS, Department of Epidemiology, Columbia University, 710 W 168th St, New York, NY 10032. E-mail mse13@columbia.edu

© 2017 American Heart Association, Inc.

Stroke is available at <http://stroke.ahajournals.org>

DOI: 10.1161/STROKEAHA.117.018272

Table. Clinical and Vascular Imaging Characteristics of 14 Cases of Childhood Arterial Ischemic Stroke With a Respiratory Pathogen in Serum Detected by MassTag–Polymerase Chain Reaction

Virus	Age, y/Sex	Race	Vascular Imaging	Recent Infection*	Acute Herpes Infection†	Other Clinical History
Parvovirus	15/F	Hispanic	Long ICA stenosis		HSV	History of minor trauma
Parvovirus	7/M	White	Long ICA stenosis		HSV	History of minor trauma
Parvovirus	7/F	White	Long ICA stenosis		HSV/EBV	History of minor trauma
Parvovirus	7/M	Black	Long ICA stenosis	yes	HSV	Sickle cell, acute chest syndrome
Parvovirus	13/F	Hispanic	Long ICA stenosis	yes		Flu-like syndrome
Parvovirus	13/M	White	M2 occlusion			None
Parvovirus	7/F	White	M2 occlusion			Severe CHD, intracardiac clot
Parvovirus	1.6/M	White	Normal	yes	HSV	Severe CHD, intracardiac clot
Parvovirus	4/M	Hispanic	Normal			Severe CHD, venous clot
Parvovirus	4/M	White	Normal			Severe CHD
HHV6	16/F	White	Normal			None
HHV6	0.9/F	First nations	M1 banding	yes	HSV	Acute febrile illness with cough
Adenovirus	2/M	Hispanic	PICA occlusion	yes		Severe CHD, gastroenteritis, shock
Rhinovirus	1.9/M	White	Normal			None

CHD indicates congenital heart disease (defined as severe if required surgical correction); EBV, Epstein-Barr virus; F, female; HHV6, human herpesvirus 6; HSV, herpes simplex virus; ICA, internal carotid artery; M, male; M1, proximal segment of middle cerebral artery; and PICA, posterior inferior cerebellar artery.

*Clinical infection in prior 4 weeks, per parental report.

†Serological evidence of acute herpes infection was defined by either positive IgM titers or, when paired samples were available, by rising IgG titers, as detailed in reference 2 (Elkind MS et al. *Circulation*. 2016;133:732-741).

We used χ^2 tests (or Fisher exact, when appropriate) to compare proportions of cases and controls having infection. We combined these data with our previously published herpesvirus serological data to identify combinations of infections.²

Results

The 161 cases (42% female) had a median age of 7.3 years (interquartile range, 1.9–14) and the 34 controls (26% female), a median age of 9.1 years (interquartile range, 2.9–14). Per parental report, 34% of cases versus 21% of controls reported a clinical infection within the prior 4 weeks. Using MassTag PCR, we detected microbes in none of the 34 controls and

14 (8.7%) of 161 cases ($P=0.06$): parvovirus B19 ($n=10$), human herpesvirus 6 ($n=2$), adenovirus ($n=1$), and rhinovirus 6C ($n=1$). The copy number of parvovirus B19 in the 10 positive cases varied from 1.3 to 11×10^4 per microliter of plasma. All 10 had positive ($n=9$) or equivocal ($n=1$) parvovirus B19 IgG serologies confirming infection at some point; 4 had IgM antibodies indicating current or recent infection. Based on parental interview, only 2 of the 10 parvovirus B19 cases had a clinical infection in the prior month; none had slapped cheek syndrome (Table). Four had severe congenital heart disease; 3 of these had detectable thrombus (intracardiac, $n=2$; systemic venous, $n=1$). Five parvovirus B19 cases had a distinct arteriopathy involving a long segment of the intracranial anterior circulation (Figure).

Cases with serological evidence of acute herpesvirus infections were more likely to be positive for another organism on MassTag PCR (Figure 1 in the [online-only Data Supplement](#)): 9 of 56 (16%) herpes-positive cases versus 5 of 105 (5%) herpes-negative cases ($P=0.015$). Seven of the 9 cases with dual infection had parvovirus B19.

Discussion

In this exploratory pilot study, 6% of our cases of childhood AIS had parvovirus B19 infections. This common DNA virus, transmitted via the upper airway, can cause subclinical infection or flu-like symptoms and, in younger children, an exanthema known as slapped cheek syndrome (erythema infectiosum). We found no parvovirus B19 DNA in our

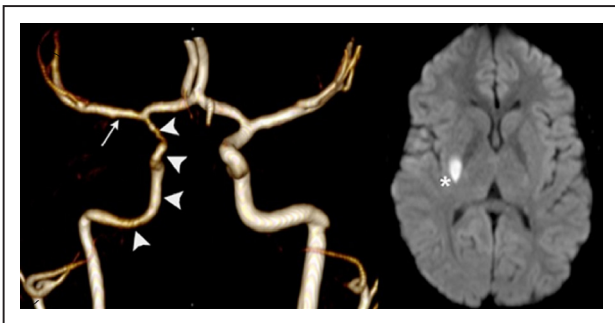


Figure. Brain magnetic resonance angiogram (left) in a case with parvovirus B19 and the characteristic long-segment distal left internal carotid artery stenosis (arrowheads) and proximal left middle cerebral artery irregularity (arrow). Brain diffusion weighted imaging (right) in the same case demonstrates a small acute left lenticulostriate infarction (asterisk).

controls; a serum study of 190 healthy individuals similarly identified no parvovirus B19 DNA or IgM antibodies.⁵ Prior literature supports the biological plausibility of a link between parvovirus, endothelial injury, and AIS: parvovirus B19 infects erythrocytes and binds to receptors on endothelial cells and has been linked to a wide array of vascular pathologies, including post-transplant vasculitis, mononeuritis multiplex, and, in case reports, AIS in the young.^{6–12} In children with sickle cell disease, stroke is a described complication of parvovirus B19 infection.⁷ Half of our parvovirus cases had complex congenital heart disease and cardioembolic stroke and half an arteriopathy involving a long segment of the distal internal carotid artery. We speculate that parvovirus may injure cardiac and arterial endothelium, promoting thrombosis or arterial stenosis. A role for parvovirus B19 in childhood stroke pathogenesis could have treatment implications: complications of parvovirus B19 infections, including parvovirus-associated vasculitis, have been successfully treated with immunomodulatory therapies, including intravenous immune globulin and antitumor necrosis factor- α therapy (etanercept).^{11–14}

Combining these pilot data with our previously published herpes serology data, we found that, in addition to individual infections, certain combinations of pathogens—such as a herpesvirus and parvovirus B19—may be important in childhood AIS. This supports the hypothesis that concurrent infection by multiple pathogens explains the paradox of a common exposure (childhood infection) associated with a rare outcome (childhood stroke).

Limitations of this pilot study include small sample size, potential bias in our control sampling and the inability to test for all pathogens, establish the timing of infections, or study the host immune response. The viremic phase is short after certain infections (including herpesviruses), limiting our ability to detect such pathogens through PCR of plasma. Respiratory samples (not collected in VIPS) may be more sensitive for respiratory pathogens. However, this study demonstrates the utility of an unbiased approach to pathogen discovery for generating testable hypotheses about the role for pathogens, and combinations of pathogens, in childhood AIS pathogenesis. The recently commenced VIPS II study will collect respiratory samples, test for a broader array of pathogens, and study the host immune response.

Sources of Funding

This study was supported by NIH R01 NS062820 (PIs Fullerton, DeVeber).

Disclosures

None.

References

1. Fullerton HJ, Hills NK, Elkind MS, Dowling MM, Wintermark M, Glaser CA, et al; VIPS Investigators. Infection, vaccination, and childhood arterial ischemic stroke: results of the VIPS study. *Neurology*. 2015;85:1459–1466. doi: 10.1212/WNL.0000000000002065.
2. Elkind MS, Hills NK, Glaser CA, Lo WD, Amlie-Lefond C, Dlamini N, et al; VIPS Investigators*. Herpesvirus infections and childhood arterial ischemic stroke: results of the VIPS study. *Circulation*. 2016;133:732–741. doi: 10.1161/CIRCULATIONAHA.115.018595.
3. Wintermark M, Hills NK, deVeber GA, Barkovich AJ, Elkind MS, Sear K, et al; VIPS Investigators. Arteriopathy diagnosis in childhood arterial ischemic stroke: results of the vascular effects of infection in pediatric stroke study. *Stroke*. 2014;45:3597–3605. doi: 10.1161/STROKEAHA.114.007404.
4. Briese T, Palacios G, Kokoris M, Jabado O, Liu Z, Renwick N, et al. Diagnostic system for rapid and sensitive differential detection of pathogens. *Emerg Infect Dis*. 2005;11:310–313. doi: 10.3201/eid1102.040492.
5. Heegaard ED, Petersen BL, Heilmann CJ, Hornsleth A. Prevalence of parvovirus b19 and parvovirus v9 DNA and antibodies in paired bone marrow and serum samples from healthy individuals. *J Clin Microbiol*. 2002;40:933–936.
6. Guidi B, Bergonzini P, Crisi G, Frigieri G, Portolani M. Case of stroke in a 7-year-old male after parvovirus B19 infection. *Pediatr Neurol*. 2003;28:69–71.
7. Wierenga KJ, Serjeant BE, Serjeant GR. Cerebrovascular complications and parvovirus infection in homozygous sickle cell disease. *J Pediatr*. 2001;139:438–442. doi: 10.1067/mpd.2001.117070.
8. Mandrioli J, Portolani M, Cortelli P, Sola P. Middle cerebral artery thrombosis in course of parvovirus B19 infection in a young adult: a new risk factor for stroke? *J Neurovirol*. 2004;10:71–74. doi: 10.1080/13550280490261752.
9. Ardalan MR, Shoja MM, Tubbs RS, Jayne D. Parvovirus B19 micro-epidemic in renal transplant recipients with thrombotic microangiopathy and allograft vasculitis. *Exp Clin Transplant*. 2008;6:137–143.
10. Dyrsen ME, Iwenofu OH, Nuovo G, Magro CM. Parvovirus B19-associated catastrophic endothelialitis with a Degos-like presentation. *J Cutan Pathol*. 2008;35(suppl 1):20–25. doi: 10.1111/j.1600-0560.2007.00974.x.
11. Magro CM, Crowson AN, Dawood M, Nuovo GJ. Parvoviral infection of endothelial cells and its possible role in vasculitis and autoimmune diseases. *J Rheumatol*. 2002;29:1227–1235.
12. Lenglet T, Haroche J, Schnuriger A, Maisonobe T, Viala K, Michel Y, et al. Mononeuropathy multiplex associated with acute parvovirus B19 infection: characteristics, treatment and outcome. *J Neurol*. 2011;258:1321–1326. doi: 10.1007/s00415-011-5931-2.
13. Modrof J, Berting A, Tille B, Klotz A, Forstner C, Rieger S, et al. Neutralization of human parvovirus B19 by plasma and intravenous immunoglobulins. *Transfusion*. 2008;48:178–186. doi: 10.1111/j.1537-2995.2007.01503.x.
14. Viguier M, Guillevin L, Laroche L. Treatment of parvovirus B19-associated polyarteritis nodosa with intravenous immune globulin. *N Engl J Med*. 2001;344:1481–1482. doi: 10.1056/NEJM200105103441919.