

GOOD NEWS FOR PEOPLE LIVING WITH PKDL IN EASTERN AFRICA

A study in Sudan found shorter, simpler, safer treatments to be very effective

THE PROBLEM

PKDL is short for post-kala-azar dermal leishmaniasis, a skin condition that can appear months or even years after treatment for visceral leishmaniasis – the world’s second-most deadly parasitic disease after malaria.

PKDL is most common in Eastern Africa and South Asia. In Sudan, around 20% of visceral leishmaniasis survivors develop PKDL later on.

Is PKDL serious?

Fortunately, PKDL is not life-threatening! But it can be very unpleasant. People affected by PKDL typically get rashes or lesions on their face and arms and sometimes elsewhere. It is not painful and most cases are mild and eventually self-heal. However, this visible skin condition can lead to social stigma and mental health issues.

PKDL is not directly infectious to other people, but if a sandfly bites affected skin and then goes on to bite

someone else, that person could potentially become infected with visceral leishmaniasis. This is a very important reason to treat PKDL – to prevent outbreaks of the more serious disease.

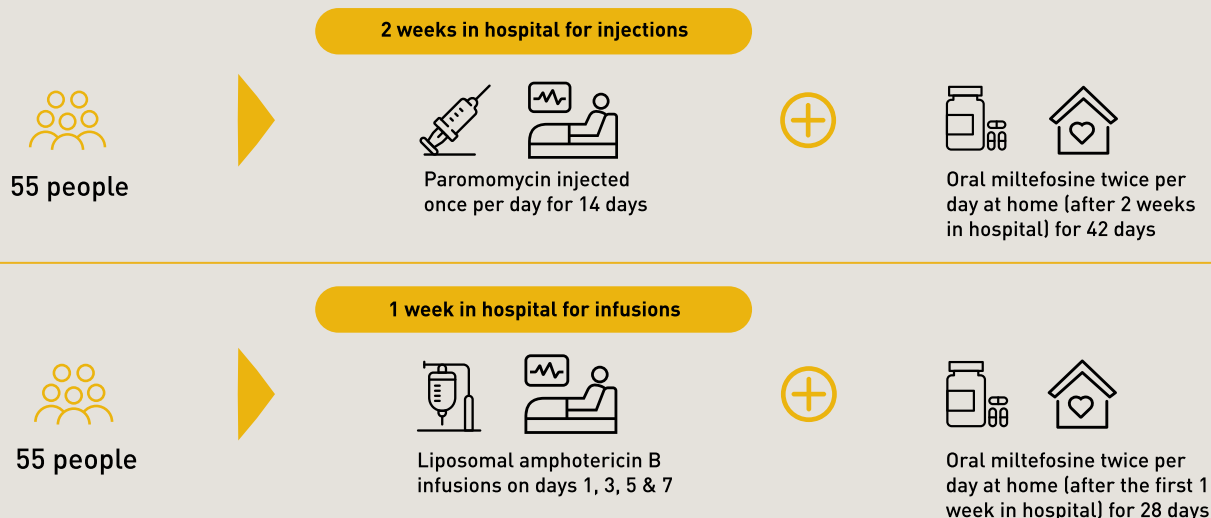
How is PKDL treated?

The current PKDL treatment in Sudan is sodium stibogluconate for 40–60 days. It is a toxic drug that requires painful injections and lengthy hospitalization with toxicity related to longer treatment duration. Due to the length of treatment it can be understandably difficult to convince people who feel well, other than having a challenging skin condition, to stay in hospital for up to two months and miss work or school.

To ensure that people are healthy and to prevent any risk of ongoing transmission of visceral leishmaniasis via sandfly bites, it is important to treat people affected by PKDL. This is why DNDi and partners conducted a study in Sudan to test the effectiveness of two shorter, safer, simpler, new treatment combinations for PKDL.

THE STUDY

DNDi and the Institute of Endemic Diseases at the University of Khartoum conducted this study in Doka, in Eastern Sudan.



THE RESULTS

- Of the 55 patients treated with the combination of **paromomycin and miltefosine**, **98% had 100% healing of their lesions** and no additional PKDL treatment after 12 months , even those with worse (grade 2 and 3) PKDL.
- Of the 55 patients treated with the combination of **liposomal amphotericin B and miltefosine**, **80% had 100% healing of their lesions** and no additional PKDL treatment after 12 months.
- Nearly **90% of the 110 study participants were children**. It was important to study treatment efficacy in children and adolescents because more than half of those affected by visceral leishmaniasis are kids.
- Patients were followed up for one year to assess the outcome of the treatment, though most patients were cured much earlier than one year.
- **Both treatment combinations were safe and well tolerated**. Drug reactions were mostly mild or moderate, with more of the drug reactions found in the group that received liposomal amphotericin B and miltefosine.

WHAT'S NEXT?

Results of this study will provide evidence to policy makers to guide recommendations of new and more patient friendly treatments, allowing people with PKDL to benefit from these findings.

You can find all the details of this PKDL treatment study in the scientific paper:

Younis BM et al. [Safety and efficacy of paromomycin/ miltefosine/ liposomal amphotericin B combinations for the treatment of post-kala-azar dermal leishmaniasis in Sudan: A phase II, open label, randomized, parallel arm study](#). PLOS Neglected Tropical Diseases 2023, 17(11): e0011780. doi: 10.1371/journal.pntd.0011780

