



The ameliorative effects of virgin olive oil and olive leaf extract on amikacin-induced nephrotoxicity in the rat

Abdelgayoum A. Abdel-Gayoum^{a,*}, Abdelrahman A. Al-Hassan^a, Ibrahim A. Ginawi^b, Ibraheem M. Alshankyty^a

^a Department of Clinical Laboratory Sciences, Faculty of Applied Medical Sciences, University of Hail, Hail, Saudi Arabia

^b Department of Community Medicine, Faculty of Medicine, University of Hail, Hail, Saudi Arabia

ARTICLE INFO

Article history:

Received 19 June 2015

Received in revised form

19 September 2015

Accepted 21 September 2015

Available online 30 September 2015

Keywords:

Amikacin

Nephrotoxicity

Olive oil

Olive leaf

Rat

ABSTRACT

Amikacin is an important antibiotic, and its use is limited because of the induced nephrotoxicity. Thus, search for natural and synthetic agents that can moderate amikacin toxicity never stopped. The present study aims to investigate the possible ameliorative effects of virgin olive oil and olive leaf extract against the amikacin-induced nephrotoxicity in rat.

Methods: 48 rats were distributed into 6 groups: 1-Animals of control (C) group were injected intraperitoneally (ip) with saline, 2-(AK); injected ip with amikacin {300 mg/kg/day for 12days}, 3-(OO) group: given olive oil {7 ml/kg/day for 16days}, 4-(OOLAK) group: given olive oil as in OO and amikacin for 12days, 5-(OL) group: given olive leaf extract {50 mg/kg/day for 16days}, 6-(OLAK) group: given leaf extract as in OL and amikacin for 12days. Animals were fasted and sacrificed. Serum was used for biochemical analysis and kidneys for histopathology.

Results: Serum urea and creatinine were significantly ($P < 0.001$) elevated in AK, and significantly dropped in the OOLAK and OLAK groups. Serum uric acid was reduced in AK by 45.29%. Kidneys from AK showed necrosis, whereas, those from OOLAK and OLAK showed mild histology. The serum triglyceride was decreased by 17.8% in OL, by 37.02% in OOLAK and by 31.48% in OLAK. The calculated amikacin effect showed a significant positive correlation with urea ($r = 0.521$, $P = 0.0004$), and a negative correlation with uric acid ($r = -0.58$, $P < 0.0001$).

Conclusion: The study confirmed nephrotoxicity of amikacin in rat which was ameliorated by virgin olive oil and by olive leaf extract. Amikacin did not cause dyslipidemia but reduced serum uric acid.

© 2015 The Authors. Published by Elsevier Ireland Ltd. This is an open access article under the CC BY-NC-ND license (<http://creativecommons.org/licenses/by-nc-nd/4.0/>).

1. Introduction

A wide variety of drugs and pesticides are known to induce renal toxicity in human and experimental animals. It has been reported that about 27% of acute kidney diseases in the United States are caused by usage of drugs [29]. Among these nephrotoxic drugs are cisplatin, oxytetracycline and cyclosporine [27,1,19]. Pesticides that kill insects by targeting their nervous system such as organophosphates and the carbamates are also known to induce nephrotoxicity [18,17]. The aminoglycosides, a group of related antibiotics, are known to generate reactive oxygen species (ROS)

which may cause a wide range of kidney related complications that include acute and chronic renal failure [5] and secondary hyperlipidemia [27,2]. Amikacin (AK) is an aminoglycoside antibiotic commonly used for the treatment of a wide spectrum of gram-negative bacterial infections. Like other nephrotoxic drugs, the clinical use of AK is limited because of its development of nephrotoxicity [28]. The nephrotoxic side effects of AK, characterized by tubular necrosis, have been documented in experimental animals [22] and in humans [28]. As in many aminoglycosides, the mechanism underlying AK toxicity is believed to be its ability to generate ROS [15]. ROS are known to mediate cascade processes leading to tissue damage in the kidney tubules. Several plant polyphenols, known to have antioxidant activity, have shown ameliorative effects on the AK induced nephrotoxicity [31], cisplatin nephrotoxicity [4] and oxytetracycline toxicity [1].

Virgin olive oil and more recently, the olive leaves were shown to be rich in antioxidant polyphenols such as oleuropein, verbascoside, ligstroside, tyrosol and hydroxytyrosol [11]. Olive leaf extracts

Abbreviations: AK, amikacin; OO, olive oil; OL, olive leaf; TG, triglyceride; LDL, low density lipoprotein; VLDL, very low density lipoprotein; EAE, estimated amikacin effect.

* Corresponding author.

E-mail address: aabdelgayoum@hotmail.com (A.A. Abdel-Gayoum).

<http://dx.doi.org/10.1016/j.toxrep.2015.09.007>

2214-7500/© 2015 The Authors. Published by Elsevier Ireland Ltd. This is an open access article under the CC BY-NC-ND license (<http://creativecommons.org/licenses/by-nc-nd/4.0/>).

are now marketed as anti-aging, immunostimulant, antioxidant, Anti-inflammatory and antimicrobial agents. Tavafi et al. [30] demonstrated that the use of olive leaf- extract can protect against gentamicin nephrotoxicity. In this study, we aimed to evaluate the protective effects of virgin olive oil and the ethanol extract of olive leaf against amikacin-induced nephrotoxicity in the rat. Since several nephrotoxic drugs are known to induce secondary dyslipidemia [2], beside assessing the kidney function parameters we measured the serum total cholesterol and triglyceride concentrations. To our knowledge, this is the first study to investigate the efficiency of olive leaf extract in the modulation of amikacin nephrotoxicity in experimental animals.

2. Materials and methods

2.1. Materials

Green olive leaves were picked from olive trees at Al-Zaitona Park, Hail, Saudi Arabia. 200 g of the air dried olive leaves were ground into fine powder. The nephrotoxic dose of amikacin was calculated according to Houghton et al. [13] and the olive leaf extract was prepared and dose calculated according to the method described by Tavafi et al. [30]. Briefly, the powder was extracted twice with 1 L of 80% (v/v) ethanol. The extract was filtered using a cotton mesh and the solvent of the pooled extract was evaporated under vacuum using rotary evaporator till dryness. The dry extract was stored refrigerated at 4 °C till use within two weeks. Fresh virgin olive oil was purchased from the local Hail market. Injectable amikacin (miacin) was obtained from Hikma Pharmaceuticals, Amman, Jordan.

Male Albino rats weighing 167.40 ± 26.34 g (150–210 g) were obtained from the Animal House-King Saud University, Riyadh, KSA, and placed in a temperature (21 ± 2 °C) and humidity (60 ± 5 %) controlled room in which a 12:12 h light:dark cycle was maintained. The animals had free access to a nutritionally adequate standard pelleted diet and tap water.

2.2. Protocol of experiment

Forty eight rats were distributed randomly into six groups (eight rats in each): 1-Control Group {C}; Animals of this group were injected intraperitoneally (ip) with saline daily for 12 days. 2-Amikacin Group {AK}: Animals were injected ip with amikacin (miacin) (300 mg/kg/d for 12 days). 3-Olive Oil Group {OO}: Animals of this group were given by gastric intubation olive oil (7 ml/kg/day for 16 days). 4-Olive Oil and Amikacin Group {OOAK}: The animals were fed with olive oil (7 ml/kg/day for 16 days), from day 4 the animals were injected ip with amikacin (300 mg/kg/d for 12 days). 5-Olive Leaf Extract Group {OL}: The animals were fed by gastric intubation weighed amounts of olive leaf extract dissolved in distilled water at a dose of 50 mg/kg/day for 16 days. 6- Olive Leaf Extract and Amikacin Group {OLAK}: Animals of this group were fed with olive leaf extract (50 mg/kg/day for 16 days), from day 4 the animals were treated ip with amikacin (300 mg/kg/day for 12 days). At the end of treatments, all rats were fasted overnight and sacrificed by cervical decapitation. Blood was collected from the trunk into plain tubes and serum was separated by centrifugation at $2000 \times g$ for 10 min at 5 °C. The left kidney of each rat was excised rapidly and kept in 10% formal- saline at 24 °C for routine histopathological examination by light microscopy.

2.3. Biochemical assays

Serum creatinine, urea, uric acid, triglyceride (TG) and total cholesterol were assayed spectrophotometrically using commercial kits from BioMerieux-France.

2.4. Histological examination

The kidneys were removed from formalin and embedded in paraffin wax. The paraffin-embedded blocks were cut into 4–5 μm slices and stained with hematoxylin and eosin. Five slides were randomly selected from each group and were examined under light microscope by a histopathologist unaware of the treatments. The intensity of the tubular injury was assessed as described by Celik et al. [7] with slight modification as follows:

Score	Stage of tubular injury
0 (Normal)	No necrosis
I (Mild)	usually single cell necrosis in scarce tubules
II (Moderate)	more than one cell involved in sparse tubules
III (Marked)	tubules exhibiting total necrosis in almost every power field

All experimental procedures were carried out in accordance to the Helsinki declaration for animal experiments and approved by the

Research Ethical Committee, Faculty of Applied Medical Sciences, University of Hail.

2.5. Calculation of estimated amikacin effect (EAE)

This was extracted from the ratio between the serum creatinine concentration (umol/L) in each rat and the amount of amikacin injected to the rat. The EAE in each rat was calculated according to the following equation: $EAE = (\text{serum creatinine (umol/L)} / (\text{total amount of amikacin given in 12 days}) \times 100$. (Zero value of EAE was given to animals not treated with the drug).

2.6. Statistical analysis

The presented data are means \pm SD. The differences between the means were computed by ANOVA using Statistical Package for Social Sciences version 16.0 (SPSS Inc., Chicago, IL, USA). The significance of differences between the means was carried out by Unpaired Student's *T*-test. *p* values <0.05 were considered significant. The regression analysis between the EAE (as independent variable) and various dependent parameters was carried out by Spearman's Regression analysis. *p* values <0.05 were considered significant.

3. Results

3.1. The kidney function parameters

The serum creatinine concentration was significantly elevated in the amikacin-alone treated group by 34.6%, whereas, it showed a significant drop by 33.3% in the OO group compared with control (Table 1). However, the OOAK group showed serum creatinine concentration not significantly different from that of the OO animals. On the other hand, the OL group had their serum creatinine levels significantly lower than control by 16%, whereas, the OLAK animals had the serum creatinine level lower by 36.63% from the amikacin-alone treated group and not different from those treated with olive leaf extract.

Similarly, the serum urea concentration was significantly elevated in the group treated with amikacin by 59.15%, whereas, the OOAK group showed a drop in their serum urea concentration by 43.89% compared to the AK group. However, the serum urea concentration in animals of OLAK group showed a significant decrease by 46.85% compared to the amikacin-alone treated group.

In contrast, the serum uric acid concentrations were significantly decreased in the AK, OOAK and the OLAK groups by 45.29%, 42.20% and 32.94%, respectively compared to control. However, the OLAK group exhibited a drop in the uric acid level by 20.83% compared to the OL group.

Table 1

The kidney function parameters and serum total lipids in (C) control, (AK) amikacin treated, (OO) olive oil-treated, (OOAK) co-treated with olive oil and amikacin, (OL) olive leaf extract treated and (OLAK) co-treated with olive-leaf extract and amikacin groups. The presented data are mean \pm SD. * $P < 0.05$, † $P < 0.01$, ‡ $P < 0.001$. a: significantly different from C, b: significantly different from AK, c: significantly different from OO, d: significantly different from OOAK, e: significantly different from OL.

	C	AK	OO	OOAK	OL	OLAK
Creatinine (umol/l)	66.30 \pm 7.07	89.28 \pm 20.33a‡	44.20 \pm 7.95 a‡b‡	53.04 \pm 9.19 a*b‡	55.69 \pm 8.84 a*b‡	56.57 \pm 5.30 a*b‡
% of change	--	+34.66% from C	-33.33% from C	-40.59% from AK +20% from OO	-16% from C	-36.63% from AK Not different from LE
Urea (mmol/l)	17.49 \pm 2.54	27.84 \pm 2.17a‡	15.61 \pm 1.30 b‡	15.62 \pm 0.69 b‡	15.85 \pm 2.47 b‡	14.79 \pm 1.72 b‡
% of change	--	+59.15% from C	-43.93% from AK	-43.89% from AK	-43.07% from AK	-46.85% from AK
Uric acid (umol/l)	404.46 \pm 58.29	221.26 \pm 44.61a‡	321.78 \pm 50.55 a* b†	233.75 \pm 47.58a‡	342.60 \pm 43.42 a*b†	271.22 \pm 35.68 a‡
% of change	--	-45.29% from C	+45.43% from AK	-27.17% from OO -42.20% from C	+46.56% from OOAK -15.29% from C	-20.83% from LE -32.94% from C
TG (mmol/l)	0.94 \pm 0.11	0.85 \pm 0.11	0.92 \pm 0.14	0.59 \pm 0.11 a‡ b†c‡	0.77 \pm 0.12a†c*d*	0.64 \pm 0.10a†b*c†
% of change	--	-9.73% from C	Not different from C	-37.02% from OO	-17.83% from C	-31.48% from C
Cholesterol (mmol/l)	2.02 \pm 0.21	1.92 \pm 0.34	1.84 \pm 0.26 a*	1.99 \pm 0.31	1.78 \pm 0.29 a*b*d*	2.00 \pm 0.30 e*
% of change	--	Not different from C	-8.79 from C	Not different from C	-11.75 from C	+12.23% from LE

3.2. Serum lipids

Interestingly, the serum TG level was significantly decreased in the OL animals by 17.8% compared to controls. Moreover, the serum TG concentrations in the OOAK and OLAK groups were dropped by 37.02%, and 31.48%, respectively compared to control. However, the serum total cholesterol was not significantly altered in the animals of AK, OO or OOAK, whereas, it was decreased in the OL group compared to control.

3.3. Changes in kidney histology

As shown in Fig. 1, the kidney sections from control, OO and OL groups revealed apparently normal tubules (Grade 0). However, sections of the kidneys from AK group showed marked tubular necrosis (Grade III). On the other hand, the sections of cortices from OOAK and OLAK groups showed moderate (Grade II) and mild (Grade I) appearances, respectively.

3.4. Regression analysis

Table 2 and Fig. 3 summarize the correlation between the EAE and the serum urea, uric acid and serum total lipids. Significant positive correlations were observed between the amikacin effect and serum creatinine and urea ($r = 0.484$, $P = 0.001$ and $r = 0.521$, $P = 0.0004$, respectively). On the other hand, a significant negative correlation was evident between the amikacin effect and serum uric acid ($r = -0.58$, $P < 0.0001$). Similarly, a slight negative correlation was shown between the amikacin effect and serum TG ($r = -0.28$, $P = 0.051$). However, no significant correlation was shown between the drug effect and serum cholesterol.

4. Discussion

Amikacin is one of the most commonly prescribed antibiotics for the treatment of Gram negative infections. The most accepted mechanism of action underlying the pathogenesis of its nephrotoxicity is the ability of the drug and its metabolites to generate oxygen free radicals [15,21]. This has guided the investigators to search for suitable potent antioxidants as protective agents against its induced nephrotoxicity. Olive oil is believed to be rich in polyphenols and has been tried as a protective agent against some nephrotoxic drugs [24]. Recently, olive leaves were reported

to be rich in polyphenols [30] and have shown antioxidant and anti-inflammatory activity [9]. While the availability of virgin olive oil is seasonal, olive leaves can be freely picked throughout the year from the numerous olive trees in Hail region. In the present study we studied the effectiveness of olive leaf extract in protecting against the amikacin nephrotoxicity compared to the olive oil. As expected, rats treated with amikacin alone exhibited significant elevation in the serum levels of creatinine and urea, indicating severe nephrotoxicity. This was confirmed by the severe degeneration of the kidney cortical tissues of these animals. The nephrotoxicity of amikacin, as other aminoglycosides, is well established and several authors have used antioxidant agents to ameliorate its toxicity [15,21]. However, treatment of the animals with olive oil prior to their exposure to drug slightly ameliorated the kidney function and cortical histology. The serum creatinine level was lower than the amikacin-alone treated animals and they exhibited moderate alleviation of the kidney cortical injury. On the other hand, the animals pretreated with olive-leaf extract prior to amikacin exposure had their serum creatinine concentrations significantly lower and their kidney cortical injury significantly ameliorated. Olive leaves are rich in polyphenols and their extract was used to protect against gentamicin nephrotoxicity [30] and carbon tetrachloride toxicity [6]. The reported polyphenols of olive, oleuropein, verbascoside and ligstroside, are powerful antioxidants which can sequester the generated drug induced oxygen free radicals in the kidney [14], and inhibit the pro-oxidant lipoxygenase enzyme activity [16]. The ameliorative effect of olive leaf extract against the amikacin nephrotoxicity was comparable or better than that of the virgin olive oil. The serum creatinine in the animals treated with both oil and drug was still higher than that treated with the olive oil alone, whereas, those exposed to leaf extract with the drug had their creatinine not different from those fed with leaf extract alone.

Interestingly however, amikacin treatment did not exhibit any elevation in serum triglyceride or cholesterol levels. This was different from our previous findings with other nephrotoxic drugs, where severe secondary dyslipidemia was observed in gentamicin-induced nephrotoxicity [3], and in cisplatin nephrotoxicity [2]. In these nephrotoxic drugs the mechanism underlying the secondary dyslipidemia was suggested to be increased cholesterol synthesis caused by the accumulation of mevalonate, the substrate and activator of HMG-CoA reductase. HMG-CoA reductase is the regulatory enzyme for cholesterol biosynthesis. Accumulation of mevalonate was thought to be due to its decreased catabolism

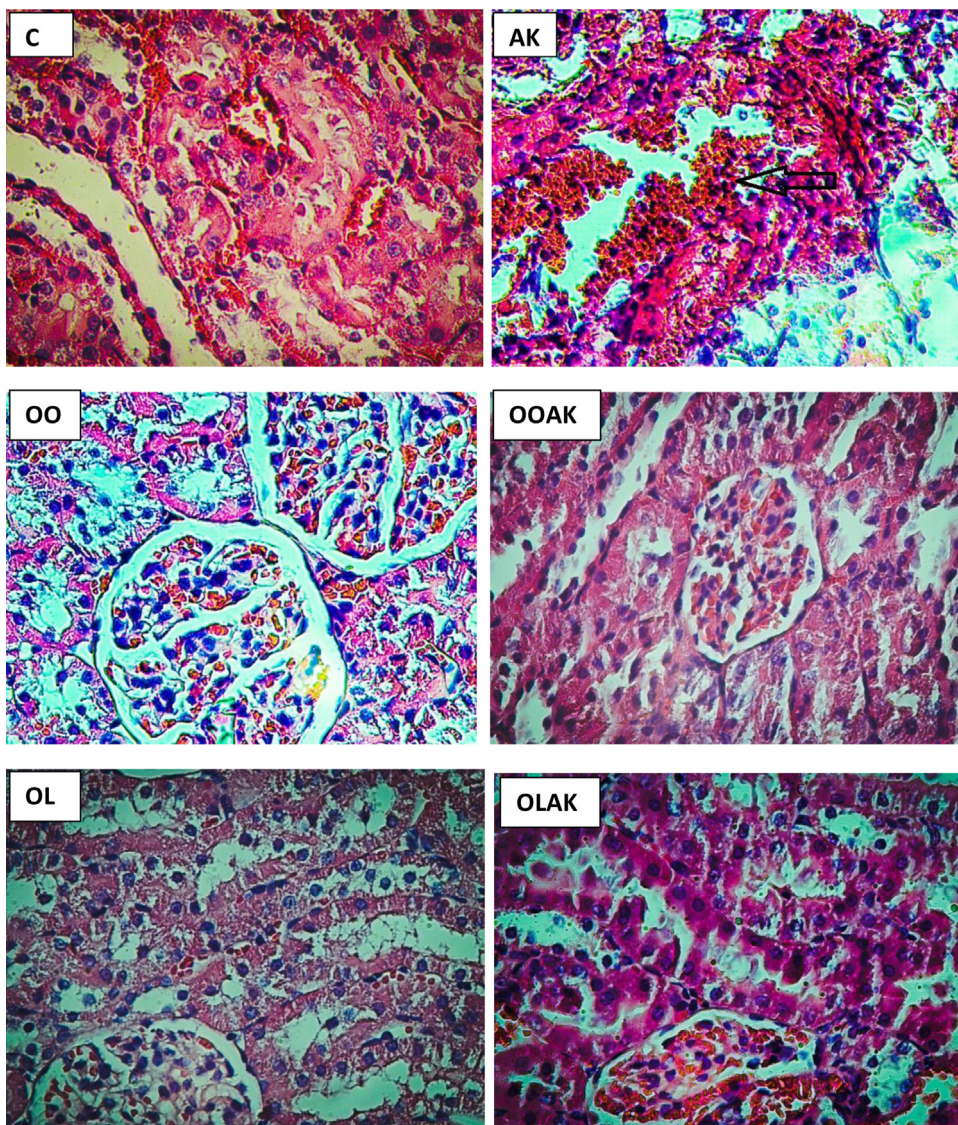


Fig. 1. The histopathology of kidney cortices of rats; (C) control, (AK) amikacin treated, (OO) olive oil-treated, (OOAK) co-treated with olive oil and amikacin, (OL) olive leaf extract treated and (OLAK) co-treated with olive leaf extract and amikacin groups. The slides were stained with hematoxylin and eosin. ($\times 40$ mm). The arrow indicates the extensive tubular necrosis in the AK group.

Table 2
The regression analysis of the estimated amikacin effect (as independent variable) and the kidney function parameters or serum lipids (as dependent variables).

	The dependent variable	R value	P value
1	Creatinine	0.484	0.0013
2	Urea	0.521	0.00047
3	Uric Acid	- 0.582	1.39×10^{-5}
4	TG	- 0.283	0.0511
5	Cholesterol	0.101	0.527

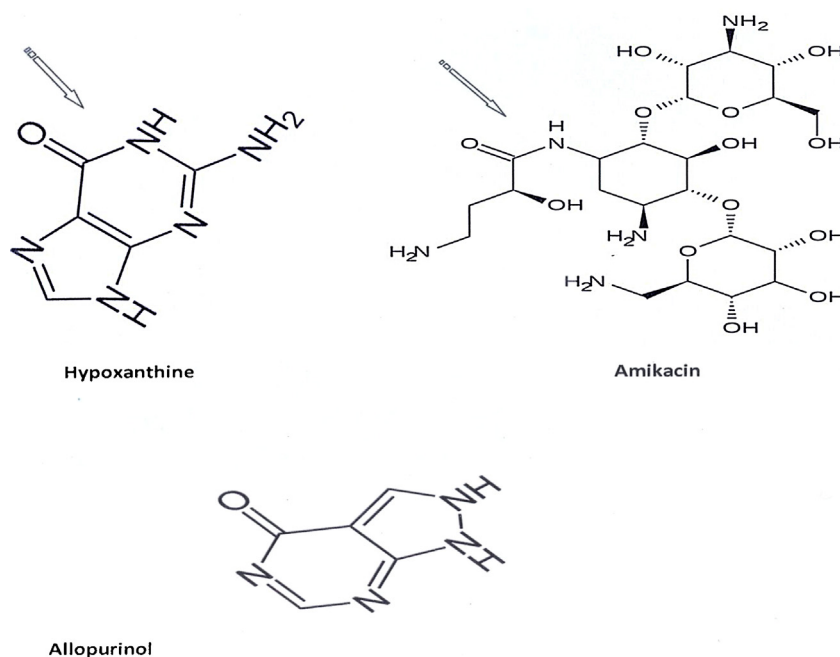


Fig. 2. Structures of hypoxanthine, the substrate of xanthine oxidase, allopurinol, competitive inhibitor for xanthine oxidase and amikacin drug. The arrow shows the domain with carbonyl and imino groups common in amikacin and in both substrate and the conventional enzyme inhibitor.

by the kidney [10]. The secondary hypertriglyceridemia was suggested to be due to reduction in the activity of lipoprotein lipase and hepatic lipase, the enzymes responsible for catabolism of the circulating triglyceride-rich VLDL particles [25]. In gentamicin and

cisplatin nephrotoxicity, the mechanism underlying their toxicity and dyslipidemia was related to the ability of these drugs and their metabolites to accumulate in the kidney cortex [23,26]. This may not be occurring with amikacin. However, further investigation is

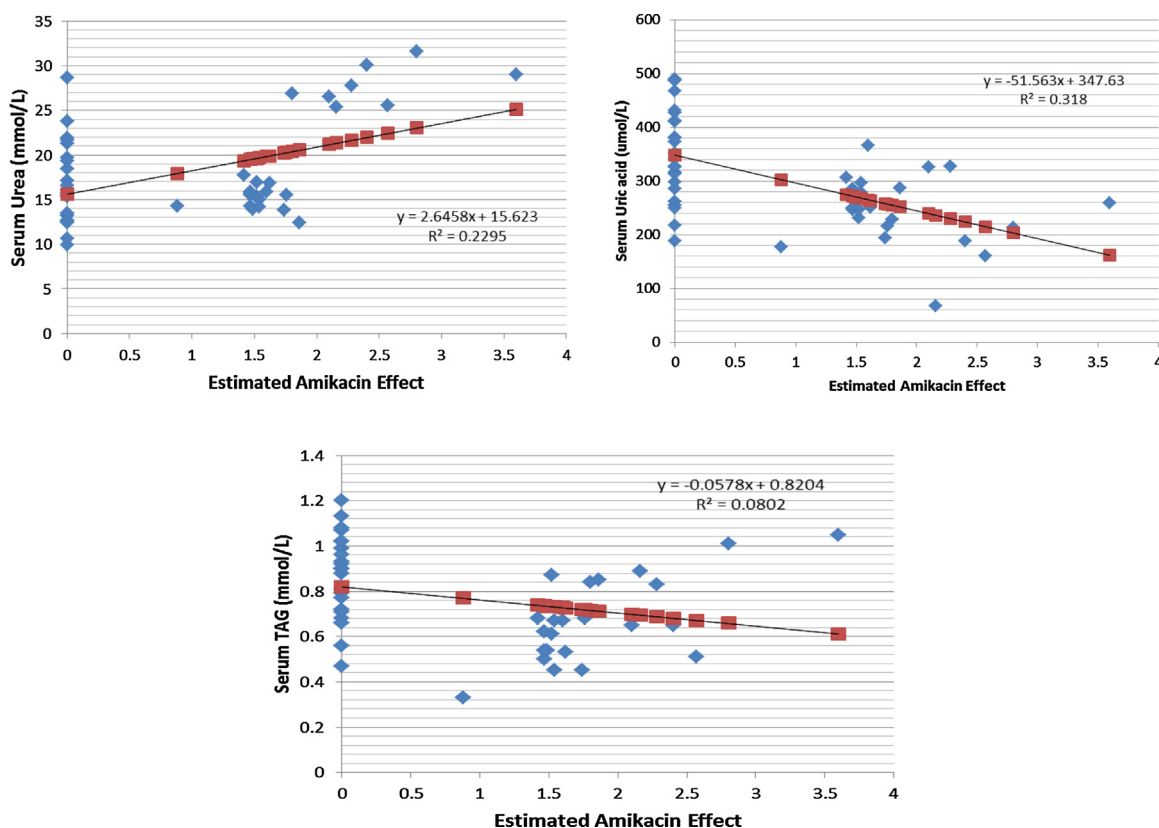


Fig. 3. The plots of regression analysis between the estimated amikacin effect (as independent variable) and the serum urea, uric acid and triglyceride (as dependent variables).

required to explain the exact cause of variation between amikacin and the other nephrotoxic drugs in their effects on lipid metabolism and regulation.

On the other hand, the olive leaf extract actively reduced the serum cholesterol and triglyceride levels. It was shown that the olive polyphenols can protect the LDL particles from oxidation [8]. Oxidized LDL is not recognized by the LDL-receptors thus not taken up by the cells leading to the elevation of circulating total cholesterol concentration. Moreover, the co-administration of both amikacin and olive oil or leaf extract did not alter the observed reduction in the serum triglyceride concentration. The fact that treatment with amikacin does not cause secondary dyslipidemia gives an advantage for amikacin as an antibiotic drug over the other aminoglycosides.

Another interesting finding in this study is the significant reduction of the serum uric acid levels in the animals treated with amikacin compared to the control. This was an unexpected observation since in kidney impairment the serum uric acid is elevated due to its delayed excretion. Uric acid is the excretory product of purine catabolism, and the final steps in uric acid biosynthesis involves the oxidation of hypoxanthine into xanthine then further oxidation of xanthine into uric acid. The reactions are catalyzed by xanthine oxidase, a metallo-enzyme that contains molybdenum and iron [12]. In treatment of hyperurecemia allopurinol is the drug of choice. Allopurinol structurally resembles hypoxanthine, thus it competitively inhibits the xanthine oxidase enzyme. Allopurinol is hydroxylated by xanthine oxidase at the 2-position to give oxipurinol which consequently binds the reduced molybdenum ion of the enzyme causing its inhibition [20]. Amikacin has an exposed domain with a carbonyl group and an imino group which resembles the hypoxanthine and allopurinol structure (Fig. 2). This makes it most appropriate to suggest that amikacin or some of its metabolites may impose an inhibitory effect on the enzyme responsible for the synthesis of uric acid. To validate this theory we calculated the correlation of the estimated amikacin effect (calculated as a ratio between the serum creatinine concentration and the units of drug given to the animal) and the serum uric acid. As indicated in Table 2 and Fig. 3, a significant positive correlation was shown with creatinine, whereas, a highly significant negative correlation was evident with the uric acid. Moreover, a significant negative correlation was also shown with the serum triglyceride, whereas, no correlation was shown with serum cholesterol. This supports the suggestion that amikacin has a strong depressing effect on the serum uric acid concentration, and to a lower extent the serum TG level. Thus our findings indicate that the drug beside its antibiotic activity may be a potent candidate for the management of hyperurecemia and gout.

5. Conclusion

The study confirmed that amikacin at a dose 300 mg/kg/d for 12 days induces nephrotoxicity in the rat. The drug toxicity was ameliorated by the virgin olive oil and ethanol extract of olive leaves. In contrast to gentamicin and cisplatin, the amikacin nephrotoxicity did not induce dyslipidemia. Amikacin treatment depressed the serum uric acid concentration, possibly by inhibition of the urate biosynthesis. Further studies are needed to elucidate the mechanism underlying the reducing effects of olive leaf extract on the serum triglyceride and cholesterol concentrations.

Acknowledgements

This study was funded by a grant from the University of Hail, Hail, Saudi Arabia.

Authors are grateful to Mr. Mohammad Ginawi for his assistance in animal care during the study and in preparation of kidney

slides for histopathology. Authors also extend their thanks to Prof. Hussain Jad-Kareem for his technical help in reading and histologic grading of the slides.

References

- [1] M.M. Abdel-Daim, E.W. Ghazy, Effects of *Nigella sativa* oil and ascorbic acid against oxytetracycline-induced hepato-renal toxicity in rabbits, *Iran. J. Basic Med. Sci.* 18 (2015) 221–227.
- [2] A.A. Abdel-Gayoum, K.B. El-Jenjan, K.A. Ghwarsha, Hyperlipidemia in cisplatin-induced nephrotic rats, *Hum. Exp. Toxicol.* 18 (1999) 454–459.
- [3] K.A. Abu-Septan, A.A. Abdel-Gayoum, Effect of high dietary cholesterol on gentamicin-induced nephrotoxicity in rabbits, *Arch. Toxicol.* 75 (2001) 284–290.
- [4] N. Al-Kharusi, H.A. Babiker, S. Al-Salam, A. Waly MI, A.I. Nemmar, I. Al-Lawati, et al., Ellagic acid protects against cisplatin-induced nephrotoxicity in rats: a dose-dependent study, *Eur. Rev. Med. Pharmacol. Sci.* 17 (2013) 299–310.
- [5] A.L. Al-Malki, S.S. Moselhy, The protective effect of epicatchin against oxidative stress and nephrotoxicity in rats induced by cyclosporine, *Hum. Exp. Toxicol.* 30 (2011) 145–151.
- [6] N.S. Al-Sowayan, H.M. Mousa, Ameliorative effect of olive leaf extract on carbon tetrachloride-induced nephrotoxicity in rats, *Life Sci. J.* 11 (2014) 238–242.
- [7] I. Celik, M. Cihangiroglu, N. Ilhan, N. Akpolat, H. Akbulut, Protective effects of different antioxidants and amrinone on vancomycin-induced nephrotoxicity, *Basic Clin. Pharmacol. Toxicol.* 97 (2005) 325–332.
- [8] M. Covas, K. Nyssönen, H.E. Poulsen, J. Kaikkonen, H.F. Zunft, H. Kiesewetter, et al., The effect of polyphenols in olive oil on heart disease risk factors: a randomized trial, *Ann. Intern. Med.* 145 (2006) 333–341.
- [9] N. Fakhraei, A.H. Abdolghaffari, B.M. Delfan, A. Abbasi, N. Rahimi, A. Khansari, et al., Protective effect of hydroalcoholic olive leaf extract on experimental model of colitis in rat: involvement of nitergic and opioidergic systems, *Phytother. Res.* 28 (2014) 1367–1373.
- [10] T.A. Golper, K.R. Feingold, M.H. Fuford, M.D. Siperstein, The role of circulating mevalonate in nephrotic hypercholesterolaemia in the rat, *J. Lipid Res.* 27 (1986) 1044–1051.
- [11] K. Hassanzadeh, K. Akhtari, H. Hassanzadeh, S.A. Zarei, N. Fakhraei, K. Hassanzadeh, The role of structural CH compared with phenolic OH sites on the antioxidant activity of oleuropein and its derivatives as a great non-flavonoid family of the olive components: a DFT study, *Food Chem.* 164 (2014) 251–258.
- [12] R. Hille, Molybdenum-containing hydroxylases, *Arch. Biochem. Biophys.* 433 (2005) 107–116.
- [13] D.C. Houghton, C.E. Plamp, D.N. Gilbert, S.J. Kohlhepp, W.M. Bennett, G.A. Porter, et al., Amikacin nephrotoxicity in the rat, *J. Environ. Pathol. Toxicol.* 4 (1980) 277–291.
- [14] H. Jemai, A. El Feki, S. Sayad, Antidiabetic and antioxidant effects of hydroxytyrosol and oleuropein from olive leaves in alloxan-diabetic rats, *J. Agric. Food Chem.* 57 (2009) 8798–8804.
- [15] K. Kaynar, S. Gul, S. Ersoz, F. Ozdemir, H. Ulusoy, S. Ulusoy, Amikacin-induced nephropathy: is there any protective way? *Ren. Fail.* 29 (2007) 23–27.
- [16] K. Kiritsakis, M.G. Kontominas, C. Kontogiorgis, D. Hadjipavlou-Litina, A. Moustakas, A. Kiritsakis, Composition and antioxidant activity of olive leaf extracts from Greek olive cultivars, *J. Am. Oil Chem. Soc.* 87 (2010) 369–376.
- [17] D.P. Koirala, K.S. Rao, K.K. Malla, T. Malla, A study of clinical features: management and outcome of organophosphate and carbamate poisoning in children, *J. Nepal Paediatr. Soc.* 33 (2013) 85–90.
- [18] S. Li, C. Cao, H. Shi, S. Yang, L. Qi, X. Zhao, C. Sun, Effect of quercetin against mixture of four organophosphate pesticides induced nephrotoxicity in rats, *Xenobiotica* 30 (2015) 1–9.
- [19] F.C. Mazali, R.J. Johnson, M. Mazzali, Use of uric acid-lowering agents limits experimental cyclosporine nephropathy, *Nephron. Exp. Nephrol.* 120 (2012) e12–e19.
- [20] K. Okamoto, B.T. Eger, T. Nishino, E.F. Pai, T. Nishino, Mechanism of inhibition of xanthine oxidoreductase by allopurinol: crystal structure of reduced bovine milk xanthine oxidoreductase bound with oxipurinol, *Nucleosides Nucleotides Nucleic Acids* 27 (2008) 888–893.
- [21] H. Parlakpinar, M.K. Ozer, M. Ucar, M. Gaffaroglu, N. Vardi, M. Koc, et al., Protective effects of caffeic acid phenethyl ester (CAPE) on amikacin-induced nephrotoxicity in rats, *Cell Biochem. Funct.* 24 (2006) 363–367.
- [22] H. Parlakpinar, M.K. Ozer, E. Sahna, N. Vardi, Y. Cigremis, A. Acet, Amikacin-induced acute renal injury in rats: protective role of melatonin, *J. Pineal Res.* 35 (2003) 85–90.
- [23] Y. Quiros, L. vicente-vicente, A.I. Morales, J.M. López-Novoa, F.J. López-Hernández, An integrative overview on the mechanisms underlying the renal tubular cytotoxicity of gentamicin, *Toxicol. Sci.* 119 (2011) 245–256.
- [24] F. Rashid, M. Kaleem, Sheema, B. Bano, Comparative effect of olive oil and fish oil supplementation in combating gentamicin induced nephrotoxicity in rats, *Indian J. Clin. Biochem.* 20 (2005) 109–114.
- [25] J.M. Saland, H.N. Ginsberg, Lipoprotein metabolism in chronic renal insufficiency, *Pediatr. Nephrol.* 22 (2007) 1095–1112.
- [26] M.H. Solanki, P.K. Chatterjee, M. Gupta, X. Xue, A. Plagov, M.H. Metz, et al., Magnesium protects against cisplatin-induced acute kidney injury by

- regulating platinum accumulation, *Am. J. Physiol. Renal. Physiol.* 15 (307) (2014) F369–F384.
- [27] M.H. Sulaiman, A.A. Abdel-Gayoum, M. Al-Fakhri, Effect of spironolactone on cisplatin-induced nephrotoxicity in rabbits, *Hum. Exp. Toxicol.* 20 (2001) 453–459.
- [28] W.M. Sweileh, A prospective comparative study of gentamicin- and amikacin-induced nephrotoxicity in patients with normal baseline renal function, *Fundam. Clin. Pharmacol.* 23 (2009) 515–520.
- [29] S.S. Taber, D.A. Pasko, The epidemiology of drug-induced disorders: the kidney, *Expert Opin. Drug Saf.* 7 (2008) 679–690.
- [30] M. Tavafi, H. Ahmad, P. Toolabi, Inhibitory effect of olive leaf extract on gentamicin-induced nephrotoxicity in rats, *Iran. J. Kidney Dis.* 6 (2012) 25–32.
- [31] S. Ulusoy, G. Ozkan, S. Ersoz, A. Orem, M. Alkanat, F.B. Yucesan, et al., The effect of grape seed proanthocyanidin extract in preventing amikacin-induced nephropathy, *Ren. Fail.* 34 (2012) 227–234.