



The University of Bradford Institutional Repository

<http://bradscholars.brad.ac.uk>

This work is made available online in accordance with publisher policies. Please refer to the repository record for this item and our Policy Document available from the repository home page for further information.

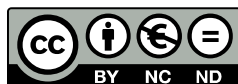To see the final version of this work please visit the publisher's website. Access to the published online version may require a subscription.

Link to original published version: <http://dx.doi.org/10.1016/j.jtv.2016.03.002>

Citation: Tobin DJ (2017) Introduction to skin aging. *Journal of tissue viability*. 26(1): 37-46.

Copyright statement: © 2017 Tissue Viability Society. Full-text reproduced in accordance with the publisher's self-archiving policy.

This manuscript version is made available under the CC-BY-NC-ND 4.0 license
<http://creativecommons.org/licenses/by-nc-nd/4.0/>



Accepted Manuscript

Introduction to SKIN aging

Desmond J. Tobin, BSc., PhD

PII: S0965-206X(16)00028-0

DOI: [10.1016/j.jtv.2016.03.002](https://doi.org/10.1016/j.jtv.2016.03.002)

Reference: JTV 197


To appear in: *Journal of Tissue Viability*

Received Date: 18 November 2015

Accepted Date: 3 March 2016

Please cite this article as: Tobin DJ, Introduction to SKIN aging, *Journal of Tissue Viability* (2016), doi: 10.1016/j.jtv.2016.03.002.

This is a PDF file of an unedited manuscript that has been accepted for publication. As a service to our customers we are providing this early version of the manuscript. The manuscript will undergo copyediting, typesetting, and review of the resulting proof before it is published in its final form. Please note that during the production process errors may be discovered which could affect the content, and all legal disclaimers that apply to the journal pertain.



INTRODUCTION TO SKIN AGING

Desmond J Tobin BSc., PhD

**Centre for Skin Sciences, Faculty of Life Sciences,
University of Bradford, Bradford West Yorkshire BD7 1DP,**

Great Britain

Tel: 01274 233585

d.tobin@bradford.ac.uk

ACCEPTED MANUSCRIPT

ABSTRACT

Cutaneous science has seen considerable development in the last 25 years, in part due to the -Omics revolution, and the appreciation that this organ is hardwired into the body's key neuro-immuno-endocrine axes. Moreover, there is greater appreciation of how stratification of skin disorders will permit more targeted and more effective treatments. Against this has been how the remarkable extension in the average human life-span, though in the West at least, this parallels worrying increases in lifestyle-associated conditions like diabetes, skin cancer etc. These demographic trends bring greater urgency to finding clinical solutions for numerous age-related deficits in skin function caused by extrinsic and intrinsic factors. Mechanisms for aging skin include the actions of reactive oxygen species (ROS), mtDNA mutations, and telomere shortening, as well as hormonal changes.

We have also significantly improved our understanding of how to harness the skin's considerable regenerative capacity e.g., via its remarkable investment of stem cell subpopulations. In this way we hope to develop new strategies to selectively target the skin's capacity to undergo optimal wound repair and regeneration. Here, the unsung hero of the skin regenerative power may be the humble hair follicle, replete with its compliment of epithelial, mesenchymal, neural and other stem cells. This review introduces the topic of human skin aging, with a focus on how maintenance of function in this complex multi-cell type organ is key for retaining quality of life into old age.

INTRODUCTION TO SKIN AGING

INTRODUCTION

Skin, our largest organ by weight and extent, can be viewed as a sensor of the body's periphery, a veritable 'brain on the outside'¹. While the question of 'what is the function of skin' is a daunting one, the best single discussion on the function of skin can, in my view, be found in the multi-author discussion review 'What is the 'true' function of skin?'² The skin organ is truly a biologic universe, as it incorporates all the body's major support systems; of blood, innervation, muscle, as well as its immuno-competence, psycho-emotion reactivity, ultraviolet radiation sensing, endocrine functions etc. Together, these participate in the homeostasis of skin and its appendages, and in this way are important for the homeostasis of the entire mammalian body. While not always the case, this view now appears self-evident, given that the skin occupies such a strategic location between the noxious external and biochemically-active internal environments. For all its perfection, in terms of evolutionary adaptation to life on an ultraviolet radiation (UVR)-drenched terrestrial planet, skin conditions still rank 4th in the leading causes of nonfatal disease burden³. This burden is likely to rise further as we age⁴ given our lifestyle choices of inactivity, sugar, tobacco, alcohol etc.

Recent insights into the skin's remarkable stress-sensing capacity, much of which is communicated via the skin's equivalent of the hypothalamic-pituitary-adrenal (and thyroid) axis, allow us to assess how age may affect these key axes. Perhaps counterintuitive, it is important to note upfront that well-nourished and UVR-protected skin exhibits truly remarkable resilience to chronological (or intrinsic) aging, and much if not most of what we refer to skin aging is due to the structural changes to the skin that are a consequence of so-called extrinsic aging (e.g., UVR, trauma, chemicals etc.).

The harbingers of our lost youth can be most readily seen in our skin as we age; including skin wrinkling (rides), hair graying (canities) and for most men and some women the tendency for scalp hair thinning/baldness. These changes may confer only small losses in function, but as our expectations for the extension of optimal functioning continue to grow well into our 70s, 80s and beyond, these changes are unwelcome. This is perhaps reasonable, as life expectancy in western countries is expected to be 100 years in the next decade.⁵ The implications of this unprecedented change for human history will be greatest for women, as they will soon spend as much as 50% of their lives post-menopause, where low estrogen levels will adversely affect skin function. The market is responding by developing sophisticated cosmetic/cosmoseuticals, pharmaceuticals and surgeries to provide options to assuage not only our vanity but also to aid our increasingly dry/itchy,⁶ infection-prone,⁷ vascular, immune-unstable⁸ skin.

Given its strategic location at the body's interface, the skin is subjected to *intrinsic* (chronologic) aging that are generally under genetic and hormonal influence and *extrinsic* aging caused by environmental factors, principally UV radiation (UVR), smoking, diet, chemicals, trauma etc. UVR effects on skin are so powerful that these are designated separately as *photo-aging*. Both types of aging have their distinct and overlapping features.⁹ Importantly, skin aging traits (e.g., perceived age, pigmented age spots, skin wrinkles and sun-damage) appear to be equally influenced by genetic and environmental factors^{10,11}.

INTRINSIC AGING

Intrinsic aging of skin is imperceptibly slow moving, and shows significant variation between populations, individuals of the same ethnicity, and different sites on the same person. Essentially intrinsic skin aging can only be seen in quite old age and is characterized by unblemished, smooth, pale(r), drier, less elastic skin with fine wrinkles^{12,13}. Additional subcutaneous changes in the face also lead to somewhat exaggerated expression lines. Intrinsic aging occurs within the tissue itself, via reductions in dermal mast cells, fibroblasts, collagen production, flattening of dermal-epidermal junction/loss of rete ridges, as well as being caused by how aging in other organs affect the skin. From a form-function perspective, the flattening of the previously undulating epidermis

is a most striking change caused by a loss of the rete ridges and their reciprocal inter-digitation with capillary-rich dermal papillae. A likely consequence of this is reduced nutrient support to the avascular epidermis by the vascularized dermis. From a mechanistic point of view, intrinsically-aged epidermis is also controlled by progressive telomere shortening, exacerbated by low-grade oxidative damage to telomeres and other cellular constituents.^{14,15}

EXTRINSIC AGING

While interventions for intrinsic aging are difficult, except perhaps via hormone supplementation etc., the prevention and treatment of extrinsic aging-associated changes to skin structure and appearance is the subject of much attention. However, the impact of extrinsic-aging drivers cannot be completely separated from how skin responds to chronologic aging. Exogenous factors will impact skin physiology permanently (e.g., pro-oxidant and antioxidant influences on cell turnover via neuro-endocrine-immune biological response modifiers). By far the greatest source of extrinsic aging is accumulated and unprotected sun exposure (i.e., photo-aging). This is largely confined to the face, neck, hands, and less so lower arms and legs. Over 80% of facial skin aging is due to low-grade chronic UVR exposure, although exposure can also cause sunburn, tanning, inflammation, immunosuppression, and damage to dermal connective tissue.^{16,17} The characteristics of extrinsically-aged skin (mostly UVR-induced) include coarse wrinkling, rough texture, sallow complexion with mottled pigmentation, and loss of skin elasticity.

Photo-aging is caused by sunlight, which at the earth's surface consists mostly of infrared (52-55%), visible (44%) and 3% UV light. The vast majority of the sun's UVR (400-10 nm) is blocked by the earth's atmosphere such that UVR reaching our planet's surface consists of >95% UVA (400-315 nm) and ~5% UVB (315-280 nm). UVC (280-100 nm), which is extremely hazardous to skin, is completely absorbed by the ozone layer and atmosphere. The ratio of UVA to UVB reaching our skin depends on latitude, season and time and in the real-world is 25. Alas, most studies have used solar-simulated radiation with a UVA:UVB ratio of <18 as a proxy for noon summer sun on a clear day¹⁸.

Deeply-penetrating UVA damages connective tissue in the dermis and also increases risk for skin cancer, while UVB penetrates only as far as the epidermis where it can cause sunburn, tanning, and photocarcinogenesis.¹⁹ UVB is the major cause for direct DNA damage and induces inflammation and immunosuppression²⁰, while UVA may have a greater role in skin photo-aging, given its greater amount in sunlight and the fact that both dermis and epidermis are irradiated.²⁰ First signs of extrinsic aging (on exposed sites) can be seen as early as 15 years of age in pale-skinned Caucasians²¹, whereas changes to non-exposed sites are not apparent until age 30 years.²² The high priority in Western culture of a golden tan²³ is associated alas, with ever-rising rates of skin cancer and prematurely-aged skin. Photo-aged skin is characterized by deep wrinkles, laxity, roughness, a sallow or yellow color, increased fragility, purpura formation, mottled pigmentary changes, telangiectasia, impaired wound healing, and benign and malignant growths. The degree of accumulated sun exposure determines the magnitude of these changes. Mechanisms of UVR-induced and accelerated aging are discussed later in this review. The second most important driver of extrinsic aging is cigarette smoking²⁴⁻²⁸.

Skin type

The level of eumelanin in skin helps protect against the cumulative effects of photo-aging. Typically, skin phototype is described using the Fitzpatrick classification I-VI (ranging from 'always burn never tan' to 'always tan and never burns'). When phototypes were compared it was found that skin of type VI individuals (i.e., black) shows little difference between exposed and unexposed sites.²⁹ Moreover, the much higher rates of skin cancer among Caucasians compared with black African-Americans reflects the significant protection from UVR damage that eumelanin provides (up to 500-fold level).³⁰ Furthermore, the appearance of photo-damaged skin

differs for those with skin types I and II (red hair/freckles/burns easily) and those with skin types III and IV (darker skin, tans easily), whereby the former tend to show atrophic skin changes, but with fewer wrinkles, and focal depigmentation (guttate hypomelanosis) and dysplastic changes, such as actinic keratoses and epidermal malignancies. In contrast, those with III/IV skin develop hypertrophic responses, such as deep wrinkling, coarseness, a leather-like appearance, and lentigines.²⁰ Basal cell and squamous cell carcinomas occur almost exclusively on sun-exposed skin of light-skinned people.

Skin has been reported to increase in thickness in chronologic and photo-aging. However, while both increases and decreases in skin thickness can be seen in different body sites, there was no general relationship between skin thickness and with age.^{30, 31} Thus, it appears that the epidermis thins with age at some body sites, such as the upper inner arm^{32,33} and back of the upper arm,³⁴ but remains constant at others, such as the buttock, dorsal forearm, and shoulder³⁵ - a variation not explained by sun or environmental exposure alone.³⁰ Although epidermal thickness appears to remain largely constant with advancing age, there is some variability in keratinocyte shape and size with age, specifically that these cells become shorter and flatter in contrast to an increase in corneocyte size potentially as a result of decreased epidermal cell turnover with age.¹³ Wrinkling in Asian skin has been documented to occur later and with less severity than in white Caucasians.²²

EPIDERMIS

The epidermis is composed of an outer nonviable layer called the stratum corneum, with more proximal layers making up the viable epidermis consisting primarily of keratinocytes (90-95% of cells). Smaller populations of Langerhans cells (2%), melanocytes (3%) and Merkel cells (0.5%) can also be found in the epidermis.¹

The stratum corneum provides the body's main barrier to the environment, and is key to maintaining optimal cutaneous hydration³⁶. Simplistically, its structure has been described by a "bricks and mortar" model with protein-rich corneocytes (bricks) embedded in a matrix (mortar) of ceramides, cholesterol, and fatty acids.³⁰ It is generally agreed that the thickness of the stratum corneum does not change significantly with age³⁷. However, certain features of aging skin do indicate an abnormal skin barrier, namely the extreme skin dryness (xerosis) and increased susceptibility to irritant dermatitis. There is also evidence of altered permeability to chemical substances³⁸ and reduced trans-epidermal water flux in aged skin.³⁰ Despite these, the baseline skin barrier function is relatively unaffected by age,³⁷ and substances recoverable from the skin surface (sebum, sweat, components of natural moisturizing factor, and corneocyte debris) were neither affected by age nor by ethnicity and gender.³⁹

The barrier function in aged skin (>80 years) is more readily disrupted by sequential tape stripping than is young skin (20 to 30 years), as was barrier recovery.³⁷ It appears that there is a global reduction in stratum corneum lipids, which may affect the "mortar" that binds the corneocytes together. In moderately aged (50 to 80 years) individuals, abnormal stratum corneum acidification results in delayed lipid processing, delayed permeability barrier recovery, and abnormal stratum corneum integrity, ion transport and turnover.⁴⁰⁻⁴³

Flattening of the dermo-epidermal junction at sites that were highly corrugated in youth is the most consistent change found in aged skin⁴⁴ and is due primarily to a retraction of the rete ridges.³⁰ This reduced interdigitation between epidermis and dermis results in less resistance to shearing forces^{13,22} as well as a reduced supply of nutrients and oxygen.⁸ This effect is likely to be influenced by solar elastosis changes in the papillary dermis (see below).⁴⁵ Even with minimal photo-aging one can appreciate loss of fibrillin-rich microfibrils in the dermal-epidermal junction - an early marker of photoaging.^{46,47,48} There is general agreement that epidermal cell turnover halves between the third and seventh decades of life,^{49,50} and this concurs with the observed deterioration in wound healing capacity in old age.⁵¹

Keratinocytes

Keratinocytes in the basal layer of the epidermis exhibit increasing atypia with age.³³ In addition, basal keratinocytes downregulate expression of some β_1 -integrins,⁵² suggesting that proliferation and adhesion of keratinocytes in photo-damaged aged skin are abnormal.

Melanocytes

The number of functional (i.e. tyrosinase-positive/active) melanocytes decline by up to 20% per decade in the basal layer of the human epidermis,⁵³ although paradoxically there is often an increase in melanocyte number in photo-damaged skin.⁵⁴ This is further reflected by a reduction in melanocytic nevi in old age.⁵⁵ Less melanocytes is associated with melanin production, which means less protection against the harmful effects of UVR.⁵⁶

There are also changes to melanocyte function in the aging/graying hair follicle (see below).⁵⁷ Aged skin of most ethnicities show an increase in solar lentigo lesions (age spots), and these contribute more to perceived age than wrinkling for those of mongoloid Asian ethnicity. Age spots exhibit major histological changes to the basal layer of the epidermis, especially the elongation of epidermal rete ridges (note epidermal flattening seen in general skin aging). The number of tyrosinase-positive melanocytes per length of dermal/epidermal interface may increase in the spot versus the unaffected skin.⁵ though other studies only report increased melanocyte size, dendrite elongation and alterations in melanosomes and their organization. Endothelin-1 and stem cell factor may be key regulators of hyperpigmentation in solar lentigo.⁵⁹

DERMIS

The dermis consists predominantly of connective tissue (e.g., collagen and elastin), but also contains appendages including sweat glands and pilosebaceous units as well as blood vessels, and nerves. Its main role is to provide a tough and flexible layer that supports the epidermis and binds to the subcutis, the fatty layer deep to the dermis. Collagen fibers give the skin its tensile strength, whereas elastin fibers contribute to elasticity and resilience.⁶⁰ Although aging changes in elderly dermis with severe damage may exhibit thinning,⁶¹ it remains difficult to define the effects of aging on skin thickness due to considerable inter-individual and inter-body site variations and because of differences in methodology between different studies.³⁰ While the mechanism of wrinkle formation is not entirely understood,⁴⁴ there is general atrophy of the extracellular matrix, accompanied by fewer fibroblasts, and with reduced synthetic ability.^{62,63} Photo-aged skin exhibit histological features of chronic inflammation without significant evidence of clinical or molecular abnormalities.⁶⁴⁻⁶⁶

Collagen is the body's most abundant protein. As the principle structural component of the dermis it confers strength and support to human skin. Alterations in collagen play an integral role in the skin aging process.⁵⁶ Dermal collagen bundles are well-organized in young adults, where they are arranged to facilitate an extension that returns to resting state via interwoven elastic fibers.⁴⁴ In aging skin however, there is an increase in density of collagen bundles⁶⁷ but they lose their extensible configuration, instead becoming fragmented, disorganized, and less soluble.^{65,68} Collagen-degrading enzymes (e.g., matrix metalloproteinases (MMPs)) are upregulated during both photoaging and intrinsic aging, mainly via the production of reactive oxygen species (ROS).⁶⁹ Collagen synthesis decreases⁷⁰ resulting in a shift in the balance between synthesis and degradation.^{8,13} Specifically, in young skin collagen I comprises 80% of dermal collagen and type III makes up 15%. However, with age there is a decrease in collagen I with a resultant increase in the ratio of type III to type I collagen.^{68,71} There are also changes to levels of collagen IV and VII. Importantly, collagen IV, which is an integral part of the dermo-epidermal junction, provides a structural framework for other molecules and plays a key role in maintaining mechanical stability.⁵⁹ Lower levels of collagen IV and collagen VII exist at the base of wrinkles, suggesting these collagens contribute to wrinkle formation.⁷²

Human skin is uniquely rich in elastic fibers with regional variation in their density. Elastin exhibits numerous age-related changes, and UVR triggers remodeling/degradation of elastic fibers mostly regulated by MMPs^{73,75} and abnormal localization of elastin in the upper dermis of photo-damaged skin.³⁰ Solar elastosis is, histologically, a most striking features of photo-damaged skin and represents a tangled mass of degraded elastic fibers, disorganized tropoelastin and fibrillin located in the upper dermis including adjacent to the dermis-epidermis junction.²⁰ Most elastin fibers appear abnormal over 70 years of age, including in sun-protected sites^{66,76} This abnormal elastotic material confers no elasticity nor resilience to skin. While recovery from mechanical depression takes only minutes in young skin, this can extend to >24hrs in the elderly.

Counterintuitively, the level of glycosaminoglycans (GAGs) increases in photo-aged skin^{77,78} but while young skin is well-hydrated (as most of the water is bound to proteins^{79,80} there is a shift toward 'tetrahedron water' in aged skin. This has poor hydration and turgor capacity and contributes to the dry (xerotic) appearance of photo-aged skin.³⁰ There is an overall reduction in subcutaneous fat volume in aged skin, despite the fact that total body fat (e.g., thighs, waist, abdomen) can continue to increase until around 70 years of age. Greatest fat loss is seen in the face, feet and hands.^{80,55}

Nerves and sensation

Skin enervation is little affected by aging, though some studies report a decrease in sensory perception and an increase in pain threshold with age.^{81,82} There is some loss of nerve support in bald scalp, but this is likely driven by hair follicle miniaturization than by skin aging per se.⁸²

Dermal vasculature

Skin aging may be associated with decreased cutaneous perfusion, especially in photo-exposed areas.^{30,83} This reduction in vascularity is especially detectable in superficial papillary dermis, where there is loss of the vertical capillary loops previously associated with the now absent rete ridges. Reduced vascularity results in skin pallor, depleted nutrient exchange, and disturbed thermoregulation.^{56,30} Dermal vessels in severely photo-damaged skin show thin and dilated walls, presenting as telangiectasia.²⁰

SKIN APPENDAGES

Eccrine and Apocrine sweat glands

The reduction in eccrine sweat glands⁸⁴ and their output⁸⁵ in skin with increasing age impacts whole body thermoregulation. While the response to epinephrine is reduced in men and women in old age, there is a greater decrease in response to acetylcholine in men than in women.^{85,86} Apocrine gland activity is also diminished with age, probably as a consequence of declining testosterone levels with consequent reduction in body odor.⁸⁷

Nails

Nail growth increases until about the age of 25 years, thereafter it starts to decrease.⁴⁴ Until the age of 70, nail growth is greater in men than women, after which the situation appears to be reversed.⁸⁸ Nails become more brittle in the elderly and develop beaded ridging due to a reduction in lipophilic sterols and free fatty acids.⁸⁹

Pilo-sebaceous Unit

The pilo-sebaceous unit, including both the hair follicle as its associated sebaceous glands, exhibits perhaps the most profound age-associated changes. During puberty there is a striking transformation of low sebum-secreting, fine and near-invisible vellus fibers to high sebum-secreting pigmented, coarse terminal hairs. Paradoxically, there may be a miniaturization of hair follicles during age-related male pattern alopecia. These anatomic changes in the hair follicle (enlargement and miniaturization) results in a significant remodeling of the dermis in the adjacent interfollicular skin, as highlighted by the significant reduction in subcutaneous fat layer of bald scalp increased the likelihood of cuts and bruising in this area.⁹⁰ While age does not significantly alter the absolute number of pilo-sebaceous units per unit area on the scalp, their sebaceous glands may become hyperplastic and larger.⁹¹ Despite this increase in size, there is a 50% reduction in sebum production,⁹² suggesting reduction in holocrine sebocyte turnover, which contributes to xerosis of aged skin. This may be due to decreased levels of testosterone.⁹³ Sebum secretion and type is also significantly reduced in post-menopausal women, suggesting these glands are also estrogen sensitive.⁹⁴

Hair

Powerful evolutionary selection ensures that the hair follicle is, in the main, hardwired against significant aging-related loss of function, even after 12 or more decades of life.⁹⁰ Processes underlying aging in general, e.g., oxidative damage, telomere shortening, age-related deficiencies related to nuclear/mitochondrial DNA damage and repair as well as age-related reductions in the cells' energy supply, will all impact on whether some follicular cell subpopulations will enter cellular senescence. Chest, axillary, and pubic hair all decrease in density with age; however, in men there is often increased hair growth vigor in other body site like the eyebrows, around the external auditory meati, and in nostrils, and this may reflect the maintenance of high testosterone levels in males into the 70s.⁴⁴ In elderly women there is a similar conversion of vellus to coarse terminal hairs on the chin and moustache, which is thought to reflect an unmasking of testosterone's influence in the context of now diminished estrogen balance.

Aside from intrinsic aging, a principal influence on hair with age is androgenetic alopecia. This is a distinct entity from the more aging-related hair thinning recently described as 'senescent' alopecia⁹⁵ as androgenetic alopecia (or common male pattern baldness) can manifest very early on, even in the late teenage years. Microarray analysis has now shown that androgenetic and senescent alopecia differ significantly in gene expression, such that these two types of age-related alopecia show two distinct profiles. While the former is the result of dihydro-testosterone action on so-called androgen-sensitive hair follicles⁹⁶, senescent alopecia may not accurately represent true aging effects on the hair follicle. By contrast, so-called female patterned alopecia may be truly 'androgenetic' for only a small number of women with thinning hair, and so other age-associated alopecias in women are likely to have other causes.⁹⁷ Regardless of cause, age-related alopecia affects at least 50% of men by the age of 50 years and 50% of women by the age of 60 years.⁹⁸

White hair was thicker on average, showed more medulla^{99,100} and grew faster than pigmented hair. Interestingly, these researchers have also described an age-related reduction in hair growth rate, but that this was broadly limited to pigmented hairs. Thus, the implication is that, counter-intuitively, the apparently more 'aged' white hairs may be partially spared these aging changes. The tensile strength of hair also decreases with age, having increased from birth to the second decade. Changes in hair color and density are very visible indicators of age and are the target of endless manipulation to maintain a youthful appearance. Hair graying appears to be a consequence of an overall and specific depletion of hair bulb melanocytes, and less so in the outer root sheath and sebaceous gland basal layer.¹⁰¹⁻¹⁰³ The mechanism for this steady depletion remains uncertain, but appears to involve the stability and survival of melanocyte stem cells and bulbar melanocytes, especially in the context of their relative sensitivity to an increasingly friable oxidant/anti-oxidant protection status.^{104,105}

Immune function

The skin (excluding an immune-privileged transient portion of anagen hair follicles) is a potent immune-competent tissue. The density of antigen-presenting Langerhans cells in the skin decreases greatly in the elderly even in sun-protected sites.^{106,107} These cells also have reduced ability to migrate from the epidermis in response to cytokines like tumor necrosis factor- α .¹⁰⁸ Similarly, T lymphocytes are reduced in number and become less responsive to specific antigens.^{42,109} Aging skin also appears to have a reduced ability to produce certain cytokines (e.g., interleukin-2,¹¹⁰), while the production of others (e.g., interleukin-4) is increased.¹¹⁰ The consequence of these changes is a reduced intensity to delayed hypersensitivity reactions⁸ and increased susceptibility to photo-carcinogenesis and chronic skin infections.⁴⁹

Women

Reduced estrogen levels in post-menopausal women contributes to wrinkling, dryness, atrophy, laxity, poor wound healing, and vulvar atrophy,¹¹¹ and loss of collagen appears to be more closely related to post-menopausal age than chronologic age.^{112,113} Estrogen therapy (HRT) may prevent collagen loss and can stimulate synthesis of collagen in those that have lower initial collagen levels.^{114,115} There is also a relationship between estrogen deprivation and degenerative changes of dermal elastic tissue.^{116,117} There is some evidence

that HRT improves skin dryness¹¹⁸ and wound healing,¹¹⁹ and increases skin surface lipids.^{120,12,122}

Mechanism

There are several proposed modes of aging in terms of their cellular and molecular biologic mechanism(s), although it is not at all clear whether they adequately address the primary cause(s) of aging. The production of reactive oxygen species (ROS) or free radicals, through UVR, smoking, pollution, and normal endogenous metabolic processes, is thought to contribute to the process of aging in the skin. ROS induces gene expression pathways result in increased degradation of collagen and accumulation of elastin.¹²³ ROS not only directly destroys interstitial collagen, but also inactivates tissue inhibitors of matrix-metalloproteases and induces the synthesis and activation of matrix degrading metalloproteases.¹²³ Hormones have also been shown to play a role as post-menopausal hormone changes are responsible for a rapid worsening of skin structure and functions, and these can be at least partially repaired by HRT or local estrogen treatment.^{113,124}

Mitochondrial DNA incurs regular DNA damage due to repeated constitutional oxidative stress, and in particular deletion of a specific length of DNA called common deletion that is 10 times more common in photo-damaged than in sun-protected skin. The deletion results in further accumulation of ROS, with additional damage to the cell's ability to generate energy. The extent of mtDNA damage in photo-damaged skin does not correlate with the chronologic age however, but rather with photo-damage severity.²⁰ UVR can also accelerate telomere shortening, and results in the activation of DNA damage response proteins such as p53, a tumor suppressor protein. The latter can inducing proliferative senescence or apoptosis, depending on the cell type.^{14,125}

CONCLUSION

Skin is subject to a complex blend of intrinsic and extrinsic aging processes and given its strategic location as an interface organ is particularly vulnerable to environmental insults (e.g., UVR). Although there are numerous defense mechanisms to protect the skin from damage, the efficacy of these diminishes over time, resulting in the clinical features associated with aging and the development of skin cancers.

References

1. Tobin DJ. Biochemistry of human skin--our brain on the outside. *Chem Soc Rev* 2006;35(1):52-67.
2. Chuong CM et al, What is the 'true' function of skin? *Exp Dermatol*. 2002;11(2):159-87.
3. Hay RJ et al. The Global Burden of Skin Disease in 2010: An Analysis of the Prevalence and Impact of Skin Conditions. *J Invest Dermatol* 2014;134:1527-1534.
4. Kligman AM, Koblenzer C. Demographics and psychological implications for the aging population. *Dermatol Clin* 1997;15:549-553.
5. Christensen K et al et al. Aging populations: the challenges ahead. *Lancet* 2009; 374:1196-1208.
6. Harvell JD, Maibach HI. Percutaneous absorption and inflammation in aged skin: a review. *J Am Acad Dermatol* 1994;31:1015-1021.
7. Plowden J et al. Innate immunity in aging: impact on macrophage function. *Aging Cell* 2004;3:161-167.
8. Waldorf DS et al. Impaired delayed hypersensitivity in an aging population. Association with antinuclear reactivity and rheumatoid factor. *JAMA* 1968;203:831-834.
9. Oikarinen A. The aging of skin: chronoaging versus photoaging. *Photodermatol Photoimmunol Photomed* 1990;7:3-4.
10. Gunn DA et al. Why some women look young for their age. *PLoS One* 2009;1:4(12):e8021
11. Parsons PA. The limit to human longevity: an approach through a stress theory of aging. *Mech Ageing Dev* 1996;87(3):211-8.

12. Montagna W et al. Histology of sun-damaged skin. *J Am Acad Dermatol* 1989;21(5 Pt 1):907-918, 1989.
13. Landau M. Exogenous factors in skin aging. *Curr Probl Dermatol* 2007;35:1-3.
14. Kosmadaki MG, Gilchrest BA. The role of telomeres in skin aging/photoaging. *Micron* 2004;35:155-159.
15. Nakamura KI et al. Comparative analysis of telomere lengths and erosion with age in human epidermis and lingual epithelium. *J Invest Dermatol* 2002;119:1014-1019.
16. Young AR. Acute effects of UVR on human eyes and skin. *Prog Biophys Mol Biol* 2006; 92(1):80-5.
17. Leyden JJ. Clinical features of ageing skin. *Br J Dermatol* 1990;122:1-3.
18. Seite S et al. Biological effects of simulated ultraviolet daylight: a new approach to investigate daily photo-protection. *Photodermatol Photoimmunol Photomed* 2006; 22:67-77.
19. Kochevar I. Molecular and cellular effects of UV radiation relevant to chronic photodamage. In: Gilchrest BA, editor: *Photodamage*. Cambridge, Mass: Blackwell Science; 1995.
20. Yaar M, Gilchrest BA. Photoageing: mechanism, prevention and therapy. *Br J Dermatol* 2007;157:874-887.
21. Saint Leger D et al. Age-associated changes in stratum corneum lipids and their relation to dryness. *Dermatologica* 1988;177:159-164.
22. Grove GL. Physiologic changes in older skin. *Clin Geriatr Med* 1989;5:115-125.
23. Seité S et al. Photodamage to human skin by suberythemal exposure to solar ultraviolet radiation can be attenuated by sunscreens: a review. *Br J Dermatol* 2010;163(5):903-914.
24. Kadunce DP et al. Cigarette smoking: risk factor for premature facial wrinkling. *Ann Intern Med* 1991;114:840-844.
25. Ernster VL et al. Facial wrinkling in men and women, by smoking status. *Am J Public Health* 1995;85:78-82.
26. Yin L et al. Skin aging induced by ultraviolet exposure and tobacco smoking: evidence from epidemiological and molecular studies. *Photodermatol Photoimmunol Photomed* 2001;17:178-183.
27. Yin L et al. Alterations of extracellular matrix induced by tobacco smoke extract. *Arch Dermatol Res* 2000;292:188-94.
28. Tur E et al. Chronic and acute effects of cigarette smoking on skin blood flow. *Angiology* 1992;43:328-35.
29. Robinson MK. Population differences in skin structure and physiology and the susceptibility to irritant and allergic contact dermatitis: implications for skin safety testing and risk assessment. *Contact Dermatitis* 1999;41:65-79.
30. Waller JM, Maibach HI. Age and skin structure and function, a quantitative approach (I): blood flow, pH, thickness, and ultrasound echogenicity. *Skin Res Technol* 2005;11:221-35.
31. Gniadecka M, Jemec GB. Quantitative evaluation of chronological ageing and photoageing in vivo: studies on skin echogenicity and thickness. *Br J Dermatol* 1998;139(5):815-821.
- Branchet MC et al. Skin thickness changes in normal aging skin. *Gerontology* 1990;36:28-35.
32. Branchet MC et al. Skin thickness changes in normal aging skin. *Gerontology* 1990;36:28-35.
33. Lavker RM. Structural alterations in exposed and unexposed aged skin. *J Invest Dermatol* 1979;73:59-66.
34. Batisse D, et al. Influence of age on the wrinkling capacities of skin. *Skin Res Technol* 2002;8:148-54.
35. Sandby-Moller J et al. Epidermal thickness at different body sites: relationship to age, gender, pigmentation, blood content, skin type and smoking habits. *Acta Derm Venereol* 2003;83:410-3.

36. Escoffier C, et al. Age-related mechanical properties of human skin: an in vivo study. *J Invest Dermatol* 1989;93:353–7.
37. Ghadially R et al. The aged epidermal permeability barrier. Structural, functional, and lipid biochemical abnormalities in humans and a senescent murine model. *J Clin Invest* 1995;95:2281–90.
38. Christophers E, Kligman A. Percutaneous absorption in aged skin. In: Montagna W, editor. *Advances in Biology of Skin*. Oxford: Pergamon; 1965.
39. Shetage SS et al. Effect of ethnicity, gender and age on the amount and composition of residual skin surface components derived from sebum, sweat and epidermal lipid. *Skin Res Technol* 2014;20(1):97–107.
40. Choi EH et al. Stratum corneum acidification is impaired in moderately aged human and murine skin. *J Invest Dermatol* 2007;127:2847–56.
41. Hachem JP et al. pH directly regulates epidermal permeability barrier homeostasis, and stratum corneum integrity//cohesion. *J Invest Dermatol* 2003;121:345–53.
42. Kligman AM. Perspectives and problems in cutaneous gerontology. *J Invest Dermatol* 1979;73:39–46.
43. Schreml S et al. Impact of age and body site on adult female skin surface pH. *Dermatology* 2012;224(1):66–71.
44. Graham-Brown RAC. Old age. In: Burns T, Breathnach S, Cox N, et al, editors. *Rook's Textbook of Dermatology*. vol. 6, Oxford: Blackwell Science; 2004.
45. Bernstein EF et al. Enhanced elastin and fibrillin gene expression in chronically photodamaged skin. *J Invest Dermatol* 1994;103(2):182–6.
46. Watson RE et al. Fibrillin-rich microfibrils are reduced in photoaged skin. Distribution at the dermal-epidermal junction. *J Invest Dermatol* 1999;112(5):782–7.
47. Watson R et al. A short-term screening protocol, using fibrillin-1 as a reporter molecule, for photoaging repair agents. *J Invest Dermatol* 2001;116(5):672–8.
48. Watson RE et al. Damage to skin extracellular matrix induced by UV exposure. *Antioxid Redox Signal* 2014;21(7):1063–77.
49. Cerimele D et al. Physiological changes in ageing skin. *Br J Dermatol* 1990;122(suppl 35):13–20.
50. Grove GL, Kligman AM. Age-associated changes in human epidermal cell renewal. *J Gerontol* 1983;38:137–142.
51. Goodson WH, Hunt TK. Wound healing and aging. *J Invest Dermatol* 1979;73:88–91.
52. Bosset S et al. Decreased expression of keratinocyte beta1 integrins in chronically sun-exposed skin in vivo. *Br J Dermatol* 2003;148:770–8.
53. Nordlund JJ. The lives of pigment cells. *Dermatol Clin* 1986;4(3):407–418.
54. Toyoda M, Morohashi M. Morphological alterations of epidermal melanocytes in photoageing: an ultra-structural and cytomorphometric study. *Br J Dermatol* 1998;139(3):444–52.
55. Fenske NA, Lober CW. Structural and functional changes of normal aging skin. *J Am Acad Dermatol* 1986;15:571–85.
56. Baumann L. Skin ageing and its treatment. *J Pathol* 2007;211:241–51.
57. Tobin DJ. Gerontobiology of the hair follicle. In Trueb RM & Tobin DJ (eds). *Aging Hair*. Berlin Heidelberg, Springer-Verlag, 2010, 1–8.

58. Kadono S et al. The role of the epidermal endothelin cascade in the hyperpigmentation mechanism of lentigo senilis. *J Invest Dermatol* 2001;116:571–7.2
59. Unver N et al. Alterations in the epidermal-dermal melanin axis and factor XIIIa melanophages in senile lentigo and ageing skin. *Br J Dermatol* 2006;155(1):119-28.
60. Farage MA et al. Structural characteristics of the aging skin: a review. *Cutan Ocul Toxicol* 2007;26:343–57.
61. Richard S et al. Noninvasive measurement of the effect of lifetime exposure to the sun on the aged skin. *Photodermatol Photoimmunol Photomed* 1994;10:164–9.
62. Makrantonaki E et al. Characteristics and pathomechanisms of endogenously aged skin. *Dermatology* 2007;214:352–60.
63. Varani J et al. Inhibition of type I procollagen synthesis by damaged collagen in photoaged skin and by collagenase-degraded collagen in vitro. *Am J Pathol* 2001;158:931–42.
64. Bosset S et al. Photoageing shows histological features of chronic skin inflammation without clinical and molecular abnormalities. *Br J Dermatol* 2003;149(4):826-35.
65. Uitto J. Connective tissue biochemistry of the aging dermis. Age-related alterations in collagen and elastin. *Dermatol Clin* 1986;4:433–46.
66. Braverman IM, Fonferko E. Studies in cutaneous aging: I. The elastic fiber network. *J Invest Dermatol* 1982;78:434–43.
67. Lavker RM et al. Aged skin: a study by light, transmission electron, and scanning electron microscopy. *J Invest Dermatol* 1987;88:44s–51s.
68. Gniadecka M et al. Ultrasound structure and digital image analysis of the subepidermal low echogenic band in aged human skin: diurnal changes and interindividual variability. *J Invest Dermatol* 1994;102:362–5.
69. Rittié L, Fisher GJ. UV-light-induced signal cascades and skin aging. *Ageing Res Rev* 2002;1:705–20.
70. Shuster S et al. The influence of age and sex on skin thickness, skin collagen and density. *Br J Dermatol* 1975;93:639–43
71. Lovell CR et al. Type I and III collagen content and fibre distribution in normal human skin during ageing. *Br J Dermatol* 1987;117:419–28.
72. Contet-Audonneau JL et al. A histological study of human wrinkle structures: comparison between sun-exposed areas of the face, with or without wrinkles, and sun-protected areas. *Br J Dermatol* 1999;140:1038–47.
73. Ritz-Timme S, Laumeier I et al. Aspartic acid racemization: evidence for marked longevity of elastin in human skin. *Br J Dermatol* 2003;149:951–9.
74. Robert C et al. Ageing of the skin: study of elastic fiber network modifications by computerized image analysis. *Gerontology* 1988;34:291–6.
75. Bernstein EF et al. Enhanced elastin and fibrillin gene expression in chronically photodamaged skin. *J Invest Dermatol* 1994;103:182–6.
76. Tsuji T, Hamada T. Age-related changes in human dermal elastic fibres. *Br J Dermatol* 1981;105:57–63.
77. Gniadecka M et al. Water and protein structure in photoaged and chronically aged skin. *J Invest Dermatol* 1998;111:1129–33.
78. Bernstein EF et al. Chronic sun exposure alters both the content and distribution of dermal glycosaminoglycans. *Br J Dermatol* 1996;135:255–62.

79. Gniadecka M et al. Structure of water, proteins, and lipids in intact human skin, hair, and nail. *J Invest Dermatol* 1998;110:393–8.
80. Farage MA et al. Degenerative changes in aging skin. *In* Farage MA, Miller KW, Maibach HI (eds). *Textbook of Aging Skin*. Berlin Heidelberg. Springer-Verlag 2010, 25-35.
81. Grove GL et al. Effect of ageing on the blistering of human skin with ammonium hydroxide. *Br J Dermatol* 1982;107:393–400.
82. Winkelmann R. Nerve changes in aging skin. *In*: Montagna W, editor. *Advances in Biology of Skin*. vol. 6, Oxford: Pergamon; 1965.
83. Gilchrest BA et al. Chronologic aging alters the response to ultraviolet-induced inflammation in human skin. *J Invest Dermatol* 1982;79:11–5.
84. Oberste-Lehn H. *In*: Montagna W, editor. *Aging. Effects of Aging on the Papillary Body of the Hair Follicles and on the Eccrine Sweat Glands*. vol. 6, Oxford: Pergamon; 1965.
85. Silver A et al. The effect of age on human eccrine sweating. *In*: Montagna W, editor. *Aging*. vol. 6, Oxford: Pergamon; 1965.
86. Rees J, Shuster S. Pubertal induction of sweat gland activity. *Clin Sci (Lond)* 1981;60:689–92.
87. Hurley J, Shelley W. *The Human Apocrine Sweat Gland in Health and Disease*. Springfield, Ill: Charles C Thomas; 1960.
88. Orentreich N et al. The effect of aging on the rate of linear nail growth. *J Invest Dermatol* 1979;73:126–30.
89. Helmdach M et al. Age and sex variation in lipid composition of human fingernail plates. *Skin Pharmacol Appl Skin Physiol* 2000;13:111–9.
90. Garn SM et al. Scalp thickness and the fat-loss theory of balding. *AMA Arch Derm Syphilol*. 1954;70(5):601–8.
91. Plewig G, Kligman AM. Proliferative activity of the sebaceous glands of the aged. *J Invest Dermatol* 1978;70:314–7.
92. Pochi PE et al. Age-related changes in sebaceous gland activity. *J Invest Dermatol* 1979;73:108–11.
93. Gilchrest BA. Aging. *J Am Acad Dermatol* 1984;11:995–7.
94. Smith L. Histopathologic characteristics and ultrastructure of aging skin. *Cutis* 1989;43:414–24.
95. Karnik P et al. Microarray analysis of androgenetic and senescent alopecia: comparison of gene expression shows two distinct profiles. *J Dermatol Sci* 2013;72(2):183–6.
96. Ellis JA et al. Androgenetic alopecia: pathogenesis and potential for therapy. *Expert Rev Mol Med* 2002;4:1–11.
97. Olsen EA et al. Evaluation and treatment of male and female pattern hair loss. *J Am Acad Dermatol* 2005;52(2):301–11.
98. Whiting DA. Male pattern hair loss: current understanding. *Int J Dermatol* 1998;37:561–6.
99. *Aging Hair*. Trueb RM & Tobin DJ (Eds). Springer-Verlag, Berlin Heidelberg 2010.
100. Keogh EV, Walsh RJ. Rate of greying of human hair. *Nature* 1965;207:877–8.
101. Panhard S et al. Graying of the human hair: a worldwide survey, revisiting the '50' rule of thumb. *Br J Dermatol* 2012;167(4):865–73.
102. Commo S et al. Human hair greying is linked to a specific depletion of hair follicle melanocytes affecting

- both the bulb and the outer root sheath. *Br J Dermatol* 2004;150:435–43.
103. Tobin DJ, Paus R. Graying: gerontobiology of the hair follicle pigmentary unit. *Exp Gerontol* 2001;36(1):29–54.
104. Kauser S et al. Human hair follicle and epidermal melanocytes exhibit striking differences in their aging profile which involves catalase. *J Invest Dermatol* 2011;131(4):979–82.
105. Nishimura EK et al. Mechanisms of hair graying: incomplete melanocyte stem cell maintenance in the niche. *Science*. 2005;307(5710):720–724.
106. Gilchrist BA et al. Effect of chronologic aging and ultraviolet irradiation on Langerhans cells in human epidermis. *J Invest Dermatol* 1982;79:85–8.
107. Thiers BH et al. The effect of aging and chronic sun exposure on human Langerhans cell populations. *J Invest Dermatol* 1984;82:223–6.
108. Bhushan M et al. Tumour necrosis factor-alpha-induced migration of human Langerhans cells: the influence of aging. *Br J Dermatol* 2002;146:32–40.
109. Makinodan T. Immunodeficiencies of ageing. In: Doria G, Eshkol A, editors. *The Immune System: Functions and Therapy of Dysfunction*. New York: Academic Press; 1980.
110. Ben-Yehuda A, Weksler ME. Host resistance and the immune system. *Clin Geriatr Med* 1992;8:701–11.
111. Hall G, Phillips TJ. Estrogen and skin: The effects of estrogen, menopause, and hormone replacement therapy on the skin. *J Am Acad Dermatol* 2005;53:555–68.
112. Brincat M et al. Long-term effects of the menopause and sex hormones on skin thickness. *Br J Obstet Gynaecol* 1985;92:256–9.
113. Affinito P et al. Effects of postmenopausal hypoestrogenism on skin collagen. *Maturitas* 1999;33:239–47.
114. Brincat M et al. Skin collagen changes in post-menopausal women receiving estradiol gel. *Maturitas* 1987;9:1–5
115. Brincat M et al. Skin collagen changes in postmenopausal women receiving different regimens of estrogen therapy. *Obstet Gynecol* 1987;70:123–7.
116. Bologna JL et al. Skin changes in menopause. *Maturitas* 1989;11:295–304.
117. Calleja-Agius J, Muscat-Baron Y, Brincat MP. Skin ageing. *Menopause Int* 2007;13:60–4.
118. Dunn LB et al. Does estrogen prevent skin aging? Results from the first national health and nutrition examination survey (NHANES I). *Arch Dermatol* 1997;133:339–42.
119. Ashcroft GS et al. Estrogen accelerates cutaneous wound healing associated with an increase in TGF-beta1 levels. *Nat Med* 1997;3:1209–15
120. Callens A et al. Does hormonal skin aging exist? A study of the influence of different hormone therapy regimens on the skin of postmenopausal women using non-invasive measurement techniques. *Dermatology* 1996;193:289–94.
121. Sator PG et al. The influence of hormone replacement therapy on skin ageing: a pilot study. *Maturitas* 2001;39:43–55.
122. Thornton MJ. Estrogens and aging skin. *Dermatoendocrinol* 2013;5(2):264–70.
123. Scharffetter-Kochanek K et al. Photoaging of the skin from phenotype to mechanisms. *Exp Gerontol* 2000;35:307–16.

124. Brincat MP. Hormone replacement therapy and the skin. *Maturitas* 2000;35:107–17.

125. Li GZ et al. Evidence that exposure of the telomere 3' overhang sequence induces senescence. *Proc Natl Acad Sci USA* 2003;100:527–B1.

ACCEPTED MANUSCRIPT