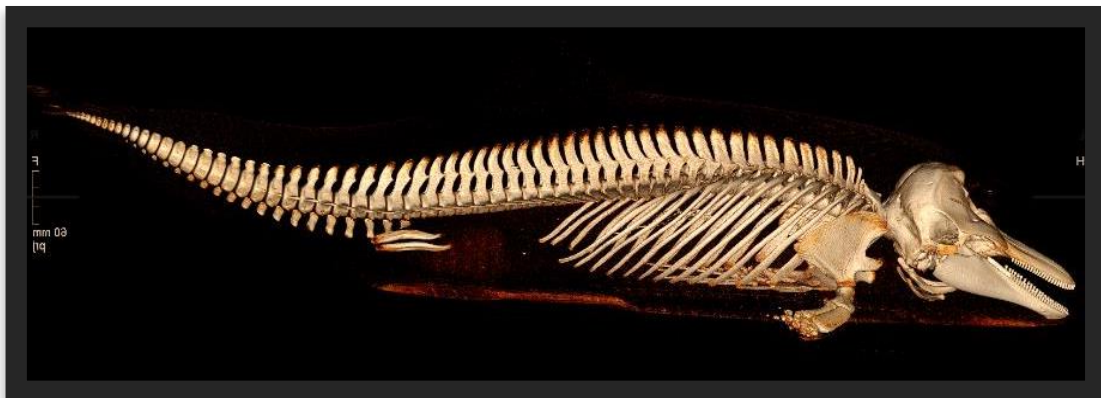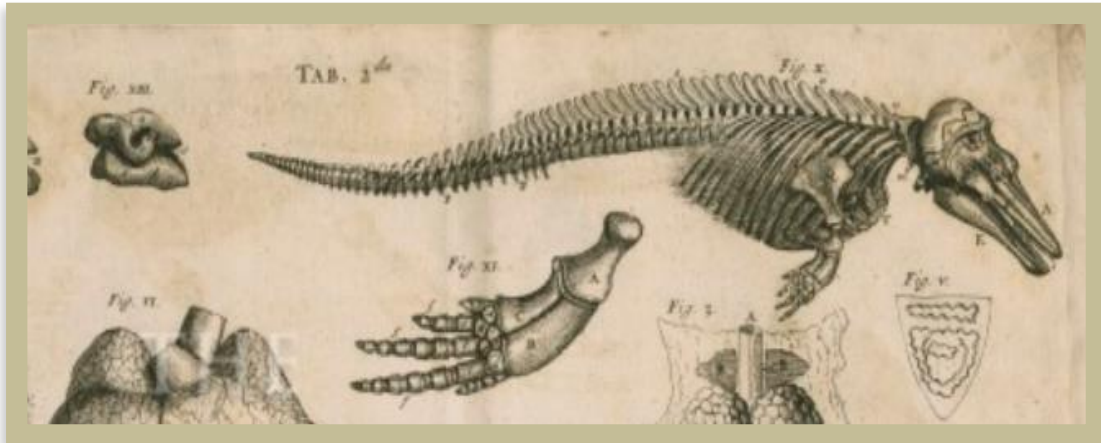


# Best practice on cetacean post mortem investigation and tissue sampling

Joint ACCOBAMS and ASCOBANS document



Editors:

Lonneke L. IJsseldijk • Andrew C. Brownlow • Sandro Mazzariol

September 2019



**Editors: Lonneke L. IJsseldijk<sup>a</sup>, Andrew C. Brownlow<sup>b</sup> & Sandro Mazzariol<sup>c</sup>**

<sup>a</sup>Faculty of Veterinary Medicine, Utrecht University, Pathology Division, Utrecht, The Netherlands

<sup>b</sup> Scottish Marine Animal Stranding Scheme, SRUC Northern Faculty, Inverness Campus, Inverness Scotland

<sup>c</sup>Department of Comparative Biomedicine and Food Science, Università degli Studi di Padova, Legnaro, Padova, Italy

With contributions from:

**Agreement for the Conservation of Cetaceans of the Baltic Sea, Mediterranean Sea and Contiguous Atlantic Area (ACCOBAMS)**

- Aviad Scheinin

**Agreement on the Conservation of Small Cetaceans of the Baltic, North East Atlantic, Irish and North Seas (ASCOBANS)**

**Cetacean Strandings Investigation Program, Zoological Society of London, London, United Kingdom**

- Rob Deaville, Paul D. Jepson, Matthew W. Perkins

**Cornwall Wildlife Trust Marine Strandings Network, Cornwall, United Kingdom**

- James Barnett

**C.Re.Di.Ma. , Istituto Zooprofilattico Sperimentale del Piemonte, Liguria and Valle d'Aosta, Italy**

- Carla Grattarola, Cristina Caselone

**Dipartimento di Scienze Fisiche, della Terra e dell'Ambiente, Università degli Studi di Siena, Siena, Italy**

- Maria Cristina Fossi, Letizia Marsili

**Facoltà di Medicina Veterinaria, Università degli Studi di Teramo, Teramo, Italy**

- Giovanni Di Guardo

**Pathology Division, Faculty of Veterinary Medicine, Utrecht University**

- Andrea Gröne

**International Whaling Commission (IWC)**

- Karen Stockin

**Institute for Neurosciences of Montpellier (INSERM U1051), France**

- Maria Morell

**Institute for Terrestrial and Aquatic Wildlife Research, University of Veterinary Medicine Hannover, Büsum, Germany**

- Miguel Grilo, Kristina Lehnert, Abbo van Neer, Anja Reckendorf, Ursula Siebert

**Moredun Research Institute, Edinburgh, Scotland, United Kingdom**

- Mark P. Dagleish

**Observatoire Pelagis, La Rochelle, France**

- Willy Dabin, Paula Mendes Fernandez

**Scottish Marine Animal Stranding Scheme, SRUC Northern Faculty, An Lòchran, Inverness Campus, Inverness Scotland**

- Nicholas J. Davison, Mariel T.I. ten Doeschate

**University of Las Palmas de Gran Canaria, Spain**

- Manolo Arbello, Yara Bernaldo de Quirós, Antonio Jesús Fernández Rodríguez, Jesus de la Fuente, Eva Sierra

**Veterinary Faculty, University of Liège, Liège, Belgium**

- Thierry Jauniaux

## PREFACE

Human society is changing rapidly. Our global gross domestic product has tripled in the last 25 years, with a concomitant increase in human impact on the marine environment. To measure the effects of this impact on cetacean health, it is crucial to perform long-term monitoring of dead cetaceans. Such monitoring includes the examination of their organs for pathological changes, collection of tissue samples for toxicology, and taking measurements for life history, according to a standardised and internationally harmonised protocol.

I missed such a protocol in the early 1990s, when, as a recently graduated veterinarian, I started studying the pathology of stranded cetaceans in England and Wales. At meetings of the European Cetacean Society (ECS), I met biologists who were highly experienced in examining and sampling stranded cetaceans to learn more about their life history, diet, parasites, and pollutant burdens. However, there were very few people studying their pathology.

Among the ECS members was another veterinarian, Manuel Garcia Hartmann, who, like me, was interested in cetacean pathology. In 1991, together with Marjan Addink, we organised a workshop at the National Natural History Museum in Leiden and brought together biologists and veterinarians who examined stranded cetaceans, as well as specialists in a variety of relevant laboratory analyses. During the day, post mortem examinations on harbour porpoises were demonstrated, and sampling procedures were discussed. At night, assisted by Johnny Walker, Manuel and I worked up our notes. The end result was a standard post mortem protocol for small cetaceans that integrated pathology, life history, and toxicology. Appearing at a time when ASCOBANS-based monitoring programs were being developed in several European Countries, this protocol was adopted and further developed widely and has been cited over 100 times in scientific publications.

The publication before you now is a more organised and better illustrated edition of that old protocol, and incorporates advances in laboratory techniques and new knowledge of cetacean diseases. Its essence has remained the same, namely to integrate the pathological examination of a dead cetacean with the measurements and sampling for life history and toxicology. This is illustrated well by the background training of the Editors: biology (Lonneke IJsseldijk) and veterinary medicine (Andrew Brownlow and Sandro Mazzariol). My wish is similar to the one Manuel and I expressed 25 years ago: that this protocol will prove useful and be widely adopted, and so help to provide a view of the biology and pathology of cetaceans that is not limited by the borders of Countries.

*Thijs Kuiken, Rotterdam, August 2019.*

## Table of Contents

PREFACE .....	4
Introduction and background .....	7
Monitoring of stranded or bycaught animals .....	9
Glossary .....	10
Multi-Tier Triage Approach .....	12
Tier One – External examination and stranding data collection .....	13
Tier Two – Post mortem investigations and tissue sampling .....	13
Tier Three – Post mortem examination with diagnostic aims .....	13
Legislation and permits .....	14
Health and Safety .....	16
Biological risks .....	16
Environmental risks .....	17
Chemical and residue risks .....	17
Post mortem risks .....	17
Carcass disposal .....	18
Evaluation of the carcass .....	19
External Features .....	19
Internal Features .....	20
Carcass Decomposition Classification .....	20
Description and photographs .....	22
Effects of decomposition code on investigative tests .....	23
Tier One: Basic morphometrics, external examination and basic tissue sampling .....	26
Data collection and photographs .....	26
Body measurements .....	27
Freezing carcasses prior to post mortem examination .....	27
Tier Two: Post mortem investigations and sampling .....	29
External examination .....	30
Nutritional condition state .....	31
Subcutaneous examination .....	32
Visualisation of internal organs .....	33
Examination of abdominal organs (except GIT) .....	33
Examination of GIT .....	35
Examination of head and neck region, and thoracic organs .....	36
Examination of the head .....	39
Examination of the skeletal system and rete mirabilis .....	41

Tissue sampling procedures, storage and analysis .....	42
Morphometric studies and imaging.....	42
Tissue sampling and storage .....	42
Labelling of samples .....	43
Tissue and biological specimens' archive .....	44
Age determination .....	44
Diet analysis, marine litter and micro- /nano-plastics.....	45
Genomic (DNA) studies and RT-PCR ecotoxicological investigations .....	46
Reproduction studies .....	46
Histopathology and immunohistochemistry samples .....	46
Microbiology .....	48
Virology .....	49
Parasitology.....	49
Toxicology .....	50
Biotoxins.....	51
Suggested sampling tables.....	51
Acknowledgements.....	62
Literature.....	63
Annex 1. Decomposition condition coding example pictures .....	67
Annex 2. Additional body measurements to consider .....	70
Annex 3. Brain sampling image.....	71

## Introduction and background

Monitoring dead stranded cetaceans offers an often unique opportunity to gain insights into the health of, and threats and stressors affecting, marine ecosystems (e.g. Dierauf & Gulland 2001; Gulland & Hall 2009; Van Bressemer et al. 2009; Peltier et al. 2012, 2013; Plön et al. 2015). Information derived from the systematic examination of stranded carcasses can provide insights into the at-sea population not easily acquired through other means, indeed strandings data is the major source of information available for some species (Reyes et al. 1991; Pyenson 2011). Detailed investigation of carcasses can assist in the determination of causes of death and provides general surveillance on the incidence of trauma and disease (Siebert et al. 2001, 2006; Jauniaux et al. 2002; Arbelo et al. 2013; Di Guardo et al. 2013; Lane et al. 2014; Díaz-Delgado et al. 2018). Investigations can identify existing and emerging threats due to human impact, such as bycatch (Leeney et al. 2008, Peltier et al. 2016) and marine pollution (Siebert et al. 1999; Jepson et al. 2016), as well as provide tissues and data for subsequent analysis into a range of biological and ecological parameters. The collection of data and samples for ancillary investigations over a range of disciplines can provide information on the general population ecology, helping countries evaluate and mitigate possible threats affecting species conservation and the marine ecosystem.

Many EU countries operate cetacean strandings investigation networks as part of their obligations to international agreements. These include the “Agreement on the Conservation of Small Cetaceans of the Baltic, North East Atlantic, Irish and North Seas” (ASCOBANS), the “Agreement for the Conservation of Cetaceans in the Black Sea, Mediterranean Sea and contiguous Atlantic Area” (ACCOBAMS), the EU Habitats Directive (NATURA2000), the OSPAR Commission and the “Baltic Marine Environment Protection Commission” (HELCOM). The Marine Strategy Framework Directive (MSFD) obliges the member states to develop indicators and descriptors for the surveillance of “Good Environmental Status” of cetaceans.

Many of these strandings networks are well established and have long-term datasets comprising extensive biological and pathological information from the systematic collation and investigation of mortalities. In addition, many European strandings networks curate uniquely important tissue and pathogen archives. Most networks follow the original protocol by Kuiken and Hartmann, published in 1993 as a special issue of the European Cetacean Society. In the subsequent decades, stranding networks throughout Europe have developed, and new analytical techniques (e.g. assessment of the effects of

barotrauma) or health impacts e.g. grey seal predation, have been incorporated into operational methods.

During the VIII ASCOBANS Meeting of the Party (MoP) in 2016, the Advisory Committee (AC) and Secretariat were requested to engage actively in the work on best practice guidelines for response to stranding events and in the establishment of an updated post-mortem protocol within the frameworks of the International Whaling Commission (IWC), ACCOBAMS and the European Cetacean Society (ECS) under Resolution 8.10. In the same year, ACCOBAMS endorsed the document on common best practices for a basic post mortem examination of stranded cetaceans under the Resolution no. 6.22 during the VI MoP. In the same Recommendation, an approach to ASCOBANS, ECS and IWC was requested to the Scientific Committee (SC) to review the common definitions, common data collections and common post-mortem protocols during the triennium. In 2018, during the 24th ASCOBANS AC and 12th ACCOBAMS SC a joint workshop was proposed to harmonize the existing initiatives. This meeting was organised in Padua (Italy) in June 2019 involving 24 experts from different countries of the two regional Agreements and from Macaronesia area representing the MARCET project.

The aim of this document is to update the protocol with the currently available techniques and knowledge agreed between all member countries of ACCOBAMS and ASCOBANS. It is hoped that this updated protocol can serve three overall aims:

To provide a reference document for veterinarians and biologists currently engaged in cetacean post-mortem investigation, summarising a recognised approach to stranding investigation across European networks;

To highlight areas where harmonisation of data from existing networks could allow for analysis and inference to be made between networks, of particular relevance for the transboundary, mobile species;

Provide a start-up guide for researchers attempting to instigate new stranding monitoring programmes, particularly in regions of the world with limited resources for extensive, top-down surveillance programmes.

It should be emphasised that this document is not designed to replace existing protocols, particularly those of longstanding and well established laboratories and stranding networks, but offers a post mortem framework aiming for consistency across Europe when conducting examinations on dead cetaceans. By outlining current European best



practices, it has been assumed that there is sufficient time and resources to carry out a full post mortem examination, although it is recognised this may not always be the case.

The quality of the information gathered is influenced by logistical capacity, e.g. carcass accessibility, available equipment/supplies and finances; and the skills, experience and capacity of the human resources. Nonetheless, it should be emphasized that following a precise and well defined data collection procedure ensures the information collected during post-mortem investigations is of high quality. To be able to assess cause of death and health status, a full post mortem investigation with additional examinations as proposed below is deemed necessary and therefore highly recommended. If a full investigation cannot be carried out for any reason, one should always attempt to collect the following data: species, sex, stranding location, stranding date and (approximate) body length to assess age class. Additionally, teeth (for ageing), skin (for genetic analysis), blubber and muscle (for toxicological screening) and swabs of genital slit and blowhole (for e.g. virological and microbiological analysis) can be relatively easily collected.

### Monitoring of stranded or bycaught animals

Data from dead cetaceans, including stranded and bycaught individuals, offer a means to sample the at-sea population, making it possible to obtain, in some cases, data not accessible through other means of surveillance. There are discussions around the extent to which investigations on dead animals can inform on the wider population due to several biases intrinsic to the stranding process. Strandings are a complex result of biological, physical and social (effort) processes that influence observed mortality (ten Doeschate et al. 2018). These should be taken into account when making population level inferences based on the examination of stranded or bycaught individuals. Where an increase in strandings could indicate increased mortality or increased abundance (biological variation), it may well be a consequence of unusual variation in environmental conditions such as wind or tide or observer efforts. It is therefore encouraged to acknowledge all three components of the stranding process during mortality investigations.

It needs to be highlighted that the quality and output of post mortem investigations is strongly dependent on the quality of the stranding network in terms of spatiotemporal coverage, collecting environmental information in relation with the stranding event and the time between the collection of the carcass and start of post mortem investigation.

## Glossary

Here is a collection of common terms and definitions frequently used throughout the document, and general terminology used in stranding events and forensic human and veterinary medicine.

**DEAD CETACEAN:** Comprises cetaceans found dead on the shore or floating at sea and cases which live strand and subsequently die or are euthanized. Includes animals found dead entangled in fishing gear. Signs of death are absence of breathing, cardiac arrest and absence of neuronal activity.

**STRANDED CETACEAN:** A stranded cetacean is one whose body lies entirely on land, and includes both dead and live animals found in a helpless state after faltering ashore ill, wounded, weak, or simply lost. In this document it is expanded to include animals either dead or alive but showing clear signs of physiological dysfunction in shallow waters. On the basis of the number of animals involved, it is possible to distinguish between single and mass strandings.

**ENTANGLED CETACEAN:** Animals found completely or partially entangled in either marine debris or active or discarded fishing gear, for example ropes, nets or straps.

**UNUSUAL MORTALITY EVENT (UME):** A UME is an unexpected mortality of cetaceans at an abnormally large scale compared to average stranding reports for the species or involves a significant die-off of any marine mammal population, and demands immediate response. There are seven criteria that make a mortality event "unusual."

1. A marked increase in the magnitude or a marked change in the nature of morbidity, mortality, or strandings when compared with prior records.
2. A temporal change in morbidity, mortality, or strandings is occurring.
3. A spatial change in morbidity, mortality, or strandings is occurring.
4. The species, age, or sex composition of the affected animals is different than that of animals that are normally affected.
5. Affected animals exhibit similar or unusual pathologic findings, behavior patterns, clinical signs, or general physical condition (e.g., blubber thickness).
6. Potentially significant morbidity, mortality, or stranding is observed in species, stocks, or populations that are particularly vulnerable (e.g., listed as depleted, threatened, or endangered or declining). For example, stranding of three or four right whales may be cause for great concern whereas stranding of a similar number of fin whales may not.
7. Morbidity is observed concurrent with or as part of an unexplained continual decline of a marine mammal population, stock, or species.

Main recognised causes are sudden emergence of an infectious disease or a disease outbreak, biotoxins, or human interactions (including environmental accidents). Features of these mass mortalities (i.e. temporal and spatial distribution) do not correspond to mass strandings, as defined below.

**MASS STRANDING:** These events involve two or more cetaceans (excluding cow/calf pairs) stranded at the same time and place. Several causes may be responsible for this event, including, but not limited to, extreme weather conditions, tidal changes, disease of one or several group members, or human-related actions. It is noteworthy that some individuals involved in a mass stranding may be completely healthy.

**DISEASE OUTBREAK:** An UME specifically involves infectious agents. This can represent the emergence of a novel pathogen or disease, be caused by a known pathogen not previously recognized in that species or geographic area, or manifest as an abnormal increase in the incidence of stranded individuals in a region, season or population. An outbreak may occur in a restricted geographical area, or may extend over an entire basin and can range in duration from a few days to several years.

**DISSECTION/PROSECTION:** Medical and/or biological procedure to dismember the body of a deceased animal according to specific protocols in order to study its anatomical structure and/or to evaluate and sample specific organs and tissues.

**NECROPSY/AUTOPSY/POST-MORTEM/POST MORTEM EXAMINATION** Synonyms for a specialised medical procedure comprising of a thorough examination of a carcass by dissection to determine the cause, the mechanism and manner of death through the collection of evidence. In the case of wild animals this requires the involvement of a veterinary pathologist or a veterinarian with specific training in animal pathology, diseases and assessment of health.

**POST MORTEM INVESTIGATIONS:** All studies and investigations carried out on an animal's carcass and/or samples taken after death, including those aimed to determine the cause of death.

**HEALTH STATUS:** Subjective assessment of diseases, conditions, or injuries that not only contributed to the proximal cause of death but which characterize the ante-mortem health status of the individual and the possible health status of cohort animals.

**CAUSE OF DEATH/STRANDING:** The disease, injury or abnormality that alone or in combination with other factors (environmental, other concurrent diseases, age, etc.) is responsible for initiating the sequence of functional disturbances that resulted in live

stranding and death. In the case of an aquatic animal stranded on shore, the post mortem investigation is aimed to determine the cause of stranding. During this procedure the following may be further defined:

Immediate cause of death: final disease or condition resulting in death;

Underlying cause of death: the disease or injury that initiated the chain of morbid events that led directly and inevitably to death;

Contributing factors: other significant diseases, conditions, or injuries/impacts/influences that may have contributed to death but which did not constitute an underlying cause of death.

**MECHANISM OF DEATH:** The immediate physiologic derangement resulting in death. A particular mechanism of death can be produced by a variety of different causes of death.

**MANNER OF DEATH:** How death came about; in the case of wildlife and, specifically, in cetaceans, we can distinguish:

Natural, due mainly to natural disease or toxic processes;

Anthropic/anthropogenic, accidental like ship strikes, bycatch, or non-accidental due to a volitional act or direct killing;

Undetermined, inadequate information regarding the circumstances of death in order to determine the manner.

### Multi-Tier Triage Approach

No two stranding networks are identical; the scientific requirements, political drivers, resources, infrastructure and experience vary both within and between stranding networks. Nonetheless, it is possible to maximize the capacity to compare or combine data collected under different operational models, whilst minimizing inaccuracies and biases. Here we outline how a tiered approach to carcass triage allows investigations to be conducted at a number of levels, depending on the resources, facilities or experience of the stranding network. Whilst the 'gold standard' centres around a thorough and detailed post-mortem investigation conducted by well-resourced and experienced veterinary pathologists, it is recognised that this capacity is often the exception rather than the rule. The tiered approach, outlined below, offers a framework for data collection and interpretation appropriate to the resources available.

Additionally, given the specialised nature of this work, this recognizes that not all analyses and ancillary tests are available in all countries. An additional section annexed to this

document will list the detailed literature for specific issues, techniques and investigations aiming to help establish a mechanism for identifying specialised laboratories to share expertise and analyses at an international level. Finally, this approach enables information recovered from individual cases to be optimized depending on the resources available.

### Tier One – External examination and stranding data collection

#### Who can do this?:

Wide range of personnel who have basic training.

#### What is assessed?:

External examination only, aiming to collect basic morphometric data, assessment of decomposition condition, sex and age class determination, and photographs of external features. Based on information collected in this tier, a decision should be made by an experienced person whether an animal is suitable for further post mortem investigation (also depending upon logistics etc.). On its own, a tier one examination will not permit any reliable assessment of health status nor allow conclusions to be drawn as to the cause of death but can provide vital basic data and identify cases for more detailed investigation should this be required.

### Tier Two – Post mortem investigations and tissue sampling

#### Who can do this?:

Trained responders with expertise in animal dissections and awareness of potential hazards e.g. zoonotic infections.

#### What is assessed?:

In addition to tier one data: thorough post mortem investigation, involving the visualization and gross inspection of all organ systems and a detailed description of findings. Samples can be collected to allow subsequent assessment of life history, diet, contaminant or disease status, identify indicators of trauma and assess both body and carcass condition scores. In the absence of professional experience (see tier three), findings should however be considered informative, but not conclusive.

### Tier Three – Post mortem examination with diagnostic aims

#### Who can do this?:

Experienced professionals, for example veterinary pathologists and/or biologists (depending on the country's legal framework) able synergize diagnostic results from

multiple sources to provide an overall assessment of health and a cause, mechanism and manner of death.

### What is assessed?:

The aim of a post mortem examination at this level is to establish the cause(s) of death and to assess the health status of the individual(s) investigated. This process is as much about excluding potential aetiologies as identifying them.

Whilst a basic set of morphometrics can be collected by any suitably trained personnel (tiers one and two), a complete necropsy is a specialist undertaking requiring qualified personnel, a systematic approach and adherence to relevant safety protocols (tier three). This involves additional or detailed analysis of the data and samples collected during post mortem investigation (tier two), aiming to understand wider parameters of ecological health. Analyses can incorporate life history and diet analysis, age determination, assessment of contaminant burdens and identification of infectious agents. The latter can be the result of both as “indirect” (sero-epidemiological investigations) and “direct” (microbiological, virological, parasitological, biomolecular and immunohistochemical, ecotoxicological) investigations, providing evidence of both active infection and recent and past pathogen exposure. This tier of investigation usually requires use of specialised laboratories or collaboration with other stranding investigation groups.

**This document describes the best practices for cetacean post mortem investigations, and outlines basic best practice up to and including tier two. Guidance in cetacean post mortem examinations or causes of death at tier three is outwith the scope of the basic protocol outlined below.** For this level, it is recommended that a veterinarian with specific training in pathology is involved in the examination, and principles and protocols according to professional bodies such as the European College of Veterinary Pathology (ECVP) are followed.

## Legislation and permits

The international community has recognised the necessity to ensure conservation of cetaceans through the protection of species and their habitats. In this respect, several international conventions and agreements, including associated protocols, are currently ratified. Among these are the International Convention for the Regulation of Whaling (ICRW; Washington, 1946; <http://iwc.int>, currently: International Whaling Commission (IWC)). The Convention on International Trade in Endangered Species of Fauna and Flora

(CITES; Washington, 1973; [www.cites.org](http://www.cites.org)). The Convention for the Protection of the Marine Environment and the Coastal Region of the Mediterranean (Barcelona 1976; [www.unepmap.org](http://www.unepmap.org)). The Convention on the Conservation of European Wildlife and Natural Habitats (Bern, 1979; <http://www.coe.int>). The Convention on the Conservation of Migratory Species of Wild Animals (CMS; Bonn, 1979; [www.cms.int](http://www.cms.int)). The Oslo-Paris (OSPAR 1992; <https://www.ospar.org/>) convention. The Helsinki Convention (HELCOM 1992; <http://www.helcom.fi/>), and many other Agreements that regulate cetaceans' conservation and protection. ACCOBAMS and ASCOBANS are embodied within CMS.

The following frameworks for the protection of cetaceans in Europe are currently in place: the Council Directive 92/43/EEC of 21 May 1992 on the conservation of natural habitats and of wild fauna and flora (Habitat Directive). Directive 2008/56/EC of the European Parliament and of the Council establishing a framework for community action in the field of marine environmental policy (Marine Strategy Framework Directive). The Regulation (EC) 1332/2005 on the protection of species of wild fauna and flora by regulating trade therein (CITES) which substitutes and completes Council Regulation (EC) No 338/97 of 9 December 1996 on the protection of species of wild fauna and flora by regulating trade therein.

The scope of these legal frameworks range from wider biodiversity conservation to mechanisms for conservation of specific species and habitats (strict protection of species, establishment of protected areas, etc.) and supporting environmental protection mechanisms, such as environmental impact assessments. Many of these conventions, directives or statutory instruments demand some level of monitoring of the conservation status of relevant species, and this often provides the policy drivers to support stranding investigations. Whilst none of the legislation explicitly state how these populations should be monitored, a thorough investigation of stranded carcasses via post mortem examinations can offer an effective and relatively cost efficient way to meet the stated requirements.

National legal frameworks also play an important role: national legislation will determine the minimum level of training required to undertake examination of stranded animals. According to EU regulations for animal carcass disposal, a veterinary assessment of the zoonotic hazard should be undertaken prior to investigation or disposal. It is also worth highlighting that, due to their elevated protected status, the national laws of many EU member countries only permit nominated and trained people to handle, transport or possess material from cetaceans. Any post mortem investigation should also consider that each country will have implemented a national approach to animal carcass disposal, in

order to adhere to biosanitary regulations and protect public health. For this reason, any manipulation of stranded cetaceans needs to adhere to the relevant legal frameworks and with agreement from the local authorities. In order to carry out post mortem investigations, undertake diagnostic analyses or collect, store or transport samples, specific permits and derogations may be required according to the individual countries' legal framework and CITES regulations.

## Health and Safety

Live, dead or decaying marine mammal tissues may harbour a variety of potentially harmful zoonotic pathogens and the collection, transportation and post mortem examination of dead marine mammals potentially carries several hazards. It is strongly advised that each scheme conducts a review of their health and safety protocols according to their local or national operating procedures and legislations.

Whilst it is outside the scope of this protocol to provide comprehensive assessments for all possible hazards, a few key principles and factors are highlighted below:

## Biological risks

The zoonotic risk from marine mammals is reported to be low. There is an infection hazard from exposure of abraded or broken skin or mucous membranes (including the conjunctiva and respiratory tract) to fluid from a marine animal. Any such exposure should be reported to a medical professional. Immediate disinfection, or in case of direct eye contact, thorough rinsing is necessary and possibly justify appropriate antibiotic prophylaxis. It is advisable to highlight the potential risks from *Brucella*- and *Mycoplasma* exposure ('seal finger', where initial symptoms may include redness and swelling of the hand), along with that to *Neisseria* sp., *Erysipelothrix rhusiopathiae* and to hitherto unknown pathogens.

It is strongly advised that a hygiene protocol be implemented for all individuals that are involved with the retrieval, transportation or handling of tissue derived from marine mammal carcasses. All sampling should be done wearing gloves and appropriate personal protective equipment and, in the case of live animals, with suitable respiratory protection to guard against aerosol inhalation. Immunocompromised individuals e.g. due to cortisol treatment, pregnancy, age, certain viral infections etc. have a higher susceptibility to



zoonotic infections and should avoid contact with carcasses or samples derived from stranded marine mammals.

### Environmental risks

Hazards of working on remote locations, possibly with poor cell phone reception, hazards of the coastal environment such as slips and trips, tide, weather, low visibility and risk of hypo- and hyperthermia should be taken into account. The physical and machinery hazards associated with moving a large marine animal should also be considered.

### Chemical and residue risks

Drugs administered to the animal ante-mortem or for the purposes of euthanasia, comprise a notable health and environmental hazard. Most chemical euthanasia compounds are highly potent and persist in tissues after death, making them a potential hazard to those conducting post mortem investigations or disposal operations as well as to the environment (e.g. secondary poisoning of scavengers). It is imperative that the name, volume and injection site is established for any drugs administered to the animal, with all the necessary mitigation being also put in place to ensure human, wildlife and environmental safety. Other hazards may originate from animals with a high pollutant burden in tissues, e.g. PCB, or in cases of environmental contamination, e.g. oil spill, which require specific handling and carcass disposal procedures are followed. Chemicals used during the post mortem examination, for example 10% neutral buffered formalin and ethanol, are also hazardous and the appropriate health and safety procedures should be put in place to safeguard operators from exposure.

### Post mortem risks

Prior to any examination involving the moving or opening of a carcass, it is essential to assess and mitigate any potential environmental or public health hazards. Biosecurity factors to consider includes risks from the leakage of fluids, noxious odours or aerosols from the carcass, along with the aesthetic and social impacts on civil society and individual members of the public. It is advised, whenever possible, post mortem examinations are conducted in a secure area with adequate access to light, clean water and effective containment of effluent.

## Carcass disposal

Once the post mortem investigation has been completed, the carcass must be disposed in accordance with existing national legal framework regulations, in order to ensure human safety and prevent disease transmission. In many countries, responsibility for disposal lies with the local authorities, however advice may be sought from stranding investigation teams. In the EU, wild species, including cetaceans are excluded from the EU Regulations no. 1069/2009 and 142/2011 if not suspected of being infected or affected with a disease communicable to humans or animals and each member state has developed national strategies including options for carcass disposal as listed below. Local (veterinary) authorities and qualified technicians should be contacted before moving the carcass to start the post mortem procedures.

**NATURAL DECOMPOSITION:** if the post mortem is carried out on a remote, difficult to reach, isolated shore, it may be possible to gain permission to leave the carcass open for natural scavengers. This is not recommended following euthanasia by chemicals. State of decomposition will vary depending on environmental factors and species, and it is important to have good images of the state of the carcass when it was left on site so it can be identified if it re-strands (elsewhere).

**BURIAL ON SITE:** If the ecology and local regulations allow, beach burial is often the easiest, most affordable option for larger cetaceans. Local permissions should be sought to avoid contamination or disruption of water supplies and other environmentally sensitive areas. Suitable excavators and heavy equipment are however required to ensure the carcass is buried deep enough to avoid re-exposure during winter storms. Ideally, a hole should be dug in close proximity to the carcass prior to the start of the post mortem examination to immediately discard soft tissues during the dissection. If the carcass may be subsequently exhumed for accession of skeletal remains to a museum collection, burial sites should be marked precisely with GPS or with ferrous material to assist locating it by metal detector.

**AT-SEA DISPOSAL:** Towing carcass remains offshore is an option for larger specimen, but care needs to be taken to ensure the carcass sinks to prevent it from being a hazard to shipping, or material washing back ashore.

**TRANSPORT TO LANDFILL:** Transport for post mortem examination and disposal at a landfill site is commonly used in more populated regions; however, this often requires the landfill site obtains extra permissions for disposal. The transport of large specimen through

cities or populated areas can pose additional challenges and is recommended to be done in a closed container.

**INCINERATION:** Transport of remains after post mortem examination could also be disposed at a incineration company, which could be considered an environmental-conscious waste disposal solution.

**COMPOSTING/RENDERING:** There is increasing interest in composting stranded marine mammals, using a methodology similar to that employed for livestock carcasses. More information can be found on the general principles of this composting system at <http://compost.css.cornell.edu/naturalrenderingFS.pdf>. Note, however, that many countries prohibit the sale of products derived from cetaceans, and this can include compost or biodiesel from the rendering process (for more info see CITES: <https://cites.org/>). Thus, commercial plants may be reluctant to accept cetacean carcasses. Within such context, it should also be emphasised that, due to regulations enforced to minimize human and animal exposure risk to prions agents, e.g. the Bovine Spongiform Encephalopathy (BSE) causative agent, meat and bone meal derived from any species (both mammalian and avian) may not be used for animal feeding.

## Evaluation of the carcass

### External Features

The degree of autolysis of internal organs cannot be reliably evaluated from outward appearance or estimated from the time since death. The rate of decomposition is influenced by a number of intrinsic and external factors, for example body temperature (animals can be hyperthermic from infection or strenuous muscle activity during live stranding), blubber thickness and external sea or air temperature. Due to a higher surface area to volume ratio smaller, thin carcasses cool quicker than larger, rotund carcasses.

Toothed whales may initially sink at death and start to float days or weeks later when buoyed by decomposition. At the other extreme, seagulls, terrestrial and marine predators may begin gouging the eyes and penetrating the skin and blubber of the jaw and body openings of a living dolphin, perhaps already mutilated by shells and rocks during stranding. By the time the animal dies, the carcass may already appear to be affected.

Skin, eyes, and exposed mucous membrane dehydration should not be considered a reliable indicator of time since death as tissues retain their vital appearance longer in water

or with humidity or precipitation. Submerged areas of floating carcasses are often better preserved than those exposed to sun and air. Sun exposure, particularly of dark regions of skin can dramatically increase decomposition rate and cause liquefaction of the blubber layer. Bloating is generally a sign of decomposition, though some disease conditions such as “gas and fat embolic syndrome”, or clostridiosis, etc. may be characterised by gas presence and/or production in tissues. Tell-tale signs of decomposition include a protruding tongue and penis. A reliable assessment of the state of decomposition is usually only through internal examination of tissues and organs.

## Internal Features

The blubber of a fresh carcass is firm, white-cream in colour and, depending on the species and body condition, can exude oil on cut section. Post mortem change can lead to becoming tinged with blood (imbibition) from underlying tissues. Eventually, the oil begins to separate (delipidation) pool and leach from the carcass, leaving behind a matrix of connective tissue fibres.

Fresh cetacean muscle is darker than most terrestrial mammals, ranging from dark red to almost black in colour in mature deep diving species. Foetuses and young calves have paler musculature. Muscle is firm with clearly distinguishable bundles and easily separated. With decomposition the muscles become softer, lighten almost to being translucent and loss of bundle structure.

The rate of decomposition of an internal organ is related to a range of factors, including temperature, infection, the amount and arrangement of connective tissue, and proteolytic enzyme content. Antemortem hyperthermia, open wounds and bacterial sepsis will all increase the apparent rate of decomposition. Since blood tends to promote the process, decomposition is delayed in animals that exsanguinate prior to death.

Decomposition may not occur homogeneously throughout the carcass. Organs most susceptible to the effects of autolysis include pancreas, brain, spinal cord, liver and thyroid glands.

## Carcass Decomposition Classification

Despite uncertainties inherent in determining the stage of decomposition, carcass quality is an important determinant in subsequent analyses. Carcasses are assigned to one of five decomposition condition categories (DCC), determined by specific characteristics, as specified below.

Estimating the rate of decomposition and hence DCC can vary considerably between individuals, species and the factors listed above. To facilitate assessment, the following descriptors can be used to guide the appointment of a DCC. Note, however, that DCC could also be heterogenic across the body, (e.g. when predation or scavenging has exposed one visceral cavity but the other is intact. It is recommended to describe this in the post mortem report and use a category that reflects the average body DCC.

### **CODE 1: Extremely fresh carcass, just dead**

Characteristics: Usually live stranded and died/ euthanized cases or those stranded right after death; exhibiting no post mortem changes (e.g. no bloating or sloughing of skin); fresh smell; clear, glassy eyes; blubber firm and white; muscles firm, dark red, well-defined; viscera intact and well-defined; GIT contains no to little gas (unless pathologic); brain firm with no discolouration, surface features distinct, easily removed intact.

### **CODE 2: Fresh carcass**

Characteristics: Normal appearance, fresh smell, minimal drying and wrinkling of skin, eyes and mucous membranes; carcass not bloated, tongue and penis not protruded; blubber firm and white, occasionally tinged with blood.

### **CODE 3: Moderate decomposition.**

Characteristics: Bloating evident, with tongue and penis often distended; skin cracked and started sloughing; characteristic (mild) odour can be expected; mucous membranes dry, eyes sunken. Blubber blood-tinged and oily; muscles are softer and poorly defined; gut segments contain gas; brain has soft consistency. Organs are largely intact, still distinguishable and can be easily removed and assessed, although colour is more uniform throughout thoracic and abdominal cavity and consistency, particularly kidneys and pancreas is soft and increasingly friable.

### **CODE 4: Advanced decomposition**

Characteristics: Carcass may be intact, but collapsed; skin sloughing; epidermis may be largely missing, exposing underlying blubber. Strong odour; blubber soft, often with pockets of gas and pooled oil; muscles nearly liquefied and easily torn, effortless separation from the bones; blood thin and black; viscera often identifiable but friable, easily torn, and difficult to dissect; gut gas-filled; brain liquified, dark red, containing gas pockets, with decreased consistency.

## CODE 5: Mummified or skeletal remains

Characteristics: Skin may be draped over skeletal remains; any remaining tissues are desiccated. Organs partially or totally disappeared, or if present not completely identifiable.

Example pictures that show carcasses in the different DCCs can be found in the Annex 1.

### Description and photographs

As stated above, procedures for dissecting and examining carcasses depend on many factors: the animals' size and species, expertise, skill and time of the investigating team and any limits imposed by logistical, social, political and economic considerations. Consequently, the following section is organised in a multi-level approach considering these aspects.

The following aspects should be recorded regardless of the expertise of the investigator. Detailed descriptions in plain language are acceptable- inexperienced teams should not worry about using the detailed pathological terms described below. Alongside photographic images these descriptions are key to describing and illustrating any abnormality and maximize the information which can be subsequently shared with skilled professionals, such as veterinary pathologists with experience in marine mammal medicine.

**Distribution and location**: note the anatomical region, organ and/or tissue involved. Report if the abnormality is bilateral or unilateral, diffuse, focal, multifocal or multiple, patchy;

**Size**: measure and scale any finding and/or compare with commonly known objects if a ruler is not available. In order to evaluate if any organ or body part dimension is increased or decreased compared to normal, the assessing person should be experienced in this species.

**Shape**: bi-dimensional or tri-dimensional description of the lesion(s) (circular, oblong, spheroid, ovoid, target-like, wedge-shaped, irregular, papillary, pedunculated, sessile, villous);

**Margins**: note the edges of lesions ( indistinct, infiltrative, papillary, pedunculated, serpiginous, serrated, sessile, villous, well-demarcated);

**Surface**: describe the surface of the organ or lesion (bulging, cobblestoned, corrugated, crusted, eroded, granular, pitted, rough, smooth, striated, ulcerated, umbilicated, verrucous);

**Colour:** note the colour of any change. Usual colours in a carcass could be: black, brown, grey-green, mahogany, red, tan, white, yellow;

**Consistency:** note any changes compared to normal features of the tissue and/or organ of interest. Consistency cannot be evaluated by simply observing the organ/tissue, but should be done by palpating and comparing with known materials.

### Effects of decomposition code on investigative tests

The recommended suite of tissue sampling for subsequent analysis depends on the carcass DCC and is summarised in Table 1. See tissue sampling and storage section for collection information and further procedures. Decisions upon sample collection will differ, depending upon the analyses planned, laboratories involved or research questions posed. Table 1 should therefore be seen as guidelines and not a proscriptive protocol.

**Table 1 below: Recommendation for tissue sampling considering carcass DCC. Shading: green ✓ indicates the process is of potential use in carcasses of the indicated DCC; grey (✓) indicates that there may be limitations and red ✗ indicates the procedure is not recommended/very unreliable, due to post mortem autolysis.**

Analytical procedure	D	D	D	D	D	Comments/recommendations
	C	C	C	C	C	
	1	2	3	4	5	
Genetics	✓	✓	✓	✓	✓	For DCC4 or 5: paleopathological procedures may be required on account of degraded DNA (eg extracting DNA from bone medulla)
Diet and marine debris	✓	✓	✓	✓	(✓)	If GIT is not intact, eg from post mortem scavenger damage, results are compromised
Age determination	✓	✓	✓	✓	(✓)	
Fatty acids and stable isotopes	✓	✓	✓	✓	(✓)	Depending on analysis planned
Parasitology	✓	✓	✓	✓	(✓)	Depending on analysis planned
Morphometrics	✓	✓	✓	(✓)	(✓)	Girth measurements can be disrupted by bloating due to autolysis in DCC4-5
Gross pathology	✓	✓	✓	(✓)	(✓)	Recommended for DCC4-5 in cases of forensic investigation
Reproductive studies	✓	✓	✓	(✓)	✗	
Toxicology	✓	✓	✓	(✓)	✗	Depending on pollutants. DCC1-2 for biomarker investigation.
Ear investigation	✓	✓	✓	✗	✗	Inner ear analysis specifically: DCC1, histopathology of fixed ears possible up to DCC3
Microbiology	✓	✓	(✓)	(✓)	✗	Depending on analysis planned. For DCC3-4 microbiology can still be worthwhile for detection of certain bacteria and fungi using specific culture methods. Should a septicaemia be suspected in DCC3-4 animals, then microbiological investigations should be undertaken on the kidney, as this is resilient to microbial post mortem invasion using specific culture methods.
Histopathology	✓	✓	(✓)	(✓)	✗	Recommended for DCC4-5 in cases of forensic investigation
Virology	✓	✓	(✓)	✗	✗	Depending on analyses planned.
Biotoxins	✓	✓	(✓)	✗	✗	
Gas bubble analysis	✓	✓	✗	✗	✗	If this procedure is conducted: it should be done first, before undertaking further assessments and dissections, particularly prior opening any part of the vascular system or removing the head.
Serology	✓	(✓)	(✓)	✗	✗	Advisable both on blood serum and on cerebro-spinal fluid, the latter of which should be collected as soon as possible. In heavily autolyzed specimens, alternatives are "juice" obtained from skeletal muscle or lung, vitreous humour or pericardial fluid



Clinical chemistry	✓	✗	✗	✗	✗	Vitreous humour is a possible option in decomposed cases . Care is needed however to ensure sufficient baseline data are available for the analyte in the species under investigation.
--------------------	---	---	---	---	---	--

## Tier One: Basic morphometrics, external examination and basic tissue sampling

### Data collection and photographs

Scientific value is optimised by careful documentation of systematically collected data and use of non-ambiguous terminology. The use of standardised data sheets and forms is recommended for field work. In addition to written observations, photographic and video records of carcasses and the surrounding environment can capture important details such as the pattern of a mass stranding, traces of predators/scavengers and any markings, scars or injuries which would disappear soon after death or following carcass removal. In cases where there are no evident marks, it is still important to take photographs as soon as possible following arrival on site. Digital pictures and videos can be extremely important in evaluating human interaction. When photographing/filming wounds suspected to have been caused by propellers, images should be taken with the objective placed perpendicular to the axis of the lesions' surface.

Images support the descriptions of the post mortem report and, in tier three investigations, aid the pathologist in identifying the sampling area and to connect macroscopic observations with microscopic evidence. Photographic documentation should include a general body overview and detailed pictures of main distinctive features. As a minimum, it is recommended to take lateral overviews of the whole body (both sides), genital slit region, the head with exposed teeth or baleen, and a cranio-caudal 'skyline' image outlining the silhouette of the epaxial muscles. For those species included in photo-ID catalogues, additional pictures of identifying characteristics (e.g. of colour patterns and dorsal fin or fluke) should be taken. Rare species or specimens are especially valuable and require extra measurements to ensure a complete body of data. The entire carcass removal to a suitable laboratory or museum for study or preservation should be attempted.

It is recommended to present a case label and ruler/scale bar in images. The label should (ideally) include the animal identification number, the date of the stranding, the species and investigating organization together with detail of the lesion/body part. When taking close-ups, images should also be taken from a wider angle to allow a viewer to contextualise the image. Care should be taken to minimise shadows, reflections and glare

and exclude fingers or instruments from the shot. The ruler or label should not occlude important areas. Particularly noteworthy lesions or features should also be photographed without any scale or label for potential publication. If the tissue or organ have been removed from the carcass it is good practice to place on a absorbent background which minimises blood in the field of view.

Given the storage requirements of high-resolution digital media, it is advised to consider archiving to a secure location, e.g. cloud- based storage.

## Body measurements

Two principle measurements should be taken: total body length and girth. Measure the length by placing the animal on its belly (if possible), holding a measuring tape or ruler in a straight line next to the carcass parallel to the longitudinal body axis. Measuring the distance between the notch (if present) in the tail fluke and the tip of the rostrum (Figure 1). Measure the girth for DCC1-3 carcasses, in cm, by placing the measuring tape around the carcass immediately cranial to the dorsal fin without compressing the body. A second girth measurement may be taken at the level of the axilla, immediately caudal to the pectoral fin (Figure 1). If it is not possible to take an encircling measurement (e.g. if dealing with a large whale), take a half girth measurement and double it. Note if the carcass is bloated, incomplete or otherwise if measurements estimates may not be reliable.

To measure blubber thickness, incise the blubber dorsoventrally along the girth measurement line at the level of the cranial insertion of the dorsal fin. The blubber thickness is measured (in mm) at three locations: dorsal, lateral and ventral, as presented in Figure 1. Make sure to cut perpendicular to the surface of the skin. The epidermal thickness is not routinely measured. Additional measurements can be taken accordingly, see Annex 2 for a more extensive measurement collection, which could be applicable e.g. when dealing with rare species.

## Freezing carcasses prior to post mortem examination

In circumstances where there is no immediate capacity to undertake a post mortem investigation, freezing of the carcass is a possible alternative. Chilling the carcass at 0-4°C for up till 5-10 days (this accounts for small cetaceans) is preferable to freezing, due to artefacts unavoidably induced by the freeze-thaw process. Such artefacts can mask or obliterate indications of pathology hence freezing carcasses should only be employed when there is no possibility of examining the carcass fresh or storing it chilled. This should be clearly stated in the post mortem report.

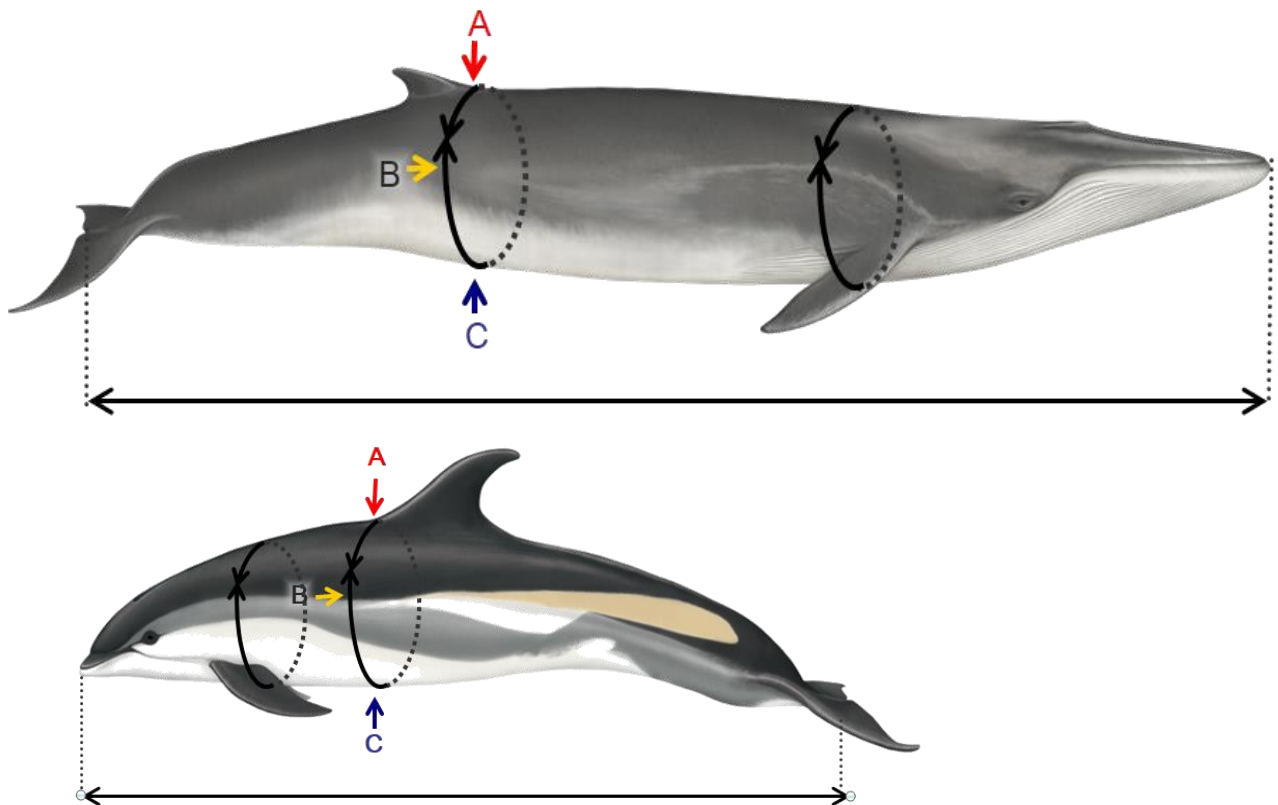


Figure 1: Images indicating the location of necessary measurements to be taken of stranded cetaceans, on the example of a fin whale (*Balaenoptera physalus*) and an Atlantic white sided dolphin (*Lagenorhynchus acutus*). The letters indicate the location of blubber thickness measurement sites, A (red) =dorsal, B (yellow) =lateral and C (blue) =ventral. Images: © CSIP/Lucy Molleson (top image) and WDC/Lucy Molleson (bottom image).

In addition to the measurements described, the complete carcasses should be weighed (in kg). It should be noted if the animal is not intact and an estimated weight is taken. If weighing is not possible, weight can be estimated by using total length. The table below summarizes an estimation based on the relationship between the two parameters (i.e. total length and weight) in three species of small cetaceans. Obviously during the estimation NCC and DCC should be considered since they could affect, often negatively, the estimate. For large whales, an estimated of body weight can also be obtained by weighting trucks at the carcass disposal taking into account liquid and tissue loss during the examination.

A more precise estimation could be obtained following Trites & Pauly (1998): “The functional relationship between the maximum body length of a given species,  $L_{max}$ , and the mean mass of all individuals in the population,  $M$ , is expressed as:  $M = a L_{max}^b$ ” where  $M$  is the **mass expressed in kg** and  $L$  is the **length in cm**. For  $a$  and  $b$  coefficients there is some variation between Odontocetes and Mysticetes and sex, as presented in the table below.

Family	Sex	a	b
Mysticetes	M	-7.347	2.329
	F	-7.503	2.347
Odontocetes	M	-8.702	2.382
	F	-9.003	2.432

$$\log_e M_{media} = a + b \log_e L_{max}$$

For sperm whales, the same linear regression has been proposed using the same parameters for Mysticetes but a dedicated formula has been developed by Lockyer (1991) due to their anatomic peculiarities ( $M = 0.218 \times L^{2.74}$ ).

## Tier Two: Post mortem investigations and sampling

*This section is modified from the document by Kuiken and García Hartmann (1993). For specific organ sample collection for histology or additional examinations, including microbiology, virology and parasitology, see the appropriate subsections later in this document.*

During a post mortem examination, all structures must be examined visually in situ, including the vascular system, by palpation and incising into organs. All findings must be recorded, including noting of ‘no abnormalities detected’ (NAD) and any organ systems not examined (NE). The presence and sampling of gas bubbles within the cardiovascular system should be carried out following specific protocols. Lesions in any organs should be described including the size, location, colour, texture, shape and margin and the nature of the transition from normal to abnormal tissue, i.e. how well or poorly demarcated the lesion is. A list of terminology that may be used for description of changes can be found above. Assessment of features allow an objective description of the observed changes compared

to normal anatomical conditions. In case of inexperienced personnel, this approach is quite simple and along with pictures taken during examination, it could allow advice of skilled experts.

Photographs of lesions should be taken with a ruler or scale bar as mentioned above. Representative tissue samples should be placed into fixatives (e.g. 10% neutral buffered formalin, the most commonly and widely used fixative) for histological examination, ensuring inclusion of the transition from normal to abnormal tissue and also include tissue samples with no gross lesions. Samples should be collected for additional testing and stored appropriately according to the suspected aetiology of any lesion.

Procedures for dissecting and examining carcasses depend on the size and species, but it is recommended to follow the outlines as reported below. Firstly, procedures as described in tier one should be conducted. Tier two can be seen as a follow-up process and outlines are summarised below. Gas examination (and possible subsequent sampling, DCC1-2) and ears collection (for inner ear analysis, DCC1), as well as samples for microbiological and virological analyses need to be taken as early as possible to avoid artefacts due to sectioning, decomposition or contamination and microbial genome degradation by proteolysis. Furthermore, the brain (and, more in general, the central nervous system), the ears, the pancreas, the thyroid gland and the liver should be fixed in 10% neutral buffered formalin as soon as possible for histopathological investigations, due to the rapid post mortem autolysis affecting these tissues. Care should be taken to prevent cross-contamination with enteric micro-organisms. Examination of the gastrointestinal tract should therefore be performed last, unless there is gross pathology in the GIT, when it is recommended to remove in its entirety and investigate on a separate table or area so that samples can be taken as soon as possible.

## External examination

Photographs, body measurements and carcass condition/state of decomposition are taken as described in Tier One. Examine the animal for external lesions (including signs of intra- and inter- species interactions, as well as anthropogenic interactions), taking note of any penetrating wound, and ectoparasites and sample appropriately. Ectoparasites are most likely to be found in or near the body openings (including wounds), in crevices or adjacent to and on the fins and flukes. Take a 2 cm<sup>2</sup> piece of full thickness skin, where possible excluding the blubber layer, and/or muscle for DNA studies. Further samples for skin, blubber and muscles can be obtained for several post mortem examinations as ecotoxicological studies, histopathology and stable isotopes analyses. Table 2 and 3 in the

paragraph for sampling procedures will detail more deeply the possible analyses and samples conservation.

Examine the oral cavity (including teeth or baleen, tongue, gingiva and lymphatic tissue), the eyes (for bubbles, evidence of intraocular haemorrhage, asymmetry or swelling), blowhole, anus, genital slit and mammary slits (when present) for lesions, discolorations and discharges. Press the skin in the area cranial to the mammary slits in a caudal direction to express any content present in the mammary glands. If liquid can be extruded take a sample for other analyses such as toxicology (see sampling procedures). Record the volume, colour and consistency of liquid. Any abnormalities should also be sampled to identify aetiological agents.

### Nutritional condition state

Assessing the body condition state is an important metric as it provides an indicator for the ante mortem health of the animal. It should be judged based on the blubber thickness, lipid composition and back muscle mass. The physiological blubber thickness is difficult to assess in isolation as it is naturally influenced by a range of factors, including species, season, region, sex, age, reproductive status and environmental temperature. An emaciated animal, however, will have lost both fat reserves and muscle mass; this is most notable in the blubber and lumbar muscles dorsal to the spine. To judge an abnormal blubber thickness, experience in assessment of the species in relation to its environment is needed as blubber thickness is physiologically varying strongly according to season, age and sex. In addition, percentages of lipids can be measured in the blubber layer and could be an informative descriptor of nutritional condition in fresh cases (DCC1-2).

Based on the state of blubber and skeletal muscle the NCC can be characterised as:

**Very good:** the animal's outlining on a cranial perspective is convex; round appearance caudal to the skull and lateral to the dorsal fin visible; subcutaneous-, pleural and other visceral fat present; blubber layers are thick.

**Good:** the animal's outlining on a cranial perspective is convex; no hollow appearance caudal to the skull and lateral to the dorsal fin visible; possibly some subcutaneous-, pleural and other visceral fat present.

**Suboptimal:** the animal's outline on a cranial perspective is not fully round; a slight hollow appearance caudal to the skull and lateral to the dorsal fin is visible (slightly hollow or almost flat); no internal fat is observed.

**Poor:** the animal's outline on a cranial perspective shows moderate concavity, and outline of lateral aspects of the vertebrae; a hollow appearance caudal to the skull and lateral to the dorsal fin is visible; scapula's can be observed sticking out.

**Emaciated:** the animal's outlining on a cranial perspective is very concave and the lateral aspects of the vertebrae are easily palpable; an extremely hollow appearance caudal to the skull and lateral to the dorsal fin is visible; scapula can be observed sticking out; blubber layers are minimal (in small odontocetes <1 cm).

It is recommended to assess NCC for cases in DCC1-3. Post mortem changes will hamper reliable assessment of nutritional condition in cases in DCC4-5.

### Subcutaneous examination

Measure the blubber thickness (as described in Tier one). Record the colour of the blubber (e.g. white, yellow, pink). Pay attention to the melon and the acoustic fat bodies externally and internally to the lower jaw. Make multiple incisions into the tissue to check for haemorrhages. Take samples of blubber and muscle (see sampling procedures).

If possible, position the animal in right lateral recumbency; make a mid-line ventral incision from the symphysis of the mandible to a short distance posterior of the anus circumventing the umbilical region, genital slit and anus. From the posterior end of this ventral incision, make a second incision almost to the dorsal mid-line. Using the line of weakness between tissue planes, separate skin and blubber from the underlying muscle to remove the integument from the upper side. Stripping of the blubber layer can also be done strip by strip in larger animals. During this phase, pay attention to the subcutaneous veins in order to detect and quantify any evidences of gas bubbles according to specific protocols (Bernaldo de Quirós et al. 2012). Examine the blubber layer as extensive as possible by cutting strips and note the colour, presence of any discoloration (e.g. haemorrhages). The presence of any parasites or lesions in the blubber should be recorded and a representative sample should be collected (see sampling procedures). Cestoda parasites may appear as white cysts of less than 1 cm in diameter, often in the ano-genital region or the dorsal aspect of the chest wall; nematodes may also be found in the subcutaneous tissue as a result of larval migration patterns. Also examine the subcutaneous tissue for the presence of bruises and haemorrhages, oedema and/or hyperaemia and different discoloration.



Locate the pre-scapular lymph node, cranial to the pectoral fin, and sample for histopathology as well as for virology and other microbiological investigations.

In females, incise the mammary gland and record the presence of liquid, parasites or gross lesions and collect/sample these.

The following section describes the key points to note whilst undertaking a post mortem investigation for cetaceans examined in right lateral recumbency, i.e. by removing the left flank wall. It is possible that protocols will be adjusted during post mortem examination depending on circumstances or findings, so the following is intended to serve as a recommendation and *aide-memoire* to existing protocols.

### Visualisation of internal organs

When opening the body cavities, note any abnormal liquid or lesions and make sure that such are carefully assessed to be able to establish the origin/aetiology. The anatomical position of the organs should be verified, paying attention to any displacement, ruptures or herniation evident. Collect any free fluid in the thoracic and abdominal cavity.

Presence of gas bubbles (in particular in the thorax, mediastinum and peri-renal location) in the mesenteric veins and lumbo-sacral plexus should be evaluated and quantified according to specific protocols (Bernaldo de Quirós et al. 2012).

If possible open before the abdominal cavity prior to the thoracic cavity in order to observe the proper position of the diaphragm and assess the presence of gas in the chest (pneumothorax). After removing the left abdominal wall, and a gross evaluation of pre-existing punctures to the thoracic wall, physiological negative pressure can be confirmed by incising the diaphragm and observing a small caudal displacement accompanied by the sound of air influx. Collect any free fluid in the thoracic and abdominal cavity for cytology and microbiology. Collect a representative sample of any parasites (e.g. cysts in abdominal wall or under the peritoneum).

### Examination of abdominal organs (except GIT)

Care should be taken to avoid contamination of the carcass with gastro-intestinal tract (GIT) contents: preferably by tying off the oesophagus and rectum to prevent leakage of content and removing the stomachs, mesenteric lymph nodes with intestines, pancreas and spleen. **Pancreas** should be removed, macroscopically examined, checked for parasites, and fixed in 10% neutral buffered formalin as soon as possible due to rapid decomposition (chemical/enzymatic post mortem autolysis). Assess the **spleen** and

sample splenic tissue for any microbiological and virological examination. Note any accessory spleens and presence of any gas bubbles in the mesenteric vasculature or spleen. Examination of the GIT can be left to the end of the post mortem examination or perform it in a completely separate area to prevent contamination of other tissues with the enteric microbiota. Sample spleen for microbiology, virology and histopathology.

Examine the **urinary bladder** in situ, and sample any urine present with a syringe, noting the volume, colour, turbidity and nature of any contents present. This sample could be useful for microbiology. Freeze urine for biotoxins examination at -20°C. If uroliths are detected these can be frozen at -20°C prior to analysis.

In females, remove the entire **reproductive tract** and open the vagina and uterus examining and sampling any stones, mucosal alternation or discharge. The reproductive history of cetaceans can be informed by analysis of ovarian tissue. Record the presence of any *corpora lutea* and/or *albicantia* or follicles on each ovary and then store the ovaries in 10% neutral buffered formalin, with some transverse incisions to allow proper fixation. If unfamiliar with the techniques to assess ovarian scarring, assessment of scars can be done at a later stage. Ensure to differentiate left from right ovary during fixation, e.g. by making a small transvers incision in one side. Additional sampling of the reproductive tract of females for histology and microbiology should be conducted when abnormalities are observed.

In males, remove the testes, check for symmetry and weigh them, noting if epididymal tissue is included in the weight, and measure the long axis length. Testes size is correlated to sexual maturity and activity. Make cross-sectional incisions at 1 cm intervals to examine. Store the testes appropriately for reproductive studies. Examine the genital opening, penis, epididymis and accessory glands. Additional sampling for histology, virology and microbiology should be conducted if abnormalities are observed.

In pregnant females, where the **foetus** can be easily palpated, photograph the uterus with a scalebar in the frame or measure the uterus. Note which uterine horn carries the foetus and the foetal position to identify possible dystocia. Note if the cervix is dilated. Describe the consistency and turbidity of the amniotic fluid and sample it for microbiological analysis if required. Twins are very unusual. When the foetus is of sufficient size to examine the individual organs, a post mortem and tissue sampling (especially including for toxicological and virological tests) should be performed. Foetal stomach contents may be collected for bacteriological culture. If the foetus is too small for a full post mortem examination, the whole foetus and its placenta can be collected for histology, or frozen for virology,

microbiology and toxicology, or fixed and kept as a museum collection. Always note the sex, weight, length and if the DCC of the foetus more advanced than the dam.

Remove and examine the **adrenal glands**, make a transverse section and measure the cortico:medulla ratio directly or photograph the cross section through the mid-adrenal gland with an appropriate scale bar. Collect a cross-sectional slice approximately 0,5 cm thick of the centre of both adrenal glands for histological examination. Slice and investigate the adrenal glands for presence of cysts, nodules and/or other abnormalities.

Before removing the **kidneys** from the body cavity look for any anomalous **gas evidence** around them in the perirenal space and in the associated vasculature. Remove them from the body and incise the kidneys longitudinally and check for parasites in the renal vasculature. Sample 1 cm<sup>3</sup> of tissue from each kidney for histological examination (if no gross lesions), ensuring to collect at least one entire renule, and for toxicology and microbiology. Further samples should be obtain fresh or frozen for microbiology and contaminants. Assess the urethra for any abnormalities and sample as appropriate.

Remove the **liver**, examine all surfaces and make multiple incisions into the parenchyma. Record the colour and consistency and distribution of any abnormalities Record any nodules and other abnormalities. Examine the bile ducts for abnormalities and parasites (note that cetaceans do not have a gall bladder). Take frozen samples for ecotoxicological examination, virology, microbiology, parasitology and stable isotopes analyses. Sample for histopathology from two regions of the liver and from any gross lesions.

## Examination of GIT

In order to avoid any possible contamination from the GIT content tie up both ends before extracting it from the abdominal cavity. If micro- and/or nano-plastic studies are considered, reduce possible environmental contamination through particulates in the air, tools, clothes or other plastic objects. Consider possible sampling for microbiology as first step that should be carried out as soon as possible before any other procedure.

Locate and examine the **mesenteric lymph nodes** and sample a 0,5 cm thick cross-sectional slice from halfway along its length for histological examination.

Separate the **stomachs** from the intestine by ligating the GIT after the ampulla duodenalis. Note that cetaceans generally have three stomach compartments, but there is species-specific variation in compartment numbers. In general, the following three compartments are present: the forestomach (cardiac), the main stomach (fundic or glandular) and the pyloric stomach.

Record the presence and amount of any ingested prey species, digesta, otoliths (these can be stored frozen), and parasites. Take note of evidences of marine litter by recording and weighting the presence and type of any macro-plastics or other ingested marine debris in the stomachs and retain for future studies. A better evaluation for marine litter ingestion should be carried out by washing gastric surface and stomach contents using proper mesh size that can help in separating diet and parasites from foreign bodies. A size of at least 1 mm is recommended in order to separate macro and meso-plastic which be later classified using the MSFD master list (TC D10 MSFD, 2019). Any macroparasite should be also recorded and a representative sample should be collected from each stomach compartment. Describe any gross lesions, including the distribution and size of any ulcerations for each separate stomach compartment. Ideally the fluid resulting from the washing should be preserved to be further filtered using meshes till at least of minimum 500 µm size for diet studies, 250 µm for marine litter and adult parasites (DCC 1-3).

Open the **intestine** throughout the entire length. Check for lesions, foreign bodies and/or parasite presence, and record and sample these. Note the colour and consistency of the content. In very fresh cases, samples of intestinal content could be taken for microbiota/microbiome studies otherwise it should be analyzed as the stomach for marine litter and parasitological examination. A sample of stomach contents and faecal material could be collected for parasitological studies and algal biotoxins. Several section of intestinal should be opened and fixed in formalin

If GIT examination cannot be undertaken immediately, collect the entire GIT (including all content, like fish bones, otoliths and all other food or non-food remains for additional studies into prey and/or marine debris ingestion) and freeze at -20°C for subsequent gross pathology, diet, parasitology, debris and biotoxins analysis. Specific protocols exist for the collection of samples for micro- and nano-plastic ingestions.

### Examination of neck region, and thoracic organs

As stated above, before opening the thorax, asses the presence of negative pressure in the chest. Open it by cutting the ribs and check for possible bones fractures. Locate the **larynx** and note its position. Check for foreign bodies in the oral cavity. Note the presence and colour of any foam and/or obstruction (e.g. foreign bodies). Free the larynx from the sphincter muscle that holds it in place, and, whilst pulling the tongue caudally incise along the neck and free the trachea. Check for foreign bodies in the **tracheal lumen**. Free the heart and lungs from the thoracic cavity checking for adhesions between lungs and

thoracic wall/diaphragm and the presence of any anomalous **gas** presence in the mediastinum or in the visceral pleura (bubbles). Note and sample any free fluids in the **pericardial sac** and **thoracic cavity**. Pericardial, pulmonary and muscle fluids can be used as a substitute for serum: for cases in moderate decomposition condition or when serum cannot be sampled, collect fluid from the pericardial sac prior to opening the pericardial sac, e.g. using a syringe, avoiding contamination with blood. Fluid from lungs can also be collected.

Examine the **ribcage** for fractures or bruising and, ventral to the thoracic spine, the **rete mirabilis** for evidence of haemorrhage.

Examine the surface of the **tongue**. Note the presence of neonatal papillae and incise into the tongue muscle for examination. Examine the lymphatic tissue of the tonsillar ring and sample any abnormalities for histology.

Open the **oesophagus** longitudinally and check for lesions, foreign bodies, food remains and/or parasite presence; record and collect these. Examine and fix the **thyroid** for histology and freeze a section if required.

Open the larynx, trachea and major bronchi longitudinally and check and record for lesions, foreign bodies, including sand silt or mud, foam, fluid, aspirated ingesta. Observe and sample for histology and virology the tonsils at the passage between the larynx and trachea.

Note any profound **asymmetry** in the size or congestion between either lung. Make multiple incisions into the parenchyma of both **lungs**. Note level and distribution of any parasite burden in pulmonary parenchyma and take a representative sample. Collect swabs for microbiology from any evident pathological changes. A minimum of two pieces of each lung, one from the hilus (tracheal bifurcation) and one from near the surface including pleura should be taken for histological examination. Care should be taken to ensure buoyant samples are fully immersed in formalin, for example by placing tissue paper on the surface. The samples should include part of the major bronchial tree. Further frozen samples should be collected for ecotoxicological examinations (i.e. biomarkers and/or contaminants), virology and microbiology. For neonates, small pieces of lung can be dropped in water to test floatation to determine if the lungs ever inflated

Open all major branches of the pulmonary blood vessels and examine and record the presence of parasites. Examine the bronchial and pulmonary associated lymph nodes. The latter can be found approximately halfway along the ventral edge of each lung. Cut a

1 cm thick cross-sectional central slice of the left pulmonary associated lymph node, including a small amount of the adjacent lung tissue attached, for histological examination, microbiology and virology.

Examine the structure and extent of the **thymus** and sample as required. Age-related thymic atrophy is normal but histopathological assessment can be useful to assess potential immunotoxic pollutant-related or any other pathology. Note the relative degree of atrophy and whether any cysts are present.

Collect any blood present in the heart ventricles (or elsewhere) and centrifuge at 1,000-1,500 rounds/8-10 minutes for sero-epidemiological and/or virological investigations. With advanced time after death or the freezing process will make it difficult to obtain serum. Nevertheless, it is very important to collect and archive blood for different purposes (incl. toxicology, parasitology, algae toxicology, PCR).

Before separating the **heart** from the lungs, check the heart for any evident gross malformation and for **gas bubbles** within the coronary veins and score them; then cut through the major blood vessels at the base of the heart. Examine the myocardium by cutting into the right and left papillary muscles and the septal myocardium. Check for evidence of petechial haemorrhages in the epicardium and myocardium. Open the left and right ventricles, atria and thoracic aorta for examination and record and collect a representative sample of any parasites present. Check to ensure no defects/ holes in the septum. Rinse the heart and weigh it. Sample heart tissue and include a piece of both ventricle walls and atrioventricular septum, including papillary muscles, for histological examination. Record any gross defects and then sample for histological examination. In case of neonates, assess whether there are any abnormalities in the foetal/neonatal cardiac anatomy (e.g. *foramen ovale*, patent *ductus arteriosus*).

In case an animal's total body weight could not be established, methodologies based on the relationship between the heart weight and total body weight can be used to get an estimation:  $\log W = (\log H + 2.2) / 0.984$ , with H = heart weight and W = body weight, both in kg (see: Brody 1945).

Examine the lumen and walls of **veins and arteries** looking for thrombi and parasitic infections, in particular in fin and beaked whales, or other lesions. If necessary sample them for further investigations. Remember to look for **gas bubbles** and to score them according to the previously cited protocol.

## Examination of the head

The eyes should be examined (check for hyphema) and collected (histology) with optical nerve attached.

Each ear bone should be removed carefully as soon as possible. Note any signs of bleeding or trauma in the surrounding tissue and external ear canal. Examine the **ear** sinuses, the Eustachian tube, the nasal sacs and sinus cavities. After ear extraction and parasite collection, rinse each ear cavity with water to assess the severity of the parasitic burden. Use forceps to collect a representative sample of any parasites present. In carcasses in DCC1-3, ears (tympano-periotic complex) should be removed for examination of infectious diseases, degenerative and traumatic changes and further microbiological, parasitological, virological and histological investigations of the middle and inner ear as well as surrounding tissue should be conducted to allow further understanding of the health of the ear apparatus as well aetiology of lesions.. With electron microscopy (EM) and immunofluorescence techniques, DCC1 inner ears can be assessed for potential degeneration and death of hair cells and associated innervation, especially in relation to acoustic trauma. The inner ear should be fixed following these steps by order:

- 1) removal of the stapes by tissue forceps,
- 2) Perforation of the round and oval window membranes with a needle
- 3) Slow perfusion of fixative into the structures of the inner ear (10% neutral buffered formalin or 4% paraformaldehyde, pH 7-7.4) with minimal pressure through one window until the fixative seeps through the other window, using a soft catheter (or the tip of a plastic pipette) and a 1ml syringe.

See more details on the perfusion protocol in Morell and André (2009) and Raverty et al. (2018). Then, the ears should be immersed in the fixative solution. Whilst unsuitable for ultrastructure imaging, the ears of carcasses in DCC2-3 should also be collected for histological assessment to investigate hearing damage.

Examine the **melon** through serial sections to assess any trauma and/or inflammatory lesions. Include upper airways assessing presence of foreign bodies, parasites or discharge. As already stated, look for any haemorrhages in the acoustic fat bodies (i.e. internal and external). For odontocetes, examine the **teeth**. Note tooth wear, integrity of dentition and state of gingiva, number and position of teeth. Remove at least 4 intact teeth (if present) from the middle of the lower jaw for age determination. Check for swelling and fractures in or around the jaws or other changes in the jaw articulations. For mysticetes,

examine the **baleens** for gross lesions, parasites and trauma, and collect up to six baleen plates ensuring each is removed as close to the gum line as possible. Teeth and baleen can be used for life history and stable isotope analysis either dried and stored at room temperature, or frozen, depending onto preferences of laboratories involved.

Sample the cerebrospinal fluid (CSF) before removing the head and opening the skull to examine the brain. In detail, remove the overlying soft tissue at the back of the head and neck, to gain access to the atlanto-occipital joint (foramen magnum). Then, to obtain a sample suitable for all type of analyses (microbiological, cytological, sero-epidemiological and biomolecular) flame the site using a butane torch for one or two seconds. It is suggested to use a syringe with a sterile needle of appropriate length (i.e. 1.3 x 88mm) or a sterile Pasteur pipette. Sample the spinal cord for histopathological, microbiological and biomolecular analyses.

Except for sperm whales, the skull can be opened by sawing a vertical cut parallel to the transverse dorsal ridge (visible and palpable on dorsum of the skull) paying attention to not cut the meningeal and cerebral tissues. Two further cuts should be made in the horizontal plane through the occipital condyles, making sure to leave the posterior portion of the condyles on the skull. Both cuts should be extended until they meet each other. The separated piece of skull can then be removed using a chisel, flat bladed screwdriver and/or a 'skull cracker'. Care should be taken to avoid human exposure to aerosols during this process.

Remove the **brain** from the skull and make an incision through the brain and check for ventricular dilation. Note the colour and turbidity of any CSF and the structure of the choroid plexuses. Cut the whole brain longitudinally by means of a sagittal, paramedian section, thereby collecting the smallest portion for virological, microbiological and ecotoxicological investigations examinations and the largest portion of it for histopathological examination (Annex 3). For neuroanatomical studies, place the remaining whole brain, including the pituitary gland which can be found caudoventrally to the optic chiasm within the cranium. Once fixed in 10% buffered formalin, make multiple slices into the brain tissue. The sampled brain should be processed using large tissue cassettes (if available), to allow full lesion profiling throughout the sample. Skulls can be retained for morphometric studies.



## Examination of the skeletal system and rete mirabilis

A representative sample of different muscle locations and diaphragm should be taken for histology, toxicology, parasitology etc. All bones should be investigated macroscopically for changes (e.g. fractures, inflammations, degenerations). Samples from humerus, lumbal vertebrates, ribs and lesions should be preserved for histology and infectious investigations as well toxicology (frozen or formalin for histology). Humerus could be also retain for diatoms investigations (Rubini et al., 2018) to support any diagnosis of drowning. Rete mirabilis should be taken for histology.

## Tissue sampling procedures, storage and analysis

### Morphometric studies and imaging

If the capacity exists, assessing carcasses by Computed Tomography (CT), DMX (bone density) and/or Magnetic Resonance Imaging (MRI) prior to post mortem examination will allow imaging and evaluation of a range of morphometrics and identification of potential pathologies. CT-scanning will allow visualisation of skeletal anatomy and lesions (e.g. trauma, shot injuries), assay bone density, assess joints and inter-vertebral discs. MRI allows the assessment of internal anatomy (including position of organs), all soft tissues and many potential pathologies. In addition, the collection and maceration of skeletal material, or the entire skeleton is of value for stable isotope analysis, morphometric studies or accession to museum collections. Definitive diagnosis of cause of death should however take preference over maintaining skeletal integrity for museum collections, and histology samples should be taken of any bone abnormalities that may be present in an animal.

### Tissue sampling and storage

The nature and storage requirements for samples taken for subsequent analysis depend on the requirements of the testing laboratory, and it is advised to check local requirements and protocols prior to sampling. As stated in Paragraph 5, national CITES permits should be assessed before collecting, preserving and exchanging tissues sampled from stranded cetaceans.

In general however, the following principles apply:

Swabs or tissues stored for subsequent microbiological/virological assay should be collected as soon as practical, as aseptically as possible and with an appropriate cold chain between sampling and testing. If it is not possible to perform microbiological analyses immediately, the use of an appropriate transport medium (depending on the pathogen) or freezing (in particular for virology) could be an option. Some viruses or bacteria could request specific sampling and/or preserving procedures.

Tissues for microscopic examinations should be fixed in 10% neutral buffered formalin. Possibly a commercial solution to ensure standardised quality (i.e. pH,

formalin concentration) should be used. If not available, characteristics of the preservative should be regularly checked. Samples should not be thicker than 1 cm and the ratio sample:formalin should be 1:10 and a plastic box with proper volume and dimension should be used. Formalin should be changed after 24 hours (especially for fatty tissues such as brain) and samples should be kept less than 72 hours in formalin for immunohistochemical analyses against infectious pathogens and/or selected tissue (bio)markers. Histological samples that can be processed are generally between 3-5mm thick.

Samples for subsequent assay for persistent organic pollutants should be wrapped in aluminium foil to prevent sample contamination from plastic in the storage containers. For heavy metals plastic bags could be used. Sampled tissues should then be frozen at -20 °C or colder.

Most samples destined for DNA molecular testing can be stored frozen or in 70% ethanol; however, samples collected for other genomic, metabolomics or proteomic work are likely to be more labile and require specific transport and storage media.

Tissues stored for cell culture in an appropriate medium (depending on the tissue) should be collected as soon as practical and as aseptically as possible, with appropriate conservation between sampling and testing.

A summary of the minimal samples set to be collected during cetaceans' post mortem investigations is included at the end of the document.

### Labelling of samples

Samples from each animal are examined by a number of people, often in different laboratories, under different conditions, and therefore it is vital that they are properly labelled for traceability, also taking into account long-lasting labelling and labelling in freezers (e.g. up to -80°C). This requires that:

Every animal should be assigned a unique reference number;

Every sample/ sample container should have a firmly attached label;

Permanent ink or pencil should be used to write labels;

Labels should include the unique reference number and tissue sample identifier.

It should be noted however that permanent ink could come off due to freezing/defrosting or when submerged in formalin. Overlying these with transparent tape may prevent this.

## Tissue and biological specimens' archive

To ensure availability of tissues for future studies, it is recommended to store samples in a sample archive. The creation of an official tissue bank for the stranding network is strongly recommended since it could preserve different tissues and fluid, and it could obtain CITES accreditation supporting exchanges of samples. An effective sample archive is very important when working with rare species, so that a larger sample size can be built up over time, but also as new pathogens may be detected in the future. With availability of a range of samples from multiple individuals and species, long-term medical, ecological and population studies can be facilitated.

It strongly depends upon the available facilities and request by the local laboratories conducting further analysis, but in general, all tissues and body fluids should be sampled and stored at  $-80^{\circ}\text{C}$  preferably and/ or at  $-20^{\circ}\text{C}$ . Formalin-fixed tissues should be stored for a limited period only in proper cabinets and paraffin embedding is highly recommended.

As a minimum, we recommend to sample at least: lung, liver and spleen for microbiological assessment (at  $-20^{\circ}\text{C}$ , or  $-80^{\circ}\text{C}$  or colder for ecotoxicology/biomarkers) and brain, lung, kidney and spleen for virology and microbiology ( $-80^{\circ}\text{C}$  or colder). Additionally, we recommend storage of blood and/or serum, CSF and other possible fluids collected at  $-80^{\circ}\text{C}$  (or colder) as a minimum.

## Age determination

**Teeth collection:** A longitudinal cross section through odontocete cetacean teeth reveals annual growth rings which can be used to determine age. To ensure all rings are visible on cross section, a minimum of four whole, undamaged or least worn teeth need to be collected from each individual for repeated estimates if necessary. Preferentially take the teeth from the middle of the lower jaw as these are usually the straightest and make age determination more accurate. From the harbour porpoise, teeth can be extracted easily by inserting a sharp knife or scalpel either side of the gums in-between the teeth and the connective tissue. In species such as the bottlenose dolphin, teeth can be loosened by initially levering the space between the tooth and the socket with a sharp pointed instrument. Dental elevators are useful tools for extracting teeth. If extracting of teeth is not possible, a piece of mandible containing at least 4 teeth should be collected. In baleen whales, age could be estimated analysing baleen plates or earplugs.

Storage: Loose teeth, jaw sections, baleen and earplug can be stored frozen. The temperature at which they are frozen is not critical. Alternatively, for short term storage, they can be fixed in 70% ethanol. They should not be stored dry as they may dehydrate which may lead to cracking of the teeth.

### Diet analysis, marine litter and micro- /nano-plastics

The best practice is to sample the entire GIT (unopened) from the oesophagus to the rectum, to ensure all content is collected. If this is not feasible the single parts (i.e. oesophagus, gastric chambers and intestine) could be separated maintaining them close by using strings or cable ties. The GIT is then placed on a non-plastic surface or grid for microbiological sampling, gross examination of ingesta and digesta, pathological changes, parasites and marine debris. Ingesta and digesta should as well as the GIT walls should be washed and filtered through different mesh size to separate macro and meso plastic (useful samples up to 1 mm, micro-plastic (up to 50  $\mu\text{m}$  if possible), diet (up to 500  $\mu\text{m}$ ) and parasites (up to 250  $\mu\text{m}$ ). The remaining fluid could be also preserved for nano-plastic investigations.

If not possible examining the GIT immediately, the whole GIT or single parts could be stored frozen closed for subsequent analysis for the presence of macro- and microplastics, dietary analysis and parasitology which can be undertaken concurrently. Samples for microplastic analysis may also require samples taken from the air, gloves, clothes, water pipes and all the other plastic materials used during sampling and analyses at the time of sampling to act as a negative control. The temperature at which the GIT is frozen is not critical.

Item characterisation: Material should be categorised as rope, net, floats, monofilament, braided line, hooks, packaging, cigarette butts, plastics, and other anthropogenic material. Size, shape (image analysis of digital photographs), mass, volume, and polymer type if plastic (e.g., Raman spectroscopy or Fourier transform infrared spectroscopy, FT-IR) should all be recorded, and all evidence should be identified as to source using established techniques.

Marine Litter will be later classified using the MSFD master list (TG D10 MSFD, 2019).

## Genomic (DNA) studies and RT-PCR ecotoxicological investigations

DNA is most readily recovered from skin or muscle even if other tissues could be used. These samples can be stored frozen at  $-20^{\circ}\text{C}$  or in 70% ethanol. Facilities permitting, storage of duplicate samples in RNAlater at  $-80^{\circ}\text{C}$  enables more advanced genetic sequencing techniques to be employed. Use RNAlater® Solution with fresh tissue only; do not freeze tissues before immersion in RNAlater® Solution. Before immersion in RNAlater® Solution, cut large tissue samples to  $\leq 0.5$  cm in any single dimension. Place the fresh tissue in 5–10 volumes of RNAlater® Solution. Most samples in RNAlater® Solution can be stored at room temperature for 1 week without compromising RNA quality, or at  $-20^{\circ}\text{C}$  or  $-80^{\circ}\text{C}$  indefinitely. Do not freeze samples in RNAlater® Solution immediately; at  $4^{\circ}\text{C}$  overnight (to allow the solution to thoroughly penetrate the tissue), remove supernatant, then move to  $-20^{\circ}\text{C}$  or  $-80^{\circ}\text{C}$  for long-term storage.

## Reproduction studies

**Female gonads:** Both ovaries should be placed, whole, in 10% neutral-buffered formalin or other fixatives if available or preferable. It is vital to differentiate between the left and the right ovary; this can be done by using separate containers, or, if storage does not allow this, by making a small incision in the left ovary before collecting them together in a container.

**Male gonads:** Each testis should be weighed separately after removal of the epididymis. Subsequently, place a cross-sectional slice approximately 1 cm thick from midway along the organ's length in 10% neutral-buffered formalin or other fixatives if available or preferable. Fix at ratio of 1 volume tissue: 10 volumes fixative and once fixed, after about 24 hours, the samples can be stored in a smaller volume of fixative.

## Histopathology and immunohistochemistry samples

**Collection:** In grossly normal organs take a random cross-sectional sample of 1 cm unless specified otherwise. Please note that samples that are processed for histology are generally 3-5mm thick. All gross lesions should be sampled to include an adjacent piece of normal tissue, if present. Always use a sharp scalpel to take the samples. Careful handling of tissues for histology is important to avoid squeeze artefacts, in particularly in soft and delicate tissues as brain, spinal cord, pancreas, lymphoid organs and GIT mucosa.

Individually labelled containers/permeable bags (e.g. tea bags) should be used to aid differentiation when multiple samples are taken from macro-microscopically similar organs (e.g. lymphoid tissues) and to be able to identify samples and lesions after fixation.

Fixation: 10% neutral-buffered formalin (4% of formaldehyde) is the most used fixative. Formalin is classified by the EU as a carcinogen and the necessary precautions to avoid direct contact and exposure must be taken. Other fixatives are now on the market to ensure human safety, but there is lack of experience in regards to their use for tissues examined by immunohistochemistry or in-situ hybridization. Formalin will only penetrate approximately 1 cm/day in any direction (tissue depending), so perfuse or slice samples no larger than 1-1.5 cm in diameter to avoid or slow down autolysis of the inner tissue portions. Use formalin at a ratio of 1 volume of tissue: 10 volumes of fixative. The tissues should remain in this fixative for a minimum of 24-48 hours (except the brain, see below) at room temperature. Longer time could affect immunohistochemical studies. If tissues have a high blood content, the fixative should be changed each 24 hours until it is no longer discoloured. Additionally it is recommended to inject formalin in eyes and intestine, to ensure proper fixation.

The brain should be placed in 10x as much formalin as tissue when fixing the largest portion of brain (see Annex 3), and should remain in this fluid for at least a week. To allow faster fixation, several transverse/coronal incisions should be made through the frontal lobes to expose the lateral ventricles. Another possibility is to freeze the brain for one hour to make easier coronal complete cuts of 1 cm; slices should be then separated by paper sheets and put in 10% neutral-buffered formalin. This facilitates a more rapid penetration of fixative into all brain areas. In really fresh cases, ensure that the brain has cooled to near room temperature prior to immersion in fixative to avoid artefacts such as dark neurons and contraction of arterioles.

Storage: Once fixation has taken place, the samples may be stored in a smaller volume of 10% neutral buffered formalin. If immunohistochemistry may be required, store tissues in 70% ethanol. If the time to processing is in excess of three months: change to formol saline at this point to avoid saponification. To minimise fixation artefacts it is recommended that neural tissue samples are processed within three months. Samples stored for years could limit diagnostic value of immunohistochemistry. Store the histology samples at room temperature and consider national legislation on workers safety related to the management and storage of formalin. If it is necessary to preserve formalin fixed samples for long periods, paraffin embedding is the better option.

## Microbiology

Sampling for microbiological diagnostics should be made in collaboration with the laboratory undertaking the processing of the samples. Preferably, microbiological examination should be carried out on a minimum of tissues including samples of lung, liver, spleen, kidney, brain, CSF and any gross lesions of suspected microbiological aetiology.

Collection: Ideally, samples should be taken using an aseptic technique whenever possible. Tissue samples (solid or liquid) or swabs, such as nylon flocked swabs, are both appropriate for microbiological examination. Each has advantages and disadvantages and the choice depends on the preference of the person performing the microbiological analysis and also the target microorganism(s) e.g. for the diagnosis of neurobrucellosis by *Brucella ceti*.

For a solid tissue sample, cut a block approximately 4x4x4 cm using a sterile scalpel and forceps and place this into a sterile container. Samples should be kept at 0-4°C until processed, which should be carried out preferably on the same day or at least within 24 hours after collection. If analysis is not possible <24 hours, samples could be frozen at -70°C, or preferable at -20 °C until further processed, to allow the subsequent growth of fastidious organisms.

For swabs, sear the surface of the organ (e.g. with a hot blade), then incise with a sterile scalpel and place a sterile swab into the incision without contaminating it with surrounding tissue. Then, directly apply the sample onto culture medium or insert the swab into a tube containing transport medium and store at 4°C until processing. Swabs should be processed within 24 hours. If this is not possible, samples of solid tissue are preferred.

For diagnosis of neurobrucellosis by *Brucella ceti*, CSF is the sample of choice, collected aseptically with a syringe with a sterile needle of appropriate length (i.e. 1.3 x 88mm) or a sterile Pasteur pipette..

Processing: This should be undertaken after consultation with the pathologist/microbiologist, as different media and methods are employed dependant on the suspected target microorganisms. Many pathogens require selective growth media or specialised containment due to their zoonotic potential, for example *Brucella* spp. or *Mycobacterium* spp..



## Virology

**Collection:** The choice of sampling for virology diagnostics should be made in collaboration with the laboratory undertaking the processing of the samples, taking into account the target virus, the (clinical and) gross lesions of the stranded animal(s) and the state of decomposition of the carcass. The tissues listed in these guidelines- lung, spleen, brain and kidney - are a good range of samples required for several known viruses, e.g. morbillivirus, influenzavirus, poxvirus, and herpesvirus detection. Any lesions of suspected viral aetiology should be sampled similarly. For virus isolation, samples of 1x1x1 cm from the relevant organs should be collected aseptically and placed into sterile containers with viral transport medium (VTM).

**Storage:** If samples are collected for molecular detection of pathogens by PCR and are submitted to the laboratory within 24 hours of sampling, they should be stored at 0-4°C, otherwise they should be frozen at -80°C before being submitted to analysis. If freezing at -80°C, or even at -20°C, is not possible, then the samples can be placed in RNAlater and stored at -20°C (or even at room temperature for up to two weeks). Frozen samples can be transported worldwide on dry ice (solid CO<sup>2</sup>) or using biofreeze bottles. For situations where large number of samples are being collected in the field or transported distance, it is advised to use an IATA approved LN2 Vapour/Dry shipper.

Sero-epidemiological investigations against viral and other infectious agents require a blood sample of at least 7 ml collected and centrifuged to obtain serum. Serum should be separated from whole blood as soon as possible and stored at -80°C. Even if the serum shows some evidence of erythrocytic haemolysis, it can still be of diagnostic value. Where a blood sample is unobtainable, a sample of pericardial fluid (PCF) and/or vitreous humour and/or lung and/or muscle tissue juices can be suitable substitutes, with special emphasis on consistently autolysed individuals. Furthermore, in well-preserved animals it is highly recommended to collect as soon as possible during the post mortem examination cerebrospinal fluid (CSF) samples, which may allow an *ad hoc* search of antibodies against a range of neurotropic pathogens (e.g. *Cetacean morbillivirus*, *herpesvirus*, *West Nile virus*, *Brucella* spp., *Toxoplasma gondii*, etc.).

## Parasitology

Parasite specimens should be isolated from the organs and cleaned from blood, dietary residues and adhering tissue in tap water (e.g. with a soft paint brush). Then preserve the

specimen in water in case of immediate analyses otherwise in 70% ethanol, or alcohol with 10% glycerine, or freeze it.

If the total number (intensity) of parasites cannot be recorded, a semi-quantitative assessment of the level of parasitic infection into none = no parasites visible, mild, moderate or severe infestation should be recorded for each organ. Documenting infection and associated lesions through photographs and histopathology is recommended. Furthermore, the macroscopically detectable severity of lesions associated with parasites should be recorded (no lesion, mild, moderate, severe) and the tissue sampled in 10% neutral-buffered formalin for histopathological examination.

## Toxicology

**Collection:** The choice of sampling for toxicological assessment should be made in collaboration with the laboratory undertaking the processing of the samples. It is recommended to duplicate samples of blubber, muscle, liver, kidneys and brain and collect these for persistent organic pollutant (POP), plastic additives and trace elements and/or fatty acids analysis. Samples collected for POP analysis should only come into contact with stainless steel, aluminium, glass or Teflon and are most conveniently stored in aluminium foil (shiny side out; do not use recycled foil as this might contain plastic particles) with an additional sample in plastic.

For lactating females, a milk sample should be collected. This must be stored in a glass container. If the container has a plastic cap, it is recommended to cover the opening with aluminium foil (shiny side out) to keep the sample from contacting the (plastic) cap, as this could invalidate the results of POP analysis.

Samples of brain, muscle, liver and kidney can be sampled for trace element analysis. These samples should not come into contact with any metals other than stainless steel and thus can be stored in plastic containers. Bone and/or blood samples are also suitable for heavy metal analysis.

If a foetus is present but too small for full post mortem examination, the whole foetus and (parts of) its placenta can be wrapped in aluminium foil (shiny side out) for POP analysis. For foetuses that can be dissected, it is recommended to conduct a full post mortem investigation with subsequent tissue sampling as done for other cases.

**Storage:** The minimal size of samples for trace elements and organochlorine analysis is 10g of solid tissue or 10 ml for milk. Samples should be stored frozen at -20°C until

analysis. For DCC1-2, samples should be stored at -80°C in liquid nitrogen or RNA later for Real-Time (RT) PCR.

## Biotoxins

Collection: Biotoxin samples collection is highly recommended particularly in case of unusual mortality events, mass mortalities and when a harmful algal bloom (HAB) is suspected in the surrounding area and/or the live animal exhibited neurological symptoms. Biotoxin samples include tissues and fluids such as: liver, kidney, brain, muscle, serum, aqueous humour, stomach contents, intestinal contents, faeces, urine. Tissue samples can be stored in plastic bags. Stomach and intestinal contents, faeces and urine can be collected in appropriate sized vials, usually 10-20 ml. Five to ten ml of urine and one to two ml of aqueous humour should be collected using sterile syringes and needles and stored in appropriate sized vials.

Storage: samples should be stored at -80°C unless being shipped immediately on dry ice.

## Suggested sampling protocols

The following tables contain a recommended suite of samples to be taken- obviously this should be modified according to the scientific and policy questions being asked of individual strandings networks. Table 2 is arranged by diagnostic investigation, and table 3 by organ system.

Table 2: Suggested minimum sampling protocol by diagnostic investigation

Diagnostic investigation	Tissue or Organ	max DCC	Aseptic fresh tissue	Frozen -20°C	Frozen -80°C	Ethanol	10% Buffered formalin	RNA Later	Quantity	Comment
(Algal) Biotoxins	Faeces	3		1					10-20 ml	
	Stomach content	3		1					10-20 ml	
	Urine	3		1					5-10 ml	
Biomarkers	Skin	1			1			1	2 cm3 of aseptic sample	Brain cut with a paramedian cut and 1/3 frozen
	Brain	1			1			1		
	CSF	1			1				2 ml	
	Liver	2			1			1	2 cm3 of aseptic sample	
	Lung	2			1			1		
	Pericardial fluid	2			1				>5ml supernatant	Centrifuged
Cell culture	Skin	1							1 cm3 of aseptic sample	
	Liver	1								
Contaminants	Brain	3		1	1				2x >10g, 1x wrapped in aluminium foil and 1x in plastic bag	Brain cut with a paramedian cut and 1/3 frozen
	Kidney	3		1						
	Liver	3		1						
	Blubber	3		1						
	Blood	3		1					10ml in glass vile	
	Placenta and foetal tissue	3			1				Whole foetus if it is small, or sample as a normal case. Placental tissue samples 2x >10g, 1x wrapped in aluminium foil and 1x in plastic bag	Freeze, -70/80°C
	Milk	3			1				10ml in glass vile	

	Muscle	3		1					2x >10g, 1x wrapped in aluminium foil and 1x in plastic bag			
Diet and marine debris	Stomach content	4		1		1			Collect whole			
Genetics	Muscle	5		1				1	2 cm3 of aseptic sample			
	Skin	4		1		1		1	2 cm3 of aseptic sample			
Histopathology	Brain	3						1		Brain cut with a paramedian cut and 2/3 in formalin		
	Cochlea	3						1		Whole complex immersed for histopathology		
	GIT	3						1		Sample 2 or 3 regions of GIT, including margins of any abnormal regions. Open intestines prior to fixing.		
	Kidney	3						1		Sections of 1x1cm including margins of abnormalities		
	Liver	3						1				
	Lung	4						1				
	Spleen	3						1				
	Skin	4						1				
	Adrenals	3						1			Measure cortico medullary ratio across middle of organ, weigh	
	Lymph nodes	3						1				
	Pancreas	2						1			Fix quickly as rapidly autolyses	
	Skeletal muscle	3						1			Fixed under tension e.g. tongue depressor	Dorsal fin epaxial muscle and rectus abdominus muscles
	Cardiac muscle	3						1			Sample 2 or 3 regions of heart, including valvular margins,	
	Reproductive tract	3						1		Sample 2 or 3 regions of GIT, including margins of any abnormal regions. Open intestines prior to fixing.		
Life	Teeth	5		1		1	1		Four or five	10% Formalin		

history	Gonadal tissue	4					1		Ovaries fixed whole, testes cross section, sample or uterus	measure length and weight, record asymmetry, include epididymis
	Baleen	5					1		Whole plate	Freeze, -20°C
Microbiology	Lung	3	1						Aseptic sample or swab	Refrigerated, 0-4°C prior to culture. For DCC4 microbiology can still be worthwhile using specific culture methods.
	Brain	3	1							
	CSF	3	1							
	Heart	3	1							
	Kidney	3	1							
	Liver	3	1							
	Lung	3	1							
	Spleen	3	1							
	Reproductive tract	3	1							
	Blood clots	2	1						>5ml	Do not centrifuge
Museum collections	Scapula	5		1					Collect whole	Freeze, -20°C
	Skeleton	5		1						
	Skull	5		1						
Parasitology	Stomach contents	4		1		1			Parasitology samples collected whole, dissect out head attachments of parasitic worms	Freeze, -20°C
	Intestine	4		1		1				
	Lung	4		1		1				
	Liver	4		1		1				
	Subcutaneous tissue	4		1		1				
	Renal vasculature and kidneys	4		1		1			in fin and beaked whales particularly	
	Cochlea/Eustachian tube/surrounding tissue	4		1		1				
	Other tissues	4		1		1			Parasitology samples collected whole, dissect out head attachments of parasitic worms	70% Ethanol
	Faeces	4		1					5 g	
	Cardiac and skeletal muscle	3	1							For Toxoplasma biomolecular identification on samples stored -80 °C

SEM / ultrastructure	Cochlea	1					1	Ears perfused with 10% neutral buffered formalin (or 4% paraformaldehyde) as per Maria Morell protocol	
Serology	Blood	2						From right ventricle with a sterile syringe	Centrifuge at 1000-1500 rounds/8-10 min and store at -70/80°C
Stable isotopes and fatty acids	Skin	4		1				2 cm3 of aseptic sample	Freeze, -70/80°C
	Muscle	4		1					
	Blubber	4		1					
	Baleen	5		1					
	Teeth	5		1					
	Liver	4		1					
Virology	Brain	3			1			2 cm3 of aseptic sample	Freeze, -70/80°C
	Liver	3			1				
	Lung	3			1				
	Placenta and foetal tissue	3			1				
	Spleen	3			1				
	Lung	3			1				
	Lymph nodes	3			1				

Table 3: Suggested minimum sampling list by organ

Tissue or Organ	Diagnostic investigation	max DCC	Aseptic fresh tissue	Frozen -20°C	Frozen -80°C	Ethanol	10% Buffered formalin	RNA Later	Quantity	Comment
Adrenals	Histopathology	3					1			Measure cortico medullary ratio across middle of organ, weigh
Baleen	Stable isotopes and fatty acids	5		1						
	Life history	5		1						
Blood	Serology	2		1					From right ventricle with a sterile syringe	Spin-dry the blood at 3000 rpm and freeze the serum at -20°C
	Microbiology	2	1						>5ml supernatant	Centrifuged for serology
	Contaminants	3		1					>10g, wrapped in aluminium foil	
Blubber	Contaminants	3		1					>10g, wrapped in aluminium foil	
	Stable isotopes and fatty acids	4		1					2 cm3 of aseptic sample	Freeze, -70/80°C
Brain	Biomarkers	1			1				2 cm3 of aseptic sample	Brain paramedian cut and 1/3 frozen
	Virology	3			1				2 cm3 of aseptic sample, possibly multiple sites	Freeze, -70/80°C
	Contaminants	3		1	1				>10g, wrapped in aluminium foil	Brain paramedian cut and 1/3 frozen
	Histopathology	3					1			Brain paramedian cut and 2/3 in formalin
	Microbiology	3	1						Aseptic sample or swab	Refrigerated, +1°C prior to culture
Cardiac muscle	Histopathology	3					1		Sample 2 or 3 regions of heart, including valvular margins	



	Microbiology	3	1						Aseptic sample or swab	Toxoplasma identification possible on samples stored at -80
	Microbiology	3	1						Aseptic sample or swab	Refrigerated, +1°C prior to culture
Cochlea	SEM / ultrastructure	1					1		Ears perfused with 10% neutral buffered formalin (or 4% paraformaldehyde) as per Maria Morell protocol	
	Histopathology	3					1		Whole complex immersed for histopathology	
	Parasitology	4		1		1				
CSF	Biomarkers	1			1				2 cm <sup>3</sup> of aseptic sample	
	Microbiology	3	1						Aseptic sample or swab	Best for culture of <i>Brucella</i> spp.
Faeces	(Algal) biotoxins	3		1					50g	
	Parasitology	4		1					5 g	
GIT	Histopathology	3					1		Sample 2 or 3 regions of GIT, including margins of any abnormal regions. Open intestines prior to fixing.	
Gonadal tissue	Life history	4					1		Ovaries fixed whole, Testes cross section	measure length and weight, record asymmetry, include epididymis.
Intestine	Microbiology	2	1						At least 3 different samples from different tracts	
	Parasitology	4		1		1			Parasitology samples collected whole, dissect out head attachments of parasitic worms	Freeze, -20°C
Kidney	Histopathology	2					1		Sections of 1cm thickness over normal/abnormal border	
	Contaminants	3		1					>10g, wrapped in aluminium foil	

	Microbiology	3	1					Aseptic sample or swab	Refrigerated, +1°C prior to culture
Liver	Biomarkers	2			1			1	
	Contaminants	3		1				>10g, wrapped in aluminium foil	
	Histopathology	3					1	Sections of 1cm thickness over normal/abnormal border	
	Microbiology	3	1					Aseptic sample or swab	Refrigerated, +1°C prior to culture
	Virology	3			1			2 cm3 of aseptic sample	Freeze, -70/80°C
	Parasitology	4		1		1		Parasitology samples collected whole, dissect out head attachments of parasitic worms	Freeze, -20°C
	Stable isotopes and fatty acids	4		1					
Lung	Biomarkers	2			1			1	
	Contaminants	3		1				>10g, wrapped in aluminium foil	
	Microbiology	3	1					Aseptic sample or swab	Refrigerated, +1°C prior to culture
	Virology	3			1			2 cm3 of aseptic sample	Freeze, -70/80°C
	Histopathology	4					1	Sections of 1cm thickness over normal/abnormal border	
	Parasitology	4		1		1		Parasitology samples collected whole, dissect out head attachments of parasitic worms	Freeze, -20°C
Lymph nodes	Virology	3			1			2 cm3 of aseptic sample	Freeze, -70/80°C
	Histopathology	3					1	Sections of 1cm thickness over normal/abnormal border	

Muscle	Contaminants	3		1					>10g, wrapped in aluminium foil	
	Stable isotopes and fatty acids	4		1					2 cm <sup>3</sup> of aseptic sample	Freeze, -70/80°C
	Genetics	5		1			1		2 cm <sup>3</sup> of aseptic sample	
	Parasitology	3		1						For Toxoplasma biomolecular identification on samples stored -80 °C
Other tissues	Parasitology	4		1		1			Parasitology samples collected whole, dissect out head attachments of parasitic worms	70% Ethanol
Pancreas	Histopathology	2					1		Sections of 1cm thickness over any normal/abnormal border	Fix quickly as rapidly autolyses
Pericardial fluid	Biomarkers	2			1				>5ml supernatant	Centrifuged
Placenta and foetal tissue	Contaminants	3			1				2 cm <sup>3</sup> of aseptic sample	Freeze, -70/80°C
	Virology	3			1				2 cm <sup>3</sup> of aseptic sample	Freeze, -70/80°C
Renal vasculature	Parasitology	4		1		1				
Reproductive tract	Microbiology	3	1				1		Aseptic sample or swab	Refrigerated, +1°C prior to culture
	Histopathology	3							Sections of 1cm thickness over normal/abnormal border	
Scapula	Museum collections	5		1					Collect whole	Freeze, -20°C
Skeletal muscle	Histopathology	3					1		Fixed under tension e.g. tongue depressor	Dorsal fin epaxial muscle and rectus abdominus muscles
	Microbiology	3	1						Aseptic sample or swab	Refrigerated, +1°C prior to culture

Skeleton	Museum collections	5		1				Collect whole	Freeze, -20°C
Skin	Biomarkers	1			1		1	2 cm3 of aseptic sample	
	Contaminants	3		1				>10g, wrapped in aluminium foil	
	Genetics	4		1		1	1	2 cm3 of aseptic sample	
	Histopathology	4					1		
	Stable isotopes and fatty acids	4		1				2 cm3 of aseptic sample	Freeze, -70/80°C
Skull	Museum collections	5		1				Collect whole	Freeze, -20°C
Spleen	Histopathology	3					1	Sections of 1cm thickness over normal/abnormal border	
	Microbiology	3	1					Aseptic sample or swab	Refrigerated, +1°C prior to culture
	Virology	3			1			2 cm3 of aseptic sample	Freeze, -70/80°C
Stomach content	Algal biotoxins	3		1				Collect whole	
	Diet and marine debris	4		1		1		Collect whole	
	Parasitology	4		1		1		Parasitology samples collected whole, dissect out head attachments of parasitic worms	Freeze, -20°C
Subcutaneous tissue	Parasitology	4		1		1			
Teeth	Life history	5		1		1	1	Four or five	10% Formalin
	Stable isotopes and fatty acids	5		1					
Urine	(Algal) biotoxins	3		1				5ml	



## Acknowledgements

This publication arose from several previous workshops, meetings and expert elicitation rounds. This work was originally initiated in 1991 by Thijs Kuiken and Manuel García-Hartmann, who organised the first cetacean pathology workshop as previously published by the European Cetacean Society (1993). Approximately 25 years later, similar workshops were organised by ACCOBAMS (Report of the ACCOBANS/PELAGOS Workshop on Cetacean Live Strandings, Monaco 2014) and during other ECS conferences, including that in Malta in 2015, for which we acknowledge the main organizer Thierry Jauniaux, and in Funchal, Madeira in 2016.

The final document as presented here was completed with support of ACCOBAMS, ASCOBANS and the IWC Strandings initiative.

## Literature

ACCOBAMS Resolution 6.22 - Cetaceans Live Strandings. Annex II Common Best Practices for a basic post-mortem examination of stranded cetaceans.

Arbelo, M., de los Monteros, A. E., Herráez, P., Andrada, M., Sierra, E., Rodríguez, F., ... & Fernández, A. (2013). Pathology and causes of death of stranded cetaceans in the Canary Islands (1999– 2005). *Diseases of aquatic organisms*, 103(2), 87-99.

Brody, S. (1945). *Bioenergetics and Growth*, Reinhold Publishing, New York (1945), pp. 484-663.

Bernaldo de Quirós, Y., González-Díaz, Ó., Arbelo, M., Andrada, M., & Fernández, A. (2012). Protocol for gas sampling and analysis in stranded marine mammals. Protocol exchange.

Díaz-Delgado, J., Fernandez, A., Sierra, E., Sacchini, S., Andrada, M., Vela, A. I., ... & Arbelo, M. (2018). Pathologic findings and causes of death of stranded cetaceans in the Canary Islands (2006-2012). *PloS one*, 13(10), e0204444.

Dierauf, L., & Gulland, F. M. (Eds.). (2001). *CRC handbook of marine mammal medicine: health, disease, and rehabilitation*. CRC press.

Di Guardo, G., Di Francesco, C. E., Eleni, C., Cocumelli, C., Scholl, F., Casalone, C., ... & Leonardi, L. (2013). Morbillivirus infection in cetaceans stranded along the Italian coastline: pathological, immunohistochemical and biomolecular findings. *Research in Veterinary Science*, 94(1), 132-137.

Gulland, F. M., & Hall, A. J. (2007). Is marine mammal health deteriorating? Trends in the global reporting of marine mammal disease. *EcoHealth*, 4(2), 135-150.

Hunt, T. D., Ziccardi, M. H., Gulland, F. M., Yochem, P. K., Hird, D. W., Rowles, T., & Mazet, J. A. (2008). Health risks for marine mammal workers. *Diseases of aquatic organisms*, 81(1), 81-92.

Jauniaux, T., Petitjean, D., Brenez, C., Borrens, M., Brosens, L., Haelters, J., ... & Coignoul, F. (2002). Post-mortem findings and causes of death of harbour porpoises (*Phocoena phocoena*) stranded from 1990 to 2000 along the coastlines of Belgium and Northern France. *Journal of Comparative Pathology*, 126(4), 243-253.

- Jepson, P. D., Deaville, R., Barber, J. L., Aguilar, À., Borrell, A., Murphy, S., ... & Cunningham, A. A. (2016). PCB pollution continues to impact populations of orcas and other dolphins in European waters. *Scientific Reports*, 6, 18573.
- Kuiken, T., & García Hartmann, M. (1993). Cetacean pathology: dissection techniques and tissue sampling. *ECS Newsletter* 17. Special Issue, 1-43.
- Lane, E. P., De Wet, M., Thompson, P., Siebert, U., Wohlsein, P., & Plön, S. (2014). A systematic health assessment of Indian ocean bottlenose (*Tursiops aduncus*) and Indo-Pacific humpback (*Sousa plumbea*) dolphins incidentally caught in shark nets off the KwaZulu-Natal coast, South Africa. *PloS One*, 9(9), e107038.
- Leeney, R. H., Amies, R., Broderick, A. C., Witt, M. J., Loveridge, J., Doyle, J., & Godley, B. J. (2008). Spatio-temporal analysis of cetacean strandings and bycatch in a UK fisheries hotspot. *Biodiversity and Conservation*, 17(10), 2323.
- Lockyer, C. (1991). Body composition of the sperm whale, *Physeter catodon*, with special reference to the possible functions of fat depots. Marine Research Institute.
- Mazzariol S., Cozzi B., Centelleghè C. (2015). Handbook for Cetaceans' Strandings. Available at: <http://www.netcet.eu/dissemination/item/132-handbook-for-cetaceans%E2%80%99-strandings>
- Morell, M., André, M. (2009). Cetacean ear extraction and fixation protocol. Available at: [http://www.zoology.ubc.ca/files/Ear\\_extraction\\_and\\_fixation\\_protocol\\_UBC.pdf](http://www.zoology.ubc.ca/files/Ear_extraction_and_fixation_protocol_UBC.pdf)
- Peltier, H., Authier, M., Deaville, R., Dabin, W., Jepson, P. D., Van Canneyt, O., ... & Ridoux, V. (2016). Small cetacean bycatch as estimated from stranding schemes: The common dolphin case in the northeast Atlantic. *Environmental Science & Policy*, 63, 7-18.
- Peltier, H., Baagøe, H. J., Camphuysen, K. C., Czeck, R., Dabin, W., Daniel, P., ... & Jepson, P. D. (2013). The stranding anomaly as population indicator: the case of harbour porpoise *Phocoena phocoena* in North-Western Europe. *PLoS One*, 8(4), e62180.
- Peltier, H., Dabin, W., Daniel, P., Van Canneyt, O., Dorémus, G., Huon, M., & Ridoux, V. (2012). The significance of stranding data as indicators of cetacean populations at sea: Modelling the drift of cetacean carcasses. *Ecological Indicators*, 18, 278-290.
- Plön, S., de Wet, M., Lane, E., Wohlsein, P., Siebert, U., & Thompson, P. (2015). A standardized necropsy protocol for health investigations of small cetaceans in southern Africa. *African Journal of Wildlife Research*, 45(3), 332-342.



- Pyenson, N. D. (2011). The high fidelity of the cetacean stranding record: insights into measuring diversity by integrating taphonomy and macroecology. *Proceedings of the Royal Society B: Biological Sciences*, 278(1724), 3608-3616.
- Raverty, S.A., Duignan, P.J., Jepson, P.D., Morell, M. (2018). Gross Necropsy and Specimen Collection Protocols (Chapter 13). In: *CRC Handbook of Marine Mammal Medicine, Third Edition* (Ed. Dierauf, Gulland). CRC Press/Taylor & Francis Group, 249-266.
- Reyes, J. C., Mead, J. G., & Waerebeek, K. V. (1991). A new species of beaked whale *Mesoplodon peruvianus* sp. n. (Cetacea: Ziphiidae) from Peru. *Marine Mammal Science*, 7(1), 1-24.
- Siebert, U., Joiris, C., Holsbeek, L., Benke, H., Failing, K., Frese, K., Petzinger, E. (1999). Potential Relation Between Mercury Concentrations and Necropsy Findings in Cetaceans from German Waters of the North and Baltic Seas. *Marine Pollution Bulletin*, 38(4), 285-95.
- Siebert, U., Wünschmann, A., Weiss, R., Frank, H., Benke, H., & Frese, K. (2001). Post-mortem findings in harbour porpoises (*Phocoena phocoena*) from the German North and Baltic Seas. *Journal of Comparative Pathology*, 124(2-3), 102-114.
- ten Doeschate, M. T., Brownlow, A. C., Davison, N. J., & Thompson, P. M. (2018). Dead useful; methods for quantifying baseline variability in stranding rates to improve the ecological value of the strandings record as a monitoring tool. *Journal of the Marine Biological Association of the United Kingdom*, 98(5), 1205-1209.
- Trites, A. W., & Pauly, D. (1998). Estimating mean body masses of marine mammals from maximum body lengths. *Canadian Journal of Zoology*, 76(5), 886-896.
- Tryland, M. (2000). Zoonoses of arctic marine mammals. *Infectious Disease Review*, 2(2), 55-64.
- Van Bresseem, M. F., Raga, J. A., Di Guardo, G., Jepson, P. D., Duignan, P. J., Siebert, U., ... & Aguilar, A. (2009). Emerging infectious diseases in cetaceans worldwide and the possible role of environmental stressors. *Diseases of Aquatic Organisms*, 86(2), 143-157.
- Waltzek, T. B., Cortés-Hinojosa, G., Wellehan Jr, J. F. X., & Gray, G. C. (2012). Marine mammal zoonoses: A review of disease manifestations. *Zoonoses and public health*, 59(8), 521-535.



Annex 1. Decomposition condition coding example pictures

DCC1 (<24H)



DCC2 (48H – 72H)



DCC3 (DAY 6)



DCC4 (DAY 24)



DCC5 (DAY 32)



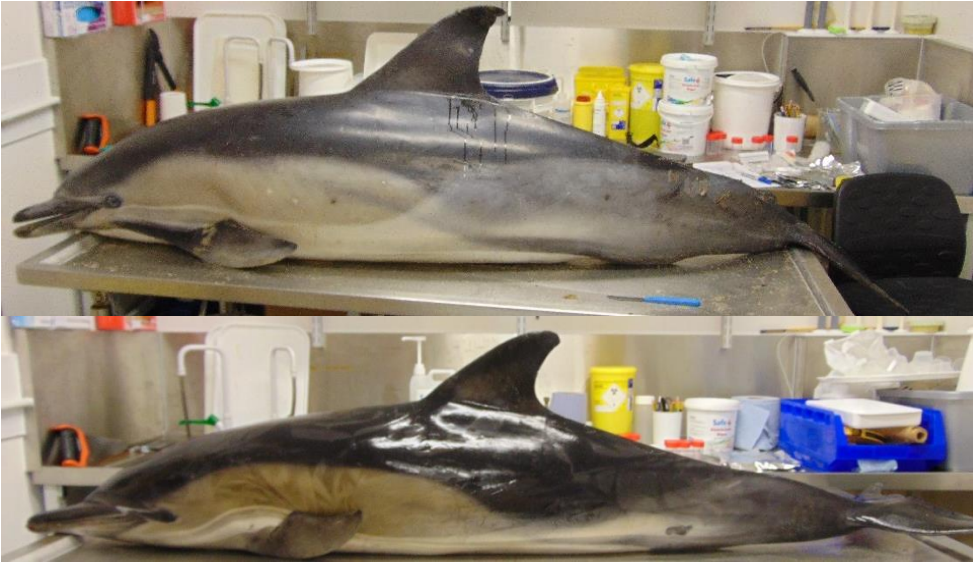Harbour porpoise example pictures 1 (DCC1-5). Photo credits: Pelagis



Harbour porpoise example pictures 2 (DCC1-5). Photo credits: Utrecht University



DCC1:



DCC2:

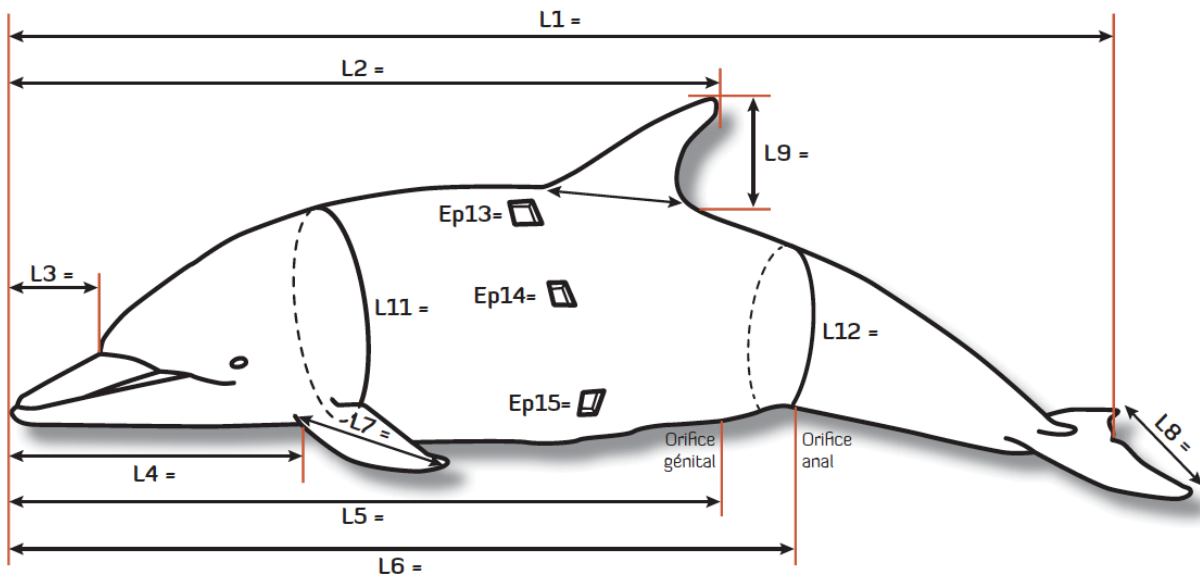


DCC3:



Common dolphin example pictures (DCC1-3). Photo credits: CSIP, James Barnett

## Annex 2. Additional body measurements to consider



Additional body measurements to consider, especially in case of rare species. Image credit: Pelagis

## Annex 3. Brain sampling image

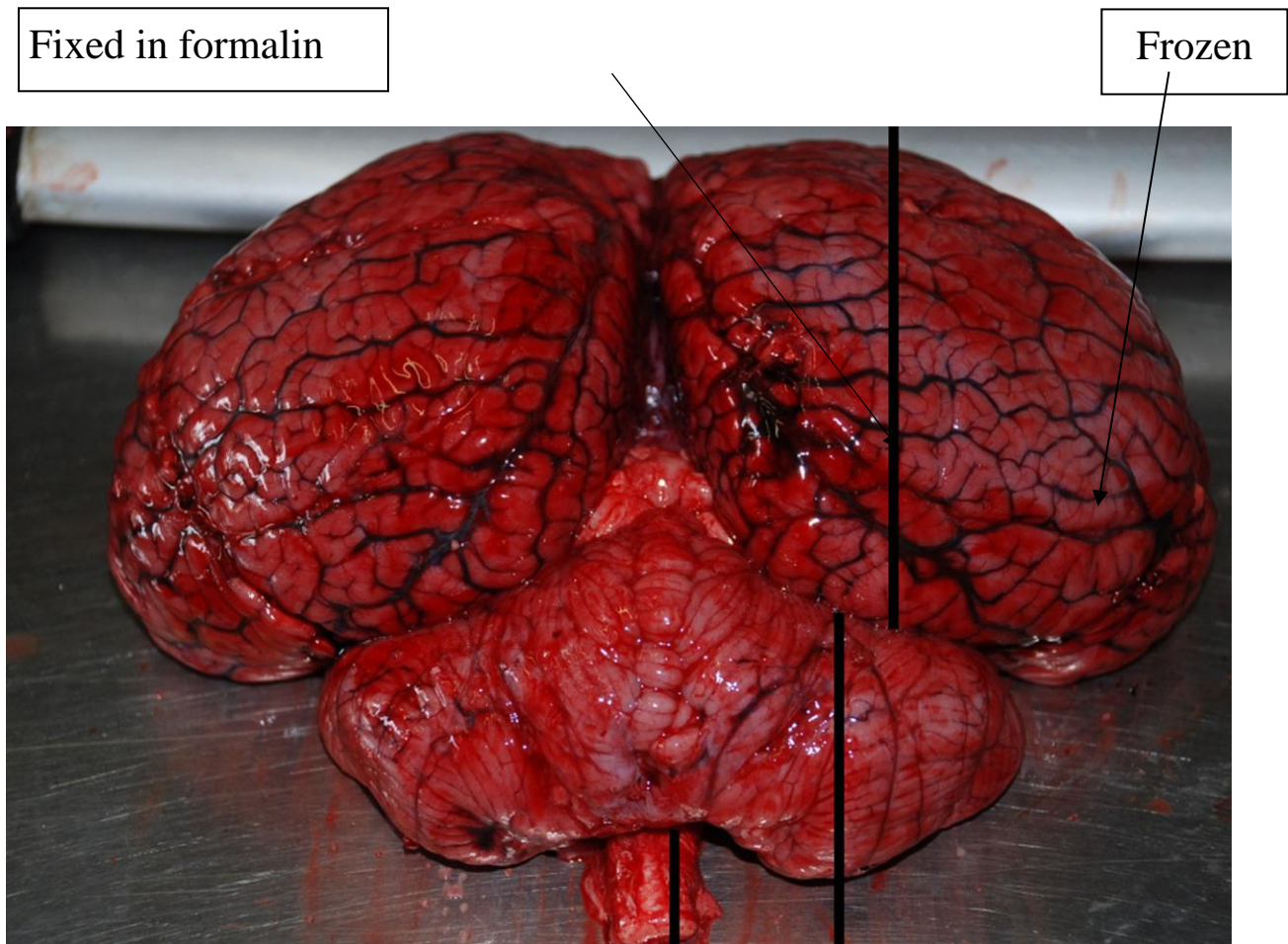


Fig. X: Sagittal paramedian cut of the brain. The largest portion fixed in 10% buffered formalin for histopathological examination and the smallest portion stocked frozen for microbiological, ecotoxicological and virological investigations. Image credit: C.Re.Di.Ma.