

Effect of Autogenous Cortical Bone Grafting in Conjunction with Guided Tissue Regeneration in the Treatment of Intraosseous Periodontal Defects

Gonca Cayir Keles^a

Mahmut Sumer^b

Burcu Ozkan Cetinkaya^a

Ferda Tutkun^a

S. Burcak Simsek^c

ABSTRACT

Objectives: The aim of this clinical trial was to evaluate the additional benefit of using guided tissue regeneration (GTR) with autogenous cortical bone (ACB) grafting versus ACB grafting alone for the regenerative treatment of intraosseous periodontal defects.

Methods: Via a split-mouth design, 12 patients with chronic periodontitis (five men, seven women; mean age, 45.3±4.6 years) who had probing pocket depths (PPDs) of ≥6 mm following initial periodontal therapy were randomly assigned to two treatments in contralateral areas of the dentition: a combination of ACB grafting and GTR (with a absorbable membrane of polylactic acid) or ACB grafting alone. The compared parameters were preoperative and 6-month postoperative PPDs, clinical attachment levels (CALs), and radiographic alveolar bone heights.

Results: Both treatment modalities resulted in significant changes in the postoperative measurements from the preoperative values ($P<.01$). The reduction in the PPDs, gain in the CALs, and gain in the radiographic alveolar bone heights were 4.58±1.08, 4.25±1.06, and 5.50±2.24 mm in the patients treated with ACB grafting and GTR and 4.92±1.00, 4.50±0.80, and 5.92±1.83 mm in those treated with ACB grafting alone, respectively. The differences between the treatments were not statistically significant ($P>.05$).

Conclusions: Within the study limitations, both ACB grafting with GTR and ACB grafting alone lead to significant improvements in clinical and radiographic parameters at 6 months postoperatively. The combined approach does not provide any additional benefit for treating intraosseous periodontal defects. (Eur J Dent 2010;4:403-411)

Key words: Autogenous bone graft; Guided tissue regeneration; Intraosseous defects; Periodontal regeneration.

^a Ondokuz Mayıs University, Faculty of Dentistry, Department of Periodontology, Samsun, Turkey.

^b Ondokuz Mayıs University, Faculty of Dentistry, Department of Oral and Maxillofacial Surgery, Samsun, Turkey.

^c Goztepe Oral and Dental Health Center, Istanbul, Turkey.

■ Corresponding author:
Dr. Gonca Cayir Keles
Ondokuz Mayıs University, Faculty of Dentistry,
Department of Periodontology 5139
Samsun, Turkey.
Phone: +90 362 3121919/3017
Fax: +90 362 4576032
E-mail: goncakeles@hotmail.com

INTRODUCTION

Periodontitis, an oral infectious disease, is characterized by clinical attachment loss, alveolar bone resorption, periodontal pocket formation, and gingival inflammation.^{1,2} One of the main objectives of periodontal therapy is regeneration of the periodontium, including restoration of the alveolar bone, cementum, and periodontal ligament lost because of periodontitis.^{3,4} Periodontal regeneration can be achieved by guided tissue regeneration (GTR),⁴ which delays the apical migration of the gingival epithelium by excluding the gingival connective tissue and allows granulation tissue derived from the periodontal ligament and osseous tissues to repopulate the space adjacent to the denuded root surface through the use of barrier membranes.⁵ New connective tissue attachment and bone fill, and improved clinical parameters have been documented in human biopsy^{6,7} and clinical GTR studies,^{8,9} respectively.

Bone grafting procedures with autogenous bone grafts, allografts, xenografts, and alloplasts are also used to promote periodontal regeneration.⁴ Among the different available graft materials, autogenous bone remains the gold standard for osseous regeneration.^{4,10,11} Autogenous bone has osteogenic potential, as it contains cells that participate in osteogenesis.^{4,12} Moreover, autografts are bioabsorbable (they are eventually replaced by the patient's own bone),¹⁰ nonallergenic (they cause minimal tissue reaction without an immunological reaction),^{4,10} easy to handle, and not costly.¹³ Rapid revascularization occurs around autogenous bone graft particles, and the graft can release growth and differentiation factors.^{4,14} Although autogenous bone grafts present some disadvantages, such as the need for secondary surgical sites and resulting additional surgical morbidity,^{10,15} they can be minimized by using intraoral harvested bone.¹⁵ The use of the latter graft material is however limited by the restricted donor sites in the oral cavity for extensive grafting.^{4,15}

In order to support barrier membranes, prevent collapse, and promote bone formation, GTR has often been combined with the placement of bone grafts or bone graft substitutes. The effectiveness of the combined procedure for treating periodontal intraosseous defects has been evaluated in comparison with the use of GTR alone in

many studies, which have shown contradictory results.¹⁶⁻¹⁹ Some clinical studies have demonstrated better clinical results and bone fill with the combined procedure,^{16,19} whereas no significant difference was found between the treatments in other studies.^{17,18} Moreover, few experimental studies have reported successful alveolar ridge augmentation by combining autogenous mandibular bone grafts with nonresorbable and resorbable GTR membranes.^{20,21} One clinical study has shown that the combination of an autogenous bone graft and a bioabsorbable GTR membrane is effective for treating three-wall periodontal defects.²²

Data from both clinical and histological studies suggest that periodontal regeneration occurs following treatment with autogenous bone grafts.²³⁻²⁵ However, a 12-month clinical study has shown that autogenous cancellous bone from the jaw compared with open flap debridement is not suitable for treating intrabony periodontal defects.²⁶ Noteworthy, an autogenous cortical bone (ACB) graft, sourced from the surgical site adjacent to the intraosseous defect, is advantageous as it prevents the need for a second surgical site while treating intraosseous periodontal defects. Further, the use of a physical barrier in addition to an ACB graft may enhance the regenerative outcome. The aim of this clinical trial was to evaluate the additional benefit of using GTR in conjunction with ACB grafting versus ACB grafting alone for the regenerative treatment of intraosseous periodontal defects.

MATERIALS AND METHODS

Experimental design

Two different approaches to treat intraosseous periodontal defects were compared by using a split-mouth, randomized, controlled design. Randomization was conducted before surgery according to the flip of a coin. The same surgical and grafting procedures were performed in both groups of patients; the application of a bioabsorbable GTR membrane was the only difference between the groups. The clinical and radiographic outcomes were measured on the day of surgery and at 6 months postoperatively.

Study population

Patients with chronic periodontitis exhibiting radiographic evidence of bone loss were recruited for the study. For inclusion, the subjects

had to have similar interproximal osseous defects without furcation involvement in each of the contralateral quadrants including the premolars and molars. Third molars with grade III mobility, teeth with inadequate endodontic treatment, and/or restored teeth were excluded from the study. The exclusion criteria were systemic disease (i.e., diabetes mellitus, cancer, HIV, bone metabolic diseases, or disorders that compromise wound healing), chronic high-dose steroid therapy, radiation or immunosuppressive therapy, pregnancy, lactation, allergy or sensitivity to any drug, and smoking. The subjects had no history of drug therapy for the last 6 months before recruitment to the study.

The enrolled patients signed an informed consent form after receiving information about the study. The study protocol and consent forms were approved by the University Institutional Review Board (assignment protocol 06.12.2005/327).

Initial periodontal therapy

The initial periodontal therapy in all the patients consisted of oral hygiene instruction, full-mouth scaling and root planing, and occlusal adjustment when indicated. Four to six weeks following the completion of this therapy, a periodontal reevalu-

ation was performed to determine the patient's response to the therapy and confirm the need for periodontal surgery. Furthermore, the following selection criteria had to be met: 1) probing pocket depth (PPD) ≥ 6 mm; 2) radiographic and intrasurgical osseous defect depth ≥ 4 mm; 3) two or three osseous walls.

Clinical and radiographic measurements

The PPD and clinical attachment level (CAL) were measured and plaque index (PI)²⁷ and gingival index (GI)²⁸ scores were recorded immediately before the surgery and at 6 months postoperatively by using a Florida Probe (Florida Probe Corp., Gainesville, FL, USA). The measurements were recorded by the same examiner (intra-examiner calibration), who was blinded to the treatments, in six areas per tooth: mesiobuccal, distobuccal, midbuccal, mesiolingual, distolingual, and midlingual.

Standardized radiographs were obtained by using the parallel technique with a customized film holder prior to the surgery and at 6 months postoperatively.²⁹ The radiographic defect angle was measured between the two lines representing the root surface of the involved tooth and the bone

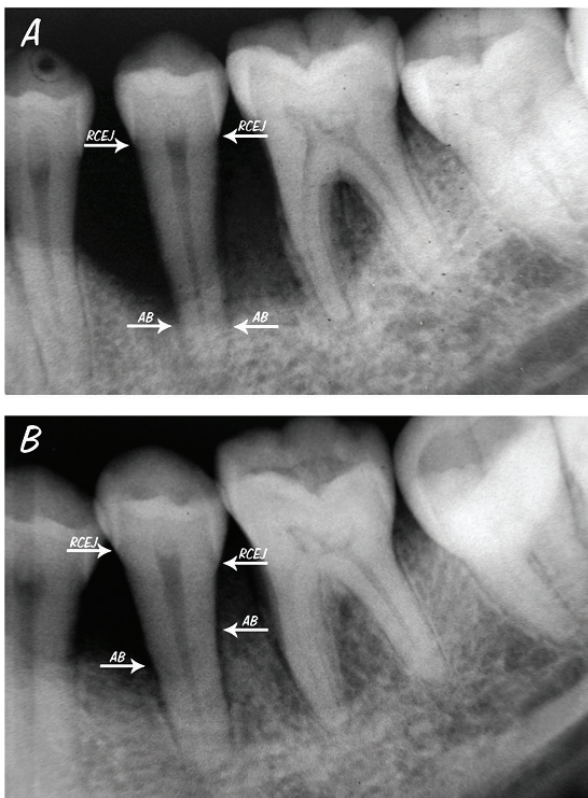


Figure 1. Radiographic appearances of an intraosseous defect treated with ACB grafting and GTR (CEJ, cementoenamel junction; AB, alveolar bone). A. Before treatment B. After treatment.

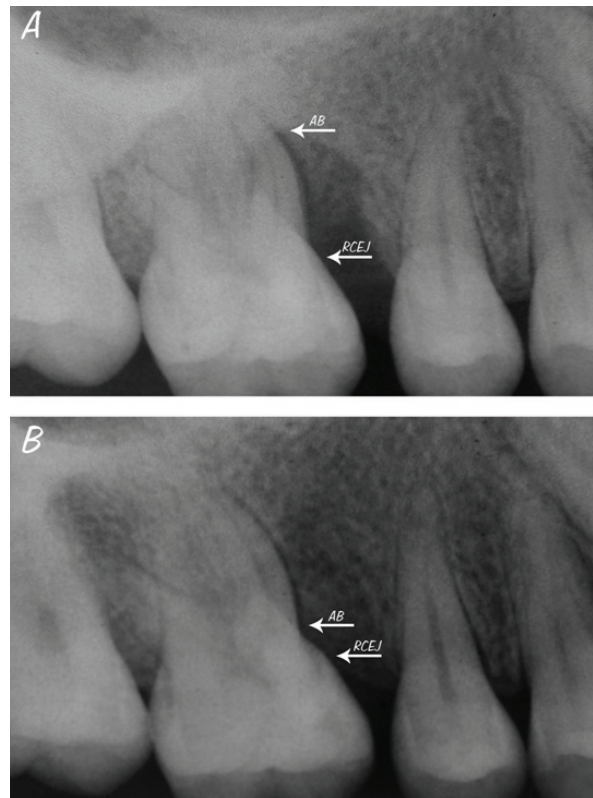


Figure 2. Radiographic appearances of an intraosseous defect treated with ACB grafting alone (CEJ, cementoenamel junction; AB, alveolar bone). A. Before treatment B. After treatment.

defect surface.^{30,31} The linear alveolar bone level, between the radiographic cemento-enamel junction (CEJ) and the most apical alveolar bone, was determined by using millimeter-scale paper.²⁹

Surgical procedure

All the operative procedures were performed on an outpatient basis under aseptic conditions by two experienced periodontal clinicians under local anesthesia; one of them performed the surgical procedure and the other assisted during the procedure. Following buccal and lingual intracrevicular incisions, full-thickness mucoperiosteal flaps were raised to allow access to the intrabony defect and facilitate primary closure where possible. Vertical releasing incisions were made only if necessary for better access or to achieve better closure of the surgical site. All the granulation tissues were removed from the defects, and the roots were thoroughly scaled and planed by using hand and ultrasonic instruments. The surgical sites were then rinsed with sterile saline.

During surgery, the depth of the intrabony defect was determined as the distance from the alveolar bone crest to the bottom of the defect, which is calculated as the distance between the CEJ and the bottom of the osseous defect minus the distance between the CEJ and the most coronal extension of the alveolar bone crest.³²

An adequate amount of particulate cortical bone was harvested from the buccal cortical plate adjacent to the intraosseous defect by using a bone scraper and implanted into the intrabony defect. For the treatment with ACB grafting and GTR, Atrisorb (Atrix Laboratories, Inc., Fort Collins, CO, USA), an absorbable polylactide membrane, was prepared according to the manufacturer's instructions and placed over the grafted defects. The flaps were repositioned and secured with 4-0 silk suture material by using the interrupted and vertical mattress suturing technique. Primary closure was obtained in all cases.

Postoperative care

The patients were prescribed amoxicillin + clavulanic acid (2 g/day for 7 days), flurbiprofen (200 mg/day for 3 days), and 0.2% chlorhexidine gluconate mouth rinse (twice a day for 6 weeks). Mechanical tooth cleaning was not allowed in the surgical area for the first 6 postoperative weeks.

The sutures were removed one week after surgery. Recall appointments for supragingival professional tooth cleaning and oral hygiene reinforcement were scheduled every other week during the first two months after surgery and once a month for the rest of the study period.

Statistical analysis

A commercially available software program (SPSS version 13.0; SPSS, Inc., Chicago, IL, USA) was used for statistical analysis. The Shapiro-Wilk test was used to investigate whether the data were normally distributed or not and the Wilcoxon signed-rank test was used for intragroup and intergroup comparisons.

The power analysis indicated that 12 defects in each treatment modality would be sufficient to demonstrate statistical significance at the $P < .05$ level with a power of (at least) $\geq 80\%$. The data are shown as the mean \pm standard deviation or the median (range).

RESULTS

Twelve patients (five men and seven women) aged 45.3 ± 4.6 years (38–52 years) with 24 intraosseous defects were treated. The radiographic defect angles were intermediate in both the ACB graft-treated group (30.25 ± 2.14 degrees) and ACB graft with GTR-treated group (29.67 ± 1.83 degrees). An analysis of the defect characteristics at the baseline revealed no significant differences between the treatment modalities ($P > .05$), as summarized in Table 1.

Defect healing following both the surgical techniques was uneventful. Neither allergic reaction nor suppuration or abscess formation was observed at any surgical site. Further, membrane exposure was not detected.

The PI and GI scores are presented in Table 2. The GI scores decreased at 6 months postoperatively compared with the preoperative data ($P < .01$), but the PI scores were not different from the preoperative values ($P > .05$) in both groups. Intergroup comparisons of the preoperative and postoperative data showed no significant differences between the groups ($P > .05$).

Intragroup comparisons showed that both treatment modalities resulted in significant changes in the postoperative measurements compared with the preoperative values ($P < .01$).

The PPD reduced by 4.58 ± 1.08 mm in the ACB graft with GTR-treated group and 4.92 ± 1.00 mm in the ACB graft-treated group. The preoperative CAL improved by 4.25 ± 1.06 and 4.50 ± 0.80 mm in the ACB graft with GTR-treated and ACB graft-treated groups, respectively. Further, the gain in radiographic alveolar bone height was 5.50 ± 2.24 mm in the ACB graft with GTR-treated group and 5.92 ± 1.83 mm in the ACB graft-treated group (Figures 1 and 2). No statistically significant difference in any clinical parameters was observed between the groups ($P>.05$), as shown in Table 3.

DISCUSSION

The results of the present study showed clinical improvement in the clinical and radiographic parameters after both regenerative treatments without significant differences between the treatment modalities. This result means that the GTR protocol did not provide an additional benefit to ACB grafting.

Reduction in the PPD and gain in the CAL are the most important clinical outcomes of regener-

ative therapy.³³ It is well documented that a gain in the CAL after any type of regenerative and conventional periodontal treatment is dependent on the initial PPD; that is, the deeper the initial PPD, the greater is the PPD reduction and clinical attachment gain.⁸ In addition, the depth of the intrabony defect is the determining factor for the maximal possible attachment gain.³⁴ In this way, a deeper intrabony defect may be related to a greater gain in the CAL.⁸ There were no differences between the treatment groups in terms of the initial PPD and intrabony defect depth. The gain in the CAL might have resulted from periodontal regeneration via new attachment or healing characterized by the formation of long junctional epithelium between the new regenerated tissues and the root surface.³⁵ Histological analysis of regenerative periodontal therapy is important in addition to observing clinical and radiographic results. As has been reported,³⁶ both radiographic interpretations and changes in CAL measurements over time are reliable for assessing the outcome of intrabony defect treatments. In other words, the use of the CAL and

Table 1. Preoperative characteristics of intraosseous defects.

	ACB/GTR*	ACB*
Upper/lower teeth	7/5	5/7
Premolar/molar teeth	6/6	5/7
Defect wall component (2-wall/3-wall)	9/3	8/4
Depth of the intrabony defect (mm)	5.00 ± 1.13	5.25 ± 0.87
Defect angle (°)	29.67 ± 1.83	30.25 ± 2.14

Depths of the intrabony defect and defect angles are expressed as the means±standard deviation.

*: No significant difference between the values of the groups ($P>.05$)

Table 2. Plaque index and gingival index scores of intraosseous defects.

	Preoperative	Postoperative 6 months	Significance (P value)
Plaque index*			
ACB/GTR	0.49 ± 0.10	0.45 ± 0.07	>.05
	0.50 (0.40-0.70)	0.40 (0.40-0.60)	
ACB	0.52 ± 0.08	0.48 ± 0.08	>.05
	0.50 (0.40-0.60)	0.50 (0.40-0.60)	
Gingival index*			
ACB/GTR	1.18 ± 0.12	0.32 ± 0.09	<.01
	1.20 (1.00-1.40)	0.30 (0.20-0.50)	
ACB	1.13 ± 0.12	0.36 ± 0.09	<.01
	1.10 (1.00-1.30)	0.35 (0.20-0.50)	

Data are expressed as the means±standard deviation and medians (minimum-maximum).

ACB: autogenous cortical bone GTR: guided tissue regeneration.

*: No significant difference between the values of the groups ($P>.05$).

radiographic evaluation are equally indicative of the outcome of periodontal therapies. When interpreting the findings of the present study, it should also be noted that the changes in the CAL are in agreement with the gain in the radiographic alveolar bone height. In addition, postsurgical healing indicated an excellent soft tissue response to both treatments with no adverse complications.

Radiographic changes in the alveolar bone height may also be used when a reentry procedure is not performed. In the present study, reentry surgery was not performed for ethical reasons and the probability of further alveolar bone loss.³⁷ Instead, the split-mouth design was used in the same patient to ensure that the defects were comparable and had the same healing potential.

The polylactic acid barrier membrane was selected for GTR because this type of barrier is successful in regenerative periodontal therapy³⁸⁻⁴⁰ and shows effective clinical results similar to

nonabsorbable barriers.^{41,42} Such a barrier is easily adaptable to the defect and absorbed by rate-controlled hydrolysis.⁴⁰

Root resorption and ankylosis have been observed in animal and human studies after the use of autogenous bone grafts.^{43,44} However, via an experimental study, it was suggested that autogenous bone grafts from intraoral sources do not induce ankylosis.⁴ In the present study, there was no evidence of ACB graft-induced root resorption and ankylosis, which appears to occur at sites where bone formation takes place without regeneration of periodontal ligament.⁴⁵

The ACB graft used in the present study was obtained from the buccal cortical plate adjacent to the intraosseous defect. The use of an ACB graft avoids the need for a second surgical region, compared with an autogenous bone graft harvested from an extraoral or intraoral (e.g., mandibular symphysis, maxillary tuberosity) region. Despite the increased

Table 3. Clinical and radiological findings of intraosseous defects (mm).

	Preoperative	Postoperative 6 months	Significance (P value)	Difference
PPD*				
ACB/GTR	7.75±0.97 8.0 (6.0-9.0)	3.17±0.58 3.0 (2.0-4.0)	<.01	4.58±1.08 4.5 (3.0-6.0)
ACB	7.92±1.00 8.0 (6.0-10.0)	3.00±0.74 3.0 (2.0-4.0)	<.01	4.92±1.00 5.0 (3.0-6.0)
CAL*				
ACB/GTR	8.67±0.78 9.0 (7.0-10.0)	4.42±0.67 4.0 (4.0-6.0)	<.01	4.25±1.06 4.5 (3.0-6.0)
ACB	8.67±0.78 8.5 (8.0-10.0)	4.17±0.72 4.0 (3.0-5.0)	<.01	4.50±0.80 5.0 (3.0-5.0)
REC*				
ACB/GTR	0.92±0.67 1.0 (0.0-2.0)	1.25±0.62 1.0 (0.0-2.0)	<.05	-0.33±0.49 0.0 (-1.0-0.0)
ACB	0.75±0.75 1.0 (0.0-2.0)	1.17±0.83 1.0 (0.0-2.0)	<.05	-0.42±0.51 0.0 (-1.0-0.0)
RABL*				
ACB/GTR	9.17±3.01 8.0 (6.0-15.0)	3.67±0.98 3.0 (3.0-6.0)	<.01	5.50±2.24 5.0 (3.0-10.0)
ACB	9.92±2.71 10.0 (6.0-15.0)	4.00±1.13 4.0 (2.0-6.0)	<.01	5.92±1.83 6.0 (3.0-9.0)

Data are expressed as the means ± standard deviation and medians (minimum-maximum).

ACB: autogenous cortical bone GTR: guided tissue regeneration.

PPD: probing pocket depth CAL: clinical attachment level REC: gingival recession RABL: radiological alveolar bone level.

*: No significant difference between the values of the groups (P>.05).

number of clinical and experimental studies using ACB grafts for periodontal regenerative therapy in the recent years,^{11,13,46} an ACB graft is reportedly osteoconductive but not osteogenic, because only few cells can survive.^{11,47} In an experimental study using a dog model with surgically created Class II furcation defects, periodontal healing was similar irrespective of the use of surgical debridement alone, ACB grafting, or ACB grafting with a calcium sulfate barrier.¹¹ Moreover, there is evidence that the combination of an ACB graft and an enamel matrix derivative in the treatment of deep periodontal intraosseous defects leads to a significant improvement in clinical parameters.^{13,46}

The results of the present study confirm the findings of a recent randomized controlled clinical trial that evaluated the adjunctive effect of GTR using a polylactic acid barrier combined with autogenous bone grafting in the treatment of deep intrabony periodontal defects.⁴⁸ Autogenous bone was harvested from the chin area in this study.⁴⁸ From the clinician's perspective, it is noteworthy that the PPD reduction and CAL gain in both the treatment modalities are somewhat greater than those in the previous study.⁴⁸ The results obtained from this clinical study might have been influenced by the defect characteristics and center and/or operator effect, which may depend on differences among the enrolled patients, technical ability, clinical organization, and experience of the clinicians or a combination of these factors.⁴⁹

CONCLUSIONS

Within the limitations of the study, both ACB grafting with GTR and ACB grafting alone led to similar improvements in the clinical and radiographic parameters at 6 months postoperatively, indicating that the combined approach does not provide an additional benefit over ACB grafting alone in the treatment of intraosseous periodontal defects. An ACB graft, which is particulate, easy to manipulate, and highly resorbable as well as does not need a second surgical site, can be selected alone for periodontal regenerative therapy. Moreover, an ACB graft is considered to be a useful regenerative material for patients as it is cheaper than the other bone graft materials and completely safe, and eliminates concerns about disease transmission and immunogenic reactions associated with allogeneic or xenogeneic preparations.

ACKNOWLEDGMENTS

We thank Prof. I. Sina Uckan (Department of Oral and Maxillofacial Surgery, Faculty of Dentistry, University of Baskent, Ankara, Turkey) for his contribution to the study.

REFERENCES

1. Socransky SS, Haffajee AD. The nature of periodontal disease. *Ann Periodontol* 1997;2:3-10.
2. Flemmig TF. Periodontitis. *Ann Periodontol* 1999;4:32-38.
3. Karring T, Lindhe J, Cortellini P. Regenerative periodontal therapy. In: Lindhe J, Karring T, Lang NP, editors. *Clinical Periodontology and Implant Dentistry*, 4th edn. Oxford, UK: Wiley-Blackwell Publishing Ltd. 2003;650-704.
4. Kim CS, Choi SH, Cho KS, Chai JK, Wikesjö UM, Kim CK. Periodontal healing in one-wall intra-bony defects in dogs following implantation of autogenous bone or a coral-derived biomaterial. *J Clin Periodontol* 2005;32:583-589.
5. Ivanovski S, Li H, Daley T, Bartold PM. An immunohistochemical study of matrix molecules associated with barrier membrane-mediated periodontal wound healing. *J Periodontol Res* 2000;35:115-126.
6. Gottlow J, Nyman S, Lindhe J, Karring T, Wennström J. New attachment formation in the human periodontium by guided tissue regeneration. Case reports. *J Clin Periodontol* 1986;13:604-616.
7. Cortellini P, Clauser C, Prato GP. Histologic assessment of new attachment following the treatment of a human buccal recession by means of a guided tissue regeneration procedure. *J Periodontol* 1993;64:387-391.
8. Cortellini P, Carnevale G, Sanz M, Tonetti MS. Treatment of deep and shallow intrabony defects. A multicenter randomized controlled clinical trial. *J Clin Periodontol* 1998;25:981-987.
9. Aimetti M, Romano F, Pigella E, Pranzini F, Debernardi C. Treatment of wide, shallow, and predominantly 1-wall intrabony defects with a bioabsorbable membrane: a randomized controlled clinical trial. *J Periodontol* 2005;76:1354-1361.
10. MacNeill SR, Cobb CM, Rapley JW, Glaros AG, Spencer P. In vivo comparison of synthetic osseous graft materials. A preliminary study. *J Clin Periodontol* 1999;26:239-245.
11. Deliberador TM, Nagata MJ, Furlaneto FA, Melo LG, Okamoto T, Sundfeld ML, et al. Autogenous bone graft with or without a calcium sulfate barrier in the treatment of Class II furcation defects: a histologic and histometric study in dogs. *J Periodontol* 2006;77:780-789.

12. Carranza FA, Takei HH, Cochran DL. Reconstructive periodontal surgery. In: Newman MG, Takei HH, Klokkevold PR, Carranza FA, editors. *Clinical Periodontology*, 10th edn. St. Louis, Missouri, USA: Saunders 2006;968-990.
13. Guida L, Annunziata M, Belardo S, Farina R, Scabbia A, Trombelli L. Effect of autogenous cortical bone particulate in conjunction with enamel matrix derivative in the treatment of periodontal intraosseous defects. *J Periodontol* 2007;78:231-238.
14. Marx RE. Clinical application of bone biology to mandibular and maxillary reconstruction. *Clin Plast Surg* 1994;21:377-392.
15. Chan C, Thompson I, Robinson P, Wilson J, Hench L. Evaluation of Bioglass/dextran composite as a bone graft substitute. *Int J Oral Maxillofac Surg* 2002;31:73-77.
16. Blumenthal N, Steinberg J. The use of collagen membrane barriers in conjunction with combined demineralized bone-collagen gel implants in human intrabony defects. *J Periodontol* 1990;61:319-327.
17. Chen CC, Wang HL, Smith F, Glickman GN, Shyr Y, O'Neal RB. Evaluation of a collagen membrane with and without bone grafts in treating periodontal intrabony defects. *J Periodontol* 1995;66:838-847.
18. Trejo PM, Weltman R, Caffesse R. Treatment of intraosseous defects with bioabsorbable barriers alone or in combination with decalcified freeze-dried bone allograft: a randomized clinical trial. *J Periodontol* 2000;71:1852-1861.
19. Paolantonio M. Combined periodontal regenerative technique in human intrabony defects by collagen membranes and anorganic bovine bone. A controlled clinical study. *J Periodontol* 2002;73:158-166.
20. Donos N, Kostopoulos L, Karring T. Augmentation of the mandible with GTR and onlay cortical bone grafting. An experimental study in the rat. *Clin Oral Implants Res* 2002;13:175-184.
21. Donos N, Kostopoulos L, Karring T. Alveolar ridge augmentation using a resorbable copolymer membrane and autogenous bone grafts. An experimental study in the rat. *Clin Oral Implants Res* 2002;13:203-213.
22. Orsini M, Orsini G, Benloch D, Aranda JJ, Lazaro P, Sanz M, et al. Comparison of calcium sulfate and autogenous bone graft to bioabsorbable membranes plus autogenous bone graft in the treatment of intrabony periodontal defects: a split-mouth study. *J Periodontol* 2001;72:296-302.
23. Froum SJ, Thaler R, Scopp IW, Stahl SS. Osseous autografts. I. Clinical responses to bone blend or hip marrow grafts. *J Periodontol* 1975;46:515-521.
24. Froum SJ, Thaler R, Scopp IW, Stahl SS. Osseous autografts. II. Histological responses to osseous coagulum-bone blend grafts. *J Periodontol* 1975;46:656-661.
25. Stahl SS, Froum SJ, Kushner L. Healing responses of human intraosseous lesions following the use of debridement, grafting and citric acid root treatment. II. Clinical and histologic observations: one year postsurgery. *J Periodontol* 1983;54:325-338.
26. Movin S, Borring-Møller G. Regeneration of intrabony periodontal defects in humans after implantation of allogenic demineralized dentin. *J Clin Periodontol* 1982;9:141-147.
27. Silness J, Løe H. Periodontal disease in pregnancy. II. Correlation between oral hygiene and periodontal condition. *Acta Odontol Scand* 1964;22:121-135.
28. Løe H, Silness J. Periodontal disease in pregnancy. I. Prevalence and severity. *Acta Odontol Scand* 1963;21:533-551.
29. Keles GC, Cetinkaya BO, Albayrak D, Koprulu H, Acikgoz G. Comparison of platelet pellet and bioactive glass in periodontal regenerative therapy. *Acta Odontol Scand* 2006;64:327-333.
30. Steffensen B, Webert HP. Relationship between the radiographic periodontal defect angle and healing after treatment. *J Periodontol* 1989;60:248-254.
31. Liñares A, Cortellini P, Lang NP, Suvan J, Tonetti MS; the European Research Group on Periodontology (ErgoPerio). Guided tissue regeneration/deproteinized bovine bone mineral or papilla preservation flaps alone for treatment of intrabony defects. II: radiographic predictors and outcomes. *J Clin Periodontol* 2006;33:351-358.
32. Sculean A, Chiantella GC, Windisch P, Arweiler NB, Brex M, Gera I. Healing of intra-bony defects following treatment with a composite bovine-derived xenograft (Bio-Oss Collagen) in combination with a collagen membrane (Bio-Gide PERIO). *J Clin Periodontol* 2005;32:720-724.
33. Lekovic V, Camargo PM, Weinlaender M, Vasilic N, Aleksic Z, Kenney EB. Effectiveness of a combination of platelet-rich plasma, bovine porous bone mineral and guided tissue regeneration in the treatment of mandibular grade II molar furcations in humans. *J Clin Periodontol* 2003;30:746-751.
34. Okuda K, Tai H, Tanabe K, Suzuki H, Sato T, Kawase T, et al. Platelet-rich plasma combined with a porous hydroxyapatite graft for the treatment of intrabony periodontal defects in humans: a comparative controlled clinical study. *J Periodontol* 2005;76:890-898.
35. Listgarten MA, Rosenberg MM. Histological study of repair following new attachment procedures in human periodontal lesions. *J Periodontol* 1979;50:333-344.
36. Zybutz M, Rapoport D, Laurell L, Persson GR. Comparisons of clinical and radiographic measurements of inter-proximal vertical defects before and 1 year after surgical treatments. *J Clin Periodontol* 2000;27:179-186.

37. Zarnet JS, Darbar UR, Griffiths GS, Bulman JS, Bragger U, Burgin W, et al. Particulate bioglass as a grafting material in the treatment of periodontal intrabony defects. *J Clin Periodontol* 1997;24:410-418.
38. Polson AM, Southard GL, Dunn RL, Polson AP. Healing patterns associated with an Atrisorb barrier in guided tissue regeneration. *Compendium* 1993;14:1162, 1164, 1166 passim; quiz 1172.
39. Laurell L, Falk H, Fornell J, Johard G, Gottlow J. Clinical use of a bioresorbable matrix barrier in guided tissue regeneration therapy. Case series. *J Periodontol* 1994;65:967-975.
40. Bogle G, Garrett S, Stoller NH, Swanbom DD, Fulfs JC, Rodgers PW, et al. Periodontal regeneration in naturally occurring Class II furcation defects in beagle dogs after guided tissue regeneration with bioabsorbable barriers. *J Periodontol* 1997;68:536-544.
41. Hugoson A, Ravalid N, Fornell J, Johard G, Teiwik A, Gottlow J. Treatment of class II furcation involvements in humans with bioresorbable and nonresorbable guided tissue regeneration barriers. A randomized multi-center study. *J Periodontol* 1995;66:624-634.
42. Garrett S, Polson AM, Stoller NH, Drisko CL, Caton JG, Harrold CQ, et al. Comparison of a bioabsorbable GTR barrier to a non-absorbable barrier in treating human class II furcation defects. A multi-center parallel design randomized single-blind trial. *J Periodontol* 1997;68:667-675.
43. Schallhorn RG, Hiatt WH. Human allografts of iliac cancellous bone and marrow in periodontal osseous defects. II. Clinical observations. *J Periodontol* 1972;43:67-81.
44. Dragoo MR, Sullivan HC. A clinical and histological evaluation of autogenous iliac bone grafts in humans. II. External root resorption. *J Periodontol* 1973;44:614-625.
45. Wikesjo UM, Lim WH, Thomson RC, Cook AD, Wozney JM, Hardwick WR. Periodontal repair in dogs: evaluation of a bioabsorbable space-providing macroporous membrane with recombinant human bone morphogenetic protein-2. *J Periodontol* 2003;74:635-647.
46. Trombelli L, Annunziata M, Belardo S, Farina R, Scabbia A, Guida L. Autogenous bone graft in conjunction with enamel matrix derivative in the treatment of deep periodontal intra-osseous defects: a report of 13 consecutively treated patients. *J Clin Periodontol* 2006;33:69-75.
47. Bauer TW, Muschler GF. Bone graft materials. An overview of the basic science. *Clin Orthop Relat Res* 2000;371:10-27.
48. Nygaard-ostby P, Bakke V, Nesdal O, Nilssen HK, Susin C, Wikesjo UM. Periodontal healing following reconstructive surgery: effect of guided tissue regeneration using a bioresorbable barrier device when combined with autogenous bone grafting. A randomized controlled clinical trial. *J Clin Periodontol* 2008;35:37-43.
49. Sanz M, Tonetti MS, Zabalegui I, Sicilia A, Blanco J, Rebelo H, et al. Treatment of intrabony defects with enamel matrix proteins or barrier membranes: results from a multicenter practice-based clinical trial. *J Periodontol* 2004;75:726-733.