

Intraluminal injection of indigo carmine facilitates identification of the afferent limb during double-balloon ERCP

Double-balloon endoscopy facilitates endoscopic retrograde cholangiopancreatography (ERCP) in patients with a Roux-en-Y anastomosis [1]. However, it is difficult to identify the afferent limb during double-balloon ERCP [2]. According to retrospective data from February 2007 to January 2009, the rate of accurate identification was 50% (14/28). We report a useful technique to identify the afferent limb of the Roux-en-Y anastomosis during double-balloon ERCP.

In the second portion of the duodenum or at the distal site of the esophagojejunostomy, after inflation of a balloon at the tip of the endoscope to prevent backflow, 50 ml of 0.2% indigo carmine was injected into the lumen using the accessory channel (● Fig. 1). At the Roux-en-Y site, we evaluated the inflow of indigo carmine into both limbs and identified the limb with less inflow as the afferent limb (● Fig. 2).

Between February 2009 and September 2011, this technique was used and evaluated prospectively in 52 consecutive patients with a Roux-en-Y anastomosis. Of the 52, 11 patients were excluded because of the following: unrecognized Roux-en-Y in 3, inaccessible Roux-en-Y in 2, and no indigo carmine at the Roux-en-Y in 6. In 33 of the remaining 41 patients (80%), the afferent limb was accurately identified. In 5 patients, identification was difficult because the amount of inflow was similar in both limbs. In 3 patients, the identification was incorrect.

This technique is based on the theory that little indigo carmine will flow into the afferent limb, but the dye will easily flow into the efferent limb by peristalsis. Double-balloon ERCP is usually performed with the patient in the left lateral position. In some patients, the influence of gravity on the inflow of indigo carmine made identification of the afferent limb difficult or led to incorrect identification.

Intraluminal injection of indigo carmine facilitates identification of the afferent limb during double-balloon ERCP in patients with a Roux-en-Y anastomosis.

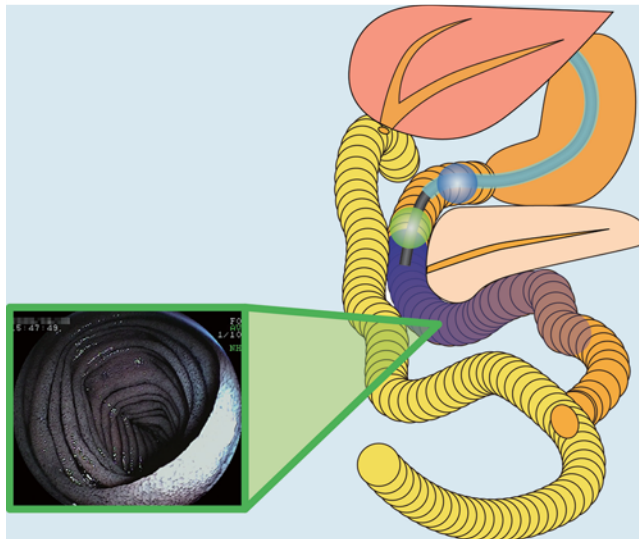


Fig. 1 After inflation of a balloon at the tip of the endoscope to prevent backflow, 50 ml of 0.2% indigo carmine was injected into the lumen using the accessory channel.

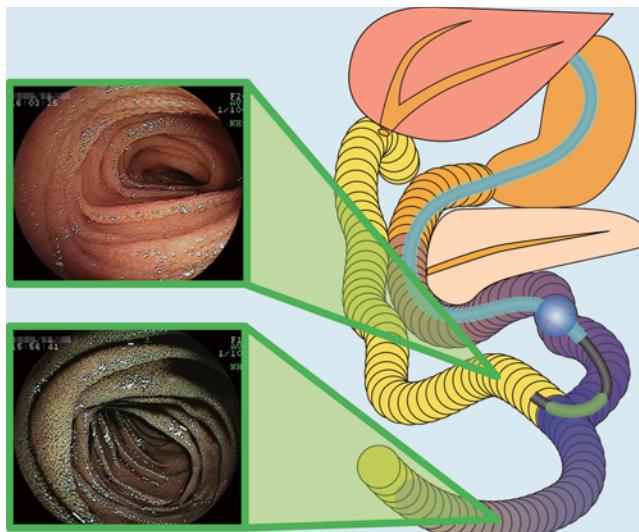


Fig. 2 At the site of the Roux-en-Y anastomosis, we evaluated the inflow of indigo carmine into both limbs and identified the limb with less inflow as the afferent limb.

Endoscopy_UCTN_Code_TTT_1AR_2AK

Competing interests: Yamamoto has applied for a patent in Japan for the double-balloon system described in the article. All other authors disclosed no financial relationships relevant to this publication.

T. Yano, H. Hatanaka, H. Yamamoto, K. Nakazawa, N. Nishimura, S. Wada, K. Tamada, K. Sugano

Department of Medicine, Division of Gastroenterology, Jichi Medical University, Shimotsuke, Tochigi, Japan

Acknowledgments

▼ We thank Professor Alan Lefor of the Department of Surgery at Jichi Medical University for language editing of the manuscript.

References

- 1 Haruta H, Yamamoto H, Mizuta K et al. A case of successful enteroscopic balloon dilation for late anastomotic stricture of choledochojejunostomy after living donor liver transplantation. *Liver Transpl* 2005; 11: 1608–1610
- 2 Shimatani M, Matsushita M, Takaoka M et al. Effective “short” double-balloon enteroscope for diagnostic and therapeutic ERCP in patients with altered gastrointestinal anatomy: a large case series. *Endoscopy* 2009; 41: 849–854

Bibliography

DOI <http://dx.doi.org/10.1055/s-0032-1309865>
Endoscopy 2012; 44: E340–E341
© Georg Thieme Verlag KG
Stuttgart · New York
ISSN 0013-726X

Corresponding author

T. Yano, MD, PhD
Department of Medicine
Division of Gastroenterology
Jichi Medical University
3311-1 Yakushiji, Shimotsuke
Tochigi 329-0498
Japan
Fax: +81-285-44-8297
tomonori@jichi.ac.jp