

# Environmental dermatology: skin manifestations of injuries caused by invertebrate aquatic animals\*

Dermatologia ambiental: manifestações dermatológicas de acidentes por animais aquáticos (invertebrados)

Vidal Haddad Junior<sup>1</sup>

DOI: <http://dx.doi.org/10.1590/abd1806-4841.20132587>

**Abstract:** Contact between humans and coastal areas has increased in recent decades, which has led to an increase in injuries from aquatic animals. The majority of these present dermatological manifestations, and some of them show typical lesions. The highest percentages of injuries that occur in marine environments are associated with invertebrates such as sea urchins, jellyfish and Portuguese men-of-war (echinoderms and cnidarians). In this review, we discuss the clinical, therapeutic and preventive aspects of injuries caused by marine and freshwater invertebrates, focusing on first aid measures and diagnosis for dermatologists and professionals in coastal areas.

**Keywords:** Cnidaria; Echinodermata; Invertebrates; Marine fauna; Sea urchins; Skin manifestations; Venomous animals

**Resumo:** O contato entre a Humanidade e as áreas litorâneas vem aumentando nas últimas décadas e com isso também aumentaram os acidentes por animais aquáticos. A maioria destes apresenta manifestações dermatológicas, sendo algumas bem características. As maiores porcentagens das lesões em ambientes marinhos estão associadas aos invertebrados, como os ouriços-do-mar, águas-vivas e caravelas (equinodermos e cnidários). Nesta revisão, são discutidos os aspectos clínicos, terapêuticos e preventivos de acidentes por invertebrados marinhos e fluviais e ressaltados os primeiros cuidados e os auxílios diagnósticos para os dermatologistas e profissionais das áreas litorâneas.

**Palavras-chave:** Animais peçonhentos ; Cnidários; Equinodermos; Fauna marinha; Invertebrados; Manifestações cutâneas; Ouriços-do-Mar

## INTRODUCTION

Due to the growing interface between humans and aquatic environments, interest in this topic has increased in recent years. Brazil has a coastline of about 8,500 kilometers and the most extensive freshwater ecosystem in the world.<sup>1-5</sup> Thus, there is a varied fauna, encompassing animals of temperate and tropical waters, including many potentially dangerous animals that come into contact with humans due to the large influx of swimmers to beaches, the increase in

commercial and sport fishing, and other activities such as scuba diving and underwater fishing.<sup>1-5</sup>

Toxins are substances produced by animals that, within the body of another animal, react with certain cells and organs, causing deleterious effects. Poisons are toxins that cause harm when ingested, as happens with puffer fish and toads. Venoms are toxins that cause effects after being injected through spikes, fangs or stingers. The action of toxins varies, but the

Received on 05.03.2013.

Approved by the Advisory Board and accepted for publication on 13.03.2013.

\* Study carried out at the Botucatu Medical School - Universidade Estadual de São Paulo "Julio de Mesquita Filho" (UNESP) - Botucatu (SP), Brazil.

Financial Support: None.

Conflict of Interests: None.

<sup>1</sup> Associate Professor - MD, MSc, PhD - Department of Dermatology - Botucatu Medical School - Universidade Estadual de São Paulo "Júlio de Mesquita Filho" (UNESP) - Botucatu (SP), Brasil.

©2013 by Anais Brasileiros de Dermatologia

main effects are neurotoxic, proteolytic, myotoxic, hemotoxic (hemolytic) and cytotoxic. The aquatic animals that are dangerous to humans, grouped together according to the frequency and severity of accidents, are: sponges, cnidarians, worms, mollusks, echinoderms, crustaceans, fish and reptiles.<sup>1,5</sup>

## EPIDEMIOLOGY

Accidents involving invertebrates aquatic animals (especially marine animals) reach their peak during the summer, when the population of some coastal towns increases approximately tenfold, or more. However, most animals that cause accidents do not vary in number during the year's seasons, and the large number of cases during this period is due to the number of humans in the water, lack of information and precautions regarding these animals. Bathers constitute more than 90% of the victims and the incidence of this type of accident is 0.1%, or 1 in 1,000, in emergency units. This is a high number, and during the holiday season, it happens that up to 3,000 people a day are treated at one emergency unit<sup>1,5</sup> Among the victims, approximately 50% are bathers who step on sea urchins and presenting traumatic accidents, 25% are bathers who have contact with cnidarians (jellyfish and Portuguese men-of-war) and 25% are fishermen injured by venomous fish, such as catfish and stingrays.<sup>1,5</sup>

## PHYLUM PORIFERA (Sponges)

Marine sponges are simple animals, with a circular body and "skeleton", consisting of calcium carbonate, silica and spongin. Sponges have a species of irritating slime on the surface of the skeleton, and the spikes of the body contribute to this.<sup>1,5</sup> The sponges associated with lesions in humans are of the genera *Neofibularia* sp, *Tedania ignis* (the fire sponge) and *Microciona prolifera*, the red sponge (Figure 1).



FIGURE 1: Top-left: marine sponge. Below: freshwater sponge (cauxi). Right: details of sponges. Photos: Vidal Haddad Junior

The dermatitis caused by the contact with sponges has an eczematous pattern, appearing rapidly (within 1-3 hours). In the affected areas, there is erythema and edema, forming papules that subsequently give rise to plaques, vesicles, and, more rarely, blisters (Figure 2). Itching is intense and the cure for the dermatitis develops in about two weeks. The most common location is in the hands and there are no systemic complications, but the dermatitis may be associated with complications such as erythema multiforme, severe conjunctivitis, local hyperpigmentation and anaphylactoid reactions.<sup>1,5</sup> Adhesive tape is recommended for the removal of micro spines, along with corticosteroid creams and cold compresses to relieve local inflammation.<sup>2,6</sup> The rare accidents observed by the author concerned biologists who collected sponges.<sup>2</sup>

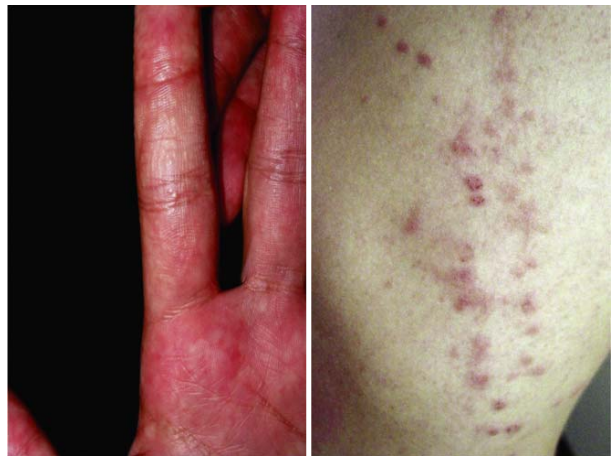

FIGURE 2: Left: eczema-like plaques on the hand of a biology student who collected marine sponges for research. Right: disseminated excoriated papules in a swimmer after diving in a lake in the Amazon region. Photos: Vidal Haddad Junior

Sponges also exist in freshwater environments and some species can cause irritating skin disorders similar to those caused by marine sponges.<sup>4</sup> Belonging to the class Demospongiae, they are popularly called *cauxi* in the Amazon region and *pó-de-mico* (monkey powder) in savannah-like areas cerrados (savannah-like environments), and are found in the ponds of these ecosystems (Figure 1). Lesions caused by freshwater sponges are disseminated, manifesting as pruritic erythematous papules surmounted by vesicles, and may also present exulcerations, crusts and secondary infections.<sup>4</sup> All skin and mucous membranes can come into contact with the spicules of sponges, which occurs in the baths in pools and rivers (Figure 2). Another interesting aspect is the manifestation of lesions, caused by freshwater sponges, in the hands of indigenous Brazilians in the Amazon region, who use

the silica "skeleton" of the sponges to confer resistance to ceramics, manipulating them for this purpose. Treatment for injuries caused by marine sponges is effective. If manifestations are severe, it is important to use systemic corticosteroids, 30 to 40mg of prednisone per day for approximately a week, with gradual withdrawal. The problem seems to be common in some regions but there is a lack of additional studies, including definitive proof of the etiology through finding spicules in injuries. A study of human eye injuries (uveitis and leukomas) in riverside people, associated the lesions with the presence of spicules from two freshwater sponges (*Drulia uruguayensis* and *D. ctenosclera*). The findings were confirmed by a histopathology exam of the lesions, demonstrating the etiology of the ophthalmic processes.<sup>7,8</sup>

### PHYLUM CNIDARIANS (Jellyfish and Portuguese men-of-war)

Cnidarians are gelatinous animals with dimorphic life cycles. They can appear in free or medusa form (jellyfish), reproduced sexually; or in the form of polyps, which are fixed and reproduce asexually. Four types are important for medicine: Anthozoa (corals and anemones that do not appear in medusa form), Hydrozoa, Scyphozoa and Cubozoa (cubomedusae).

These animals have highly specialized defense cells called cnidocytes, which include nematocysts, composed of small distal spicules in a spiral structure and kept under pressure, triggering changes in pressure and/or osmosis, which can lead to the inoculation of venom into the dermis of the victim. A cnidarian with long tentacles can have millions of nematocysts. When an accident happens, many nematocysts initially remain intact in the victim's skin, without discharging its contents.

The venom of nematocysts contains tetramine, 5-hydroxytryptamine, histamine and serotonin, as well as thermolabile high molecular weight toxins, capable of changing ionic permeability and causing cardiac dysfunction.<sup>9</sup> The venom can also cause hemolysis and renal failure, which develops in later phases.<sup>10</sup> Nontoxic proteins can trigger allergic processes of varying severity.<sup>1-5</sup> The concentration and potency of the venom varies according to a scale, from corals and anemones to Portuguese men-of-war and some jellyfish.<sup>1-5</sup>

The signs and symptoms of envenomation depend of a toxic action (immediate) and an allergic action (immediate and delayed). Intense and immediate pain occurs in areas that come into contact with the animal, along with a burning sensation (but it should not be called a burn, because is an action of toxins), a linear erythematous papular rash, urticariform, with crossed lines. In this initial stage, there may be horripiation, probably from alteration of the sympathetic

nervous system.<sup>1-5</sup> Within a matter of hours, the area may present vesicles, blisters and even superficial necrosis. The pain subsists for hours and systemic phenomena can be installed, such as general disorganization of nerve activity, heart failure (rare), shock, respiratory failure, hemolysis and renal abnormalitie, which are responsible for cardiopulmonary deaths in severe cases. Cubomedusae (*Chironex fleckeri*, *Chiropsalmus quadrumanus* and *C. quadrigatus*, *Tamoya haplonema* and others) and the Portuguese man-of-war (*Physalia physalis* and *P. utriculus*) can cause accidents of this magnitude (Figures 3 and 4).<sup>11-15</sup> There are hundreds of documented deaths caused by contact with cubomedusae worldwide. Most of them are caused by the species *Chironex fleckeri*, in the Indo-Pacific region.<sup>10</sup> There are also reports of deaths related to accidents with Portuguese men-of-war (*Physalia physalis*) and cubomedusa *Chiropsalmus quadrumanus*, in the Atlantic Ocean.<sup>2,16</sup>

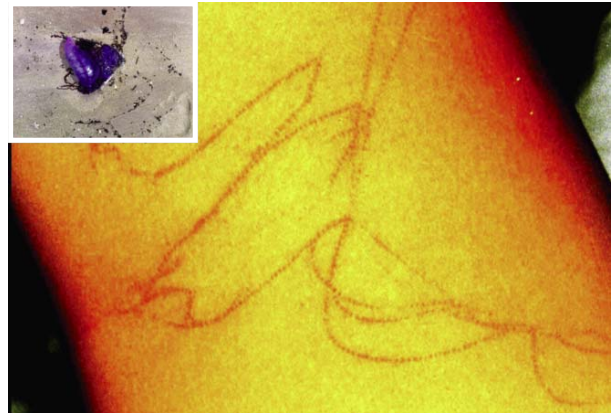


FIGURE 3: Linear and long crisscrossed plaques after the contact of a bather with a Portuguese man-of-war. In detail: *Physalia physalis*, the Portuguese man-of-war. Photos: Shirlei Pacheco and André Rossetto

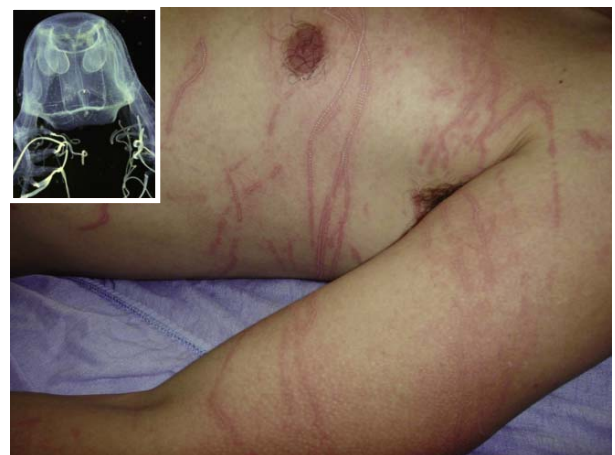

FIGURE 4: Linear plaques of large diameter and crossed with "frozen" element, which arose after contact with the cubomedusa *Chiropsalmus quadrumanus*, present on the Brazilian coast (see detail). Photos: Vidal Haddad Junior and Álvaro Migotto

After the accident, immediate allergic reactions can occur, such as angioedema and anaphylaxis. There are late allergic reactions: persistent lesions after 48 hours, new lesions at distance, recurrent reactions (four or more), contact dermatitis or late onset of new lesions. Ingestion of jellyfish is observed in oriental cuisine, and has been associated with gastrointestinal and skin allergies.<sup>17</sup>

Contact accompanied by pain and rounded or small tentacle marks, suggests envenomation by *Olindias sambaquiensis*, a common hydrozoan in the South and Southeast regions of Brazil, which is constantly associated with serial injuries on our beaches, accounting for about 80% of accidents in these regions (Figure 5).<sup>12,15,18</sup>

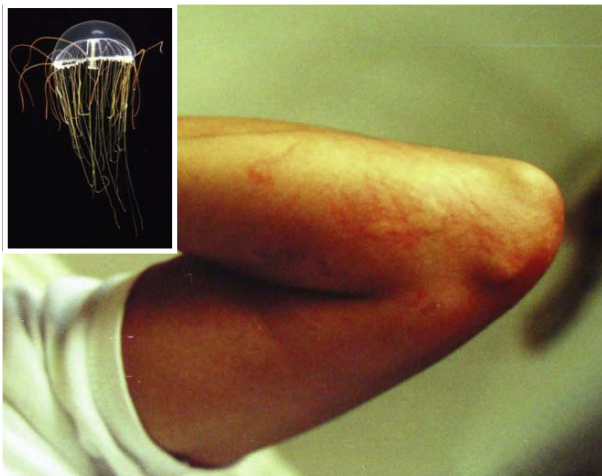


FIGURE 5: Rounded or oval plaques and small linear marks indicate envenomation by *Olindias sambaquiensis*, a common hydrozoan in southeastern and southern regions of Brazil (see detail). Photos: João Luiz Costa Cardoso e Álvaro Migotto

The larvae of the jellyfish *Linuche unguiculata*, a small scyphomedusa, were involved in the genesis of the seabather's eruption, a pruritic erythematous papular eruption that develops in areas covered by swimsuits (Figure 6). This dermatitis was first described in Brazilian bathers in Ubatuba (São Paulo State).<sup>19</sup> Recently, new cases have been reported on the coast, especially in the South of the country, suggesting that the disease is far more common than previously thought.<sup>20,21</sup>

Envenomation by anemones can be severe, though this usually causes mild manifestations. Erythematous, irregular and painful plaques and papules arise at points of contact with the short tentacles of anemones. Fire corals (*Millepora* sp) are hydrozoans that cause severe and extensive envenoming, and can provoke medical emergencies. True corals cause minor accidents, but can bring about deep wounds in bathers. There is a report of a fatal accident

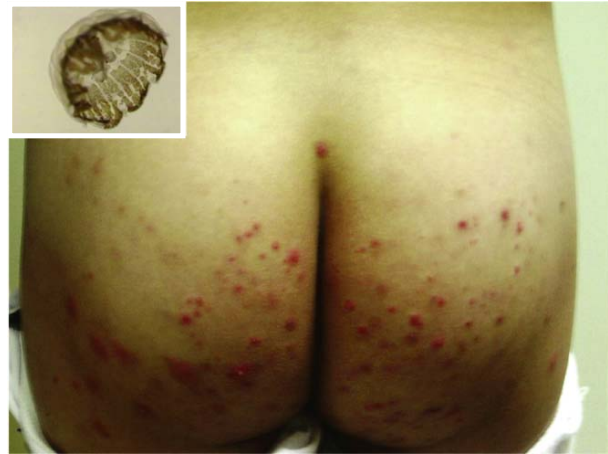

FIGURE 6: Excoriated papules in areas covered by swimsuits are typical of seabather's eruption. In detail: *Linuche unguiculata*, the thimble jellyfish, whose larvae and adult forms cause the dermatitis. Photos: João Luiz Costa Cardoso and Álvaro Migotto

by fulminant hepatic failure, following a diver's contact with an anemone (*Condylactis* sp).<sup>22</sup>

Accidents involving some hydrozoans, true corals, anemones and fire corals, show no typical pattern. Marks are irregular and can be rounded, oval shaped or without any defined form.<sup>23</sup> These accidents should be emphasized to divers who approach the underwater substrate and experience local pain and burning, as well as rapid onset of lesions.

The most common complication of accidents involving cnidarians is the residual hyperpigmentation, but keloids, atrophy of subcutaneous tissue and gangrene, may also arise.<sup>1-5</sup> Cuts from corals can develop a foreign body granulomatous reaction.

Immunologic methods to aid diagnosis are few: there is a serum test via the enzyme-linked immunosorbent assay (ELISA) method, which shows the etiology of seabather's eruption.<sup>24</sup> Histological exams can help diagnose late allergic phenomena, as well as contact tests. Some species of cnidarians were identified from the recovery nematocysts in human skin, through the adhesive tape method.

Controversy surrounds the treatment of envenomation by cnidarians: in all accidents, compresses of iced sea water or cold packs, with protection using a thin cloth, should be applied, so that freshwater does not reach the wounded area. This measure has a potent analgesic effect and should always be applied, even at beaches, as a routine first aid step.<sup>1-5,12,15</sup> The application of fresh water onto the skin triggers loaded nematocysts by osmosis. However, there is a randomized trial showing that the immersion of the affected area in hot water (45° C) for 20 minutes would be more effective than cold water immersion.<sup>25</sup> Our view is that what interferes with the nociceptive

activity of the venom, are extreme temperatures, since cold water also has a positive analgesic effect, as evidenced by earlier studies.<sup>1-5,12,15</sup>

When the animal involved is a cubomedusa (*Chironex fleckeri*, *Carukia barnesi*, *Tamoya haplonema* or *Chiropsalmus quadrumanus*), it is crucial to apply 5% acetic acid (vinegar), in order to inactivate nematocysts that are still intact on the skin or any remaining tentacles. In cases of envenomation by Portuguese men-of-war (*Physalia physalis*) or *Olindias sambaquiensis*, this course of action is less safe, since *in vitro* experiments have shown that the nematocysts of some specimens of Portuguese men-of-war fire when placed in solutions of vinegar or alcohol.<sup>26</sup> In our clinical experience, however, the application of vinegar is a beneficial measure for any accident caused by cnidarians on the Brazilian coast.<sup>1-5,12,15</sup>

Other measures such as the use of antihistamines, urine, alcohol or Coca-Cola®, are not scientifically endorsed and should not be applied, so as to avoid worsening of the condition and generally inadequate treatment. Patients with systemic manifestations (hypotension / hypertension, cardiac arrhythmias, pulmonary edema) should be referred urgently to a hospital, which can be useful if pain persists after first aid measures (in these cases, an intramuscular dipyrone ampoule seems to control pain). Cardiac arrhythmias should be treated with intravenous use of verapamil.

Accidents caused by cnidarians are easy to identify, following the classic pattern of erythematous crossed lines that arise soon after contact, accompanied by intense pain. There is a pattern in the clinical manifestations caused by cnidarians in Brazil and throughout the South Atlantic, as well as North and Central America: few, long and crisscrossed lines, suggesting cubomedusae and Portuguese men-of-war (severe envenomation, excruciating pain and systemic phenomena). The presence of the Portuguese man-of-war's float inculpates the animal. Rounded skin lesions with impressions of small tentacles without systemic phenomena, are suggestive of accidents caused by *Olindias sambaquiensis*, a very common hydrozoan on the Atlantic coast of South America.<sup>15</sup>

#### PHYLUM ANNELIDA (Leeches and polychetas)

Leeches belong to the subclass Hirudinea (Figure 7). These worms, which can reach 10cm in length, are cosmopolitan and found in freshwater (although they may exist in marine and even arboreal environments). The parasite species clings firmly onto creatures via oral and caudal suckers, and jaws equipped with sharp teeth, feeding on blood. A leech can ingest up to ten times its weight in blood, but does not cause major problems in the victims. The thera-

peutic use of these worms was widespread in antiquity, when bloodletting was carried out in patients, using the species *Hirudo medicinalis*. The saliva of leeches contains hirudin, an anticoagulant substance that prevents blood clotting in their digestive tract. Allergies and infections may also occur.<sup>2-5</sup>

Marine worms are similar to land worms (Figure 7). The most representative are marine brush worms, which can injure unsuspecting divers with bites from powerful jaws, with chitinous teeth, and introduce setae or spicules into the skin, causing edema, papules, itching and pain, which can lead to skin necrosis.



FIGURE 7: Top-left: leeches. Polychaetes (brushworms and smooth worms). Marine worms cause injury through biting and penetration by the body bristles. Photos: Vidal Haddad Junior

Leeches should be removed by applying alcohol or the heat of a flame, near the animal. Mechanical removal of leeches should be avoided, as there is a risk of trauma. Topical antibiotics should be applied to the affected area for around seven days. Wounds from marine worm bites should be washed extensively, followed by the application of topical antibiotics. The skin harmed by spicules should be dealt with using tweezers and adhesive tape, with the aim of removing the bristles. Marine worms are common on our coast and mussel catchers are often in contact with these animals, though injuries are rare. Other people who experience contact include marine wildlife researchers and divers.<sup>2-5</sup>

### PHYLUM MOLLUSCA (*Octopus* and *Conus* snails)

Mollusks are organisms that may or may not have shells to protect their bodies. Some gastropods (with only one shell) can inject venom. Among these, the *Conus* genus causes serious envenomation, inoculating venom via a spike (radula) contained in a proboscis, a tube in the distal end of the body. The venom of *Conus* snails is composed of low molecular weight neurotoxins that can induce neuromuscular blockades and progressive paralysis, even affecting respiratory muscles, culminating in sporadic death. The action is very quick and it occurs through blocking of receptors of sodium, potassium and calcium channels, present in muscles and nerves.<sup>2-5,10</sup>

The exact number of proven deaths caused by accidents with *Conus* is not known, though it is estimated to be about 50. The history of contact with the mollusk associated with muscle weakness points to the occurrence of accidents.<sup>1-5</sup>

The most venomous species of *Conus* feed on fish. In Brazil, most species feed on worms and other mollusks. Some well-known species such as *Conus clerii*, *Conus regius* and *Conus jaspideus*, depend on the capture of polychaetes (Figure 8). There are two Atlantic Ocean species of large diameter: *Conus centurio* and *Conus ermineus*, the latter being clearly piscivorous.<sup>27</sup> Recently, an accident caused by *Conus regius* was reported in Brazil.<sup>28</sup>

The blue-ringed octopus (*Hapalochlaena* sp) belongs to the Cephalopoda class and it inoculates a powerful neurotoxin that blocks sodium channels in axons and causes muscle paralysis similar to that observed in accidents caused by *Conus*. There are no blue-ringed octopuses in the Atlantic Ocean.

The common octopus (*Octopus* sp) is found worldwide and it has recently been described as a venomous animal, carrying cephalotoxin, a neurotoxin that helps the octopus to catch its prey (Figure 8).<sup>29</sup> The author noted a case of envenomation in a young woman, following consumption of raw (common) octopus meat (Japanese cuisine), which presented generalized neurotoxicity manifested by paresthesias (including perioral), malaise, dizziness, diarrhea and muscle weakness without paralysis.<sup>29</sup> An injury caused by the "beak" of an octopus in the hand of a patient provoked an area of induration and erythema measuring about 8.0 cm, which persisted for weeks. Suckers in tentacles can cause traumatic purpura, through the strong suction (from published personal communications of the author).

There are no laboratory tests to diagnose accidents caused by *Conus* snails. In envenomation by *Conus* and octopuses, it is important to remove the remaining tissues of the animal in the area of the bite/sting, perform local asepsis and if necessary,



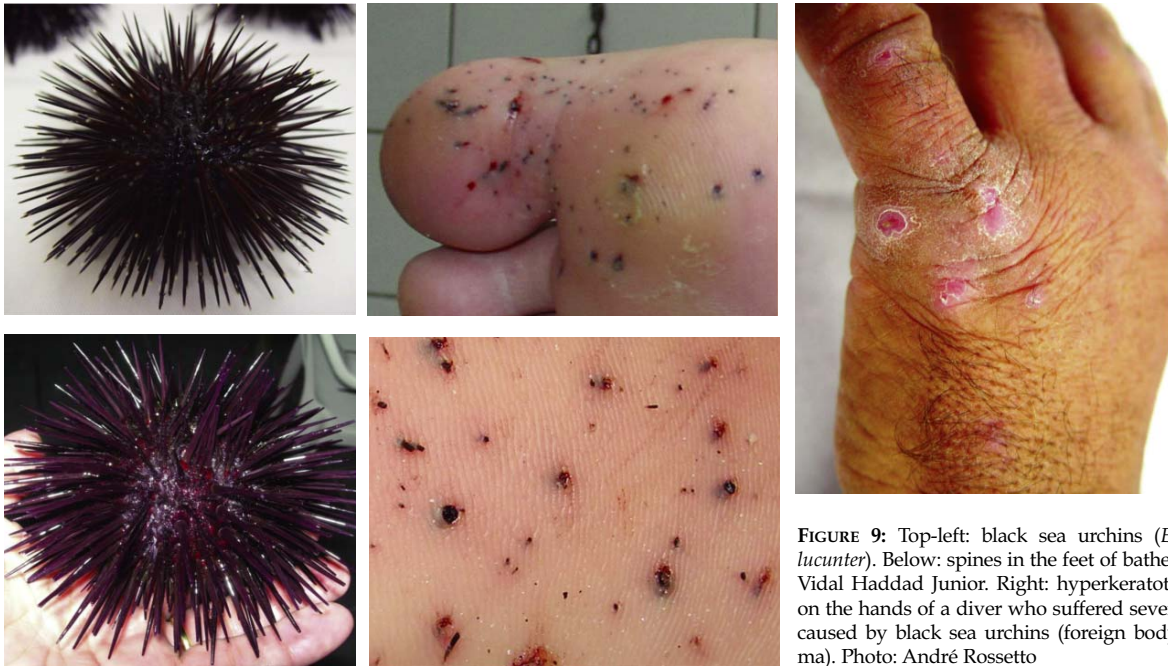
FIGURE 8: *Conus regius* and *Octopus* sp., the common octopus. Photos: Vidal Haddad Junior

apply therapeutic measures for neuromuscular paralysis, including the use of artificial respiration, the only effective means of treatment. The severity depends on the installation of the full manifestations and we should also consider the location of the accident, because a lack of medical resources also influences the prognosis.<sup>2-5, 27, 28, 29</sup>

### PHYLUM ECHINODERMATA (Sea urchins, starfish and sea cucumbers)

Echinoderms are animals with rounded bodies and some species exhibit hollow spicules of calcium carbonate on the surface, capable of causing severe traumatic accidents (Figure 9). Some species of starfish (such as the species "crown-of-thorns") and sea urchins are venomous. In sea urchins, the venom has hypotensive and hemolytic neurotoxic and cardiotoxic effects, due to toxins present in the pedicellaria, small tentacles that are located among the spikes.<sup>2,30</sup> Sea cucumbers (*Holothuria*) produce holothurin, a toxin that irritates the skin and mucous membranes.

In traumatic injuries caused by sea urchins (almost all accidents in Brazil), spines penetrate human skin and break, appearing as small black spots on the skin (Figure 9). It is possible to extract fragments of up to 3.0 cm of the site, but most are small pieces and sometimes only pigments remain at the point of entry of the spicule. The pain is moderate and only occurs by compression.<sup>30,31,32</sup> The plantar regions are commonly affected and spines may serve as a gateway for secondary infections, including tetanus. Most spines are eliminated, but there may nodules with erythematous and verrucous surfaces (foreign body granuloma) that are difficult to resolve.<sup>30,31,32</sup> Accidents caused by venomous echinoderms cause skin inflammation, manifested by erythema, edema, papules, vesicles and occasional necrosis.<sup>2-5</sup>



**FIGURE 9:** Top-left: black sea urchins (*Echinometra lucunter*). Below: spines in the feet of bathers. Photos: Vidal Haddad Junior. Right: hyperkeratotic nodules on the hands of a diver who suffered several injuries caused by black sea urchins (foreign body granuloma). Photo: André Rossetto

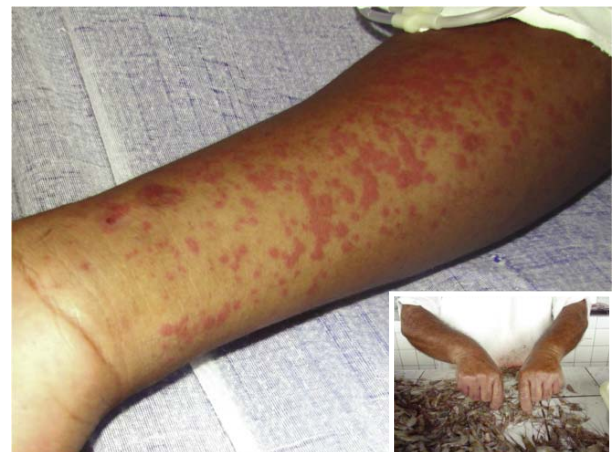The species *Echinometra lucunter* is the most common in Brazil and it causes traumatic accidents, since there are no signs of envenomation after contact. Bathers are the major victims of this accident, but it is common to see freedivers with spicules or late-developing nodules, mainly on the hands, in contrast to swimmers, who suffer foot injuries when walking in shallow waters and small pools between rocks, generally at transition points on beaches. Accidents involving black sea urchins are the most common among all caused by marine animals (about 50%).<sup>1-5, 30, 31, 32</sup>

The removal of spines of sea urchins should be done under local anesthesia. Thus, a superficial scarification with a large-caliber hypodermic needle is performed, and this same needle is used to remove spines. Fragments are brittle and can be difficult to remove, but it is necessary to extract large fragments, due to the risk of granuloma development (Figure 9). Many fragments are expelled by a local inflammatory reaction. All the venomous animals of this phylum have thermolabile venom, making it appropriate to immerse the affected area in hot water, around 50°C, for 30 to 90 minutes, especially if there is spontaneous pain.<sup>10</sup>

#### **PHYLUM CRUSTACEA (Blue crabs, crabs, shrimps, prawns, barnacles, lobsters and mantis shrimp)**

Crustaceans do not produce venom, but can cause severe allergic reactions and injuries from substances in their body.

Traumatic injuries are more common, especially lacerations caused by the claws. Allergic manifestations are not uncommon: contact dermatitis may emerge, as well as urticaria and anaphylactic reactions (Figure 10). The latter seem to be cross reactions associated with tropomyosins present in all crustaceans and astaxanthin, a pigment that gives the reddish color of shrimps, crabs, lobsters (crustaceans), salmon and flamingos.<sup>2,5</sup> Contact dermatitis is manifested by an acute eczematous process. Complications of some allergic diseases can be serious.<sup>2,5</sup> The use of antihistamines and topical corticosteroids controls contact dermatitis.



**FIGURE 10:** Urticaria caused by ingestion of shrimps. Eczematous process in a fisherman who cleans shrimps. Photos: Vidal Haddad Junior.

Traumatic injuries caused by crustaceans are not serious, but it is interesting to note that irritant dermatitis can be seen on the hands of those who clean shrimps and prawns, and it can be irritative and/or traumatic (Figure 10). Fishermen in the Southeast and Northern regions of Brazil fear the mantis shrimp, a large and aggressive crustacean (up to 30cm), whose sharp claws can cause serious injury to hands, and which has been named *thumbsplit* in parts of the Caribbean. Treatment for injuries caused by crustaceans is carried out through intense washing of the wound, a tetanus vaccination and topical or systemic antibiotics if infection occurs.

**PHYLUM INSECTA (Giant water bugs)**

Venomous aquatic insects are rare, but one can point to the Belostomatidae, carnivorous hemiptera, popularly known as giant water bugs (Figure 11). These animals live in freshwater environments and they hunt other arthropods, and even small fish and frogs. There are large species, such as *Lethocerus delpontei*, which can reach 10cm in length. Accidents caused by these animals have been reported, affecting particularly people who have contact with water streams. The bite inflicted by a proboscis provokes severe pain and in some cases, reversible paralysis of limbs can occur. Some studies associate the sting of these insects to Buruli ulcers, caused by *Mycobacterium ulcerans*.<sup>2,33</sup>



FIGURE 11: Insects of the Belostomatidae family (giant water bugs) are venomous and can cause painful accidents in humans. Photo: Vidal Haddad Junior

**CONCLUSIONS**

Injuries caused by aquatic animals are common and have occurred more frequently over the last decades, due to increasing contact between humans and aquatic environments. The animals’ main characteristics and the clinical manifestations of trauma and envenomation, are summarized in the table 1, outlining first aid measures for hospitals and healthcare teams operating in areas where the problem exists. □

**TABLE 1:** Algorithm for identification and treatment of injuries caused by aquatic animals (adapted from Haddad V Jr - Potentially Dangerous Aquatic Animals of Brazil: a medical and biologic guide. Editora Roca, São Paulo, 2008).

Puncture wounds			Skin eruptions		Lacerated wounds	
Presence of stinger	Presence of local spines	Spines rarely present	Urticariiform plaques, edema, erythema, vesicles, necrosis	Eczema	Cyanotic or pale edges Fragments of stingers	Lacerations with pain proportional to the wound
**	*	**	**	*	**	*
Marine and freshwater catfish, mandis, stingrays	Sea urchins	Scorpionfish Toadfish	Jellyfish, Portuguese men-of-war, corals, anemonas	Marine and freshwater sponges, marine worms, sea cucumbers	Marine and freshwater stingrays and catfish, (occasional puncture wounds)	Sharks, barracudas, moray eels, piranhas and other traumatogenic fish
1=	1	1	2	2	1	3

\*\* Intense pain

\* Moderate pain

- 1 - Immersion in hot water for 30-90 minutes (about 50 °C)  
Extraction of spicules and fragments of stings or glandular epithelium and infiltration of local anesthetic  
Persistence of symptoms in later phases: radiological exam. Tetanus prophylaxy.
- 2 - Wash the place or make compress with iced marine water (DON'T USE FRESHWATER!)  
Apply vinegar (acetic acid): wash the place or make compress  
Analgesy (dipirona 1 amp IM).
- 3 - Intensive washing with research of fragments of bones and stings.  
Antibioticoterapy and tetanus prevention.  
# In all lacerated wounds, it is necessary the use of antibiotics:  
Cephalexin 2,0g/ day or Amoxicillin and Clavulanate potassium 1,5g/ dia for 10 days.



## REFERENCES

1. Haddad Jr V. Avaliação Epidemiológica, Clínica e Terapêutica de Acidentes Provocados por Animais Peçonhentos Marinhos na Região Sudeste do Brasil (thesis). São Paulo (SP): Escola Paulista de Medicina, 1999. 144 p.
2. Haddad Jr V. Atlas de animais aquáticos perigosos do Brasil: guia médico de diagnóstico e tratamento de acidentes. São Paulo: Editora Roca; 2000.145 p
3. Haddad Jr V. Animais aquáticos de importância médica. Rev Soc Bras Med Trop. 2003;36:591-7.
4. Haddad Jr V. Animais aquáticos potencialmente perigosos do Brasil: guia médico e biológico. São Paulo: Editora Roca; 2008.288p.
5. Haddad Jr V, Lupi O, Lonza JP, Tying SK. Tropical dermatology: Marine and Aquatic dermatology. J Am Acad Dermatol. 2009;61:733-50.
6. Burke WA. Coastal and marine dermatology. In: Forum in the Meeting of the American Academy of Dermatology. San Francisco, 1997.
7. Volkmer-Ribeiro C, Lenzi HL, Oréfice F, Pelajo-Machado M, de Alencar LM, Fonseca CF, et al. Freshwater sponge spicules: a new agent of ocular pathology. Mem Inst Oswaldo Cruz. 2006;101:899-903.
8. Halstead BW, Auerbach PS, Campbell DA. A Colour Atlas of Dangerous Marine Animals. London: Wolfe Medical Publications; 1990.
9. Fisher AA. Atlas of aquatic dermatology. New York: Grune and Straton; 1978.
10. Meier J, White J. Clinical toxicology of animal venoms and poisons. Florida: CRS Press; 1995.
11. Cazorla-Perfetti DJ, Loyo J, Lugo L, Acosta ME, Morales P, Haddad V Jr, et al. Epidemiology of the cnidarian *Physalia physalis* stings attended at a health care center in beaches of Adicora, Venezuela. Travel Med Infect Dis. 2012;10:263-6.
12. Haddad Jr V, Silveira FL, Cardoso JLC, Morandini AC. A report of 49 cases of cnidarian envenoming from southeastern Brazilian coastal waters. Toxicon. 2002;40:1445-50.
13. Haddad Jr V, Silva G, Rodrigues TC, Souza V. Injuries with high percentage of systemic findings caused by the cubomedusa *Chiropsalmus quadrumanus* (Cnidaria) in Southeast region of Brazil: report of ten cases. Rev Soc Bras Med Trop. 2003;36:84-5.
14. Risk JY, Haddad Jr V, Cardoso JLC. Envenoming caused by a Portuguese man-of-war (*Physalia physalis*) manifesting as purpuric papules. An Bras Dermatol. 2012;87: 644-5.
15. Haddad Jr V, Migotto AE, Silveira FL. Skin lesions in envenoming by cnidarians (Portuguese man-of-war and jellyfish): etiology and severity of the accidents on the Brazilian coast. Rev Inst Med Trop São Paulo. 2010;52:47-50.
16. Guess HA, Saviteer PL, Richard MC. Hemolysis and acute renal failure following a Portuguese man-of-war sting. Pediatrics. 1982;70: 979-81.
17. Burnett JW, Calton GJ, Burnett HW. Jellyfish envenomation syndromes. J. Am Acad. Dermatol. 1986;14:100-6.
18. Resgalla Jr C, Rossetto AL, Haddad Jr V. Report of an outbreak of stings caused by *Olindias sambaquiensis* MULLER, 1861 (Cnidaria:Hydrozoa) in Southern Brazil. Braz J Oceanogr. 2011;59:391-6.
19. Haddad Jr, V, Cardoso JLC, Silveira FLS. Seabather's eruption: report of five cases in the Southeast Region of Brazil. Rev Inst Med trop S Paulo. 2001;43:171-2.
20. Rossetto AL, Dellatorre G, Silveira FL, Haddad Júnior V. Seabather's eruption: a clinical and epidemiological study of 38 cases in Santa Catarina State, Brazil. Rev Inst Med trop S Paulo. 2009;51:169-75.
21. Rossetto AL, Mora Jde M, Correa PR, Resgalla C Jr, Proença LA, da Silveira FL, et al. Prurido do traje de banho: relato de seis casos no Sul do Brasil. Rev Soc Bras Med Trop. 2007;40:78-81.
22. Garcia PJ, Schein RMH, Burnett JW. Fulminant hepatic failure from a sea anemone sting. Ann. Intern. Med. 1994;120:665-6.
23. Marques AC, Haddad Jr, V, Migotto AE. Envenomation by a benthic Hydrozoa (Cnidaria): the case of *Nemalecium lighti* (Haleciidae). Toxicon. 2002;40:213-5.
24. Burnett JW, Kumar S, Malecki JM, Szmant AM. The antibody response in seabather's eruption. Toxicon. 1995;33:95-104.
25. Loten C, Stokes B, Warsley D, Seymour JE, Jiang S, Isbistier GK. A randomized controlled trial of hot water (45oC) immersion versus ice packs for pain relief in bluebottle stings. Med J Aust. 2006;4:329-33.
26. Fenner P. Awareness, Prevention and Treatment of world-wide marine stings and bites. Conference in International Life Saving Federation Medical/Rescue Proceedings. Australia, 1997.
27. Haddad Jr V, de Paula Neto JB, Cobo VJ. Venomous mollusks: the risks of human accidents by *Conus* snails (Gastropoda, Conidae) in Brazil. Rev Soc Bras Med Trop.2000;39:498-500.
28. Haddad Jr V, Coltro M, Simone LRL. Report of a human accident caused by *Conus regius* (Gastropoda, Conidae). Rev Soc Bras Med Trop. 2009;42:446-8.
29. Haddad Jr V, Moura R. Acute neuromuscular manifestations in a patient associating with ingesting *octopus* (*Octopus* sp). Rev Inst Med trop São Paulo. 2007;49:59-61.
30. Haddad Jr V; Novaes SPMS, Miot HA, Zuccon A. Accidents caused by sea urchins - the efficacy of precocious removal of the spines in the prevention of complications. An Bras Dermatol. 2002;77:123-8.
31. Rossetto AL, Mota JM, Haddad Jr V. Sea urchin granuloma. Rev Inst Med trop São Paulo. 2006;48:303-6.
32. Haddad Jr V. Observation of initial clinical manifestations and repercussions from the treatment of 314 human injuries caused by black sea urchins (*Echinometra lucunter*) on the southeastern Brazilian coast. Rev Soc Bras Med Trop. 2012;45:390-2.
33. Haddad Jr V, Schwartz ENF, Schwartz CA, Carvalho LN. Bites Caused by Giant Water Bugs Belonging to Belostomatidae Family (Hemiptera, Heteroptera) in Humans: A Report of Seven Cases. Wilderness Environ Med. 2010;21:130-3.

---

MAILING ADDRESS:  
 Vidal Haddad Junior  
 Caixa Postal 557  
 Rubião Jr  
 18618-970 - Botucatu – SP  
 Brazil  
 E-mail: haddadjr@fmb.unesp.br

How to cite this article: Haddad V Jr. Environmental dermatology: skin manifestations of injuries caused by invertebrate aquatic animals. An Bras Dermatol. 2013; 88(4):496-506.

## QUESTIONS

1. **Poisons and venoms are different things. What is correct?**
  - a) poisons are injected through apparatus and venoms by passive ways
  - b) venoms are found in puffer fish and toads
  - c) a snake is a poisonous animal
  - d) venoms are injected by apparatus and poisons are acquired by organisms through ingestion and contact
2. **Regarding marine animals, it is observed that:**
  - a) about 10% of the occurrences in Emergency Rooms in the coast are caused by them
  - b) more than half of the accidents in Brazil are caused by jellyfish and Portuguese man-of-war
  - c) sea urchins are the main cause of injuries by marine animals in bathers in Brazil
  - d) venomous fish do not usually cause accidents
3. **Dermatitis that occurs after contact with marine sponges has a pattern:**
  - a) Eczematous
  - b) Nodular
  - c) Bullous
  - d) Verrucous
4. **Freshwater and marine sponges cause injuries:**
  - a) disseminated
  - b) localized
  - c) freshwater sponges cause disseminated lesions and marine sponges cause localized injuries
  - d) marine sponges cause disseminated lesions and freshwater sponges cause localized injuries
5. **Cnidarians are poorly developed animals in the zoological scale, but they have an advanced system of envenomation. In Brazil, they are responsible for what percentage of accidents in bathers?**
  - a) 50%
  - b) 75%
  - c) 45%
  - d) 25%
6. **The Phylum Cnidaria congregates venomous marine organisms that present cnidocytes. The inner organelle that injects the venom is called:**
  - a) cnidoblast
  - b) tentacle
  - c) float
  - d) nematocysts
7. **Accidents caused by jellyfish and Portuguese man-of-war are popularly called "burns". Mark the correct answer:**
  - a) the injuries are not so painful
  - b) there is no heat in the process, only the action of venom
  - c) there is a chemical reaction that generates heat and burns the skin
  - d) treatment for victims of burns shall be performed
8. **Long erythematous and edematous crisscrossed linear plaques, with the presence of severe pain and systemic phenomena after contact of a bather with a cnidarian should suggest accident caused by:**
  - a) *Physalia physalis* (Portuguese man-of-war) and *Olindias sambaquiensis*
  - b) *Olindias sambaquiensis* and *Linuche unguiculata*
  - c) *Physalia physalis* (Portuguese man-of-war) and *Linuche unguiculata*
  - d) *Physalia physalis* (Portuguese man-of-war) and cubomedusae
9. **Rounded plaques with occasional presence of small diameter linear plaques, accompanied by severe pain, but without systemic phenomena suggest contact with which cnidarian common in the Southeast and South of Brazil?**
  - a) *Physalia physalis* (Portuguese man-of-war)
  - b) *Olindias sambaquiensis*
  - c) *Chiropsalmus quadrumanus*
  - d) *Linuche unguiculata*
10. **A child seeks medical help after baths on a beach during the weekend with a history of pruritus in the gluteal region. The mother reports that the site was "red and swollen" a few hours after the child get out of the water. The examination shows erythematous papules in the gluteal region, some topped with crusts, probably associated with the intense itching. The agent of dermatitis is likely:**
  - a) *Physalia physalis* (Portuguese man-of-war)
  - b) *Linuche unguiculata*
  - c) *Tamoya haplonema*
  - d) *Chiropsalmus quadrumanus*
11. **There is some controversy regarding the initial treatment of injuries caused by cnidarians. One of the measures below is contraindicated. What is it?**
  - a) applying compresses of cold seawater
  - b) compresses of 5% acetic acid
  - c) use of antihistamines (only in presence of allergic phenomena)
  - d) immediately wash and use freshwater compresses
12. **Urinating on injuries caused by marine animals is a measure commonly adopted on Brazilian and other beaches around the world. This occurs on lesions caused by jellyfish, sea urchins, fish like the stingray and others. Bathing with local Coca-Cola® is also a widespread measure. Regarding the effectiveness of these actions, which is correct?**
  - a) there is no scientific support for the use of these measures in pain control
  - b) urine has substances that are inflammation suppressants and really control the process
  - c) The soft drink controls the pain by means of the sugar in the formula
  - d) only freshwater in baths and compresses can suppress the pain
13. **Leeches (especially the *Hirudo medicinalis* species) have been used since Classical Antiquity as a medical resource to collect blood samples from patients. In Nature, these animals are common in aquatic environments and may:**
  - a) cause deaths due to uncontrollable bleeding by action of hirudin
  - b) remove quantities of blood that do not compromise plasma volume or blood clotting
  - c) cause severe infections by *Mycobacterium marinum*
  - d) cause severe anemia in patients constantly parasitized
14. **The "brushworms" can cause traumatic injuries by penetration of body bristles and bites. What kind of injury is observed?**
  - a) infiltrated nodules
  - b) fistulas and gums
  - c) edema, papules, pruritus and pain
  - d) plaques with verrucous surface
15. **The common octopuses are venomous animals that can inject cephalotoxin, a neurotoxin. Other injuries caused by octopuses are:**
  - a) extensive lacerations with copious bleeding
  - b) infiltrated plaques at points of contact with the "beak"

- c) serious secondary infections by contact with the suction cups
- d) eczema after contact with the tentacles

16. Accidents by black sea urchins (*Echinometra lucunter*) correspond to about 50% of injuries caused by marine animals in Brazil. What are the main target populations?

- a) fishermen and bathers
- b) divers and fishermen
- c) bathers and divers
- d) surfers and fishermen

17. At the entry point of the spines of sea urchins we can observe points that correspond to spikes inserted deeply into the skin, usually in the plantar regions. What is the treatment for a patient that seeks immediate help?

- a) extraction of spicules as soon as possible with broad-caliber needle
- b) expectant management, for all spicules are expelled by the inflammatory reaction
- c) application of sodium bicarbonate, which dissolves the spicules
- d) referral to orthopedic surgeon to perform the procedure under general anesthesia

18. The venomous sea urchins sea are very rare in Brazil, since the predominant species (*Echinometra lucunter*, black sea urchin) cause initially only traumatic injuries. What are the complications of this kind of accident?

- a) local foreign body granulomas
- b) infections by *Sporothrix schenckii*
- c) atypical mycobacteriosis
- d) pyogenic granuloma

19. Crustaceans are animals frequently consumed by the human population. Which of these substances in crustaceans is associated with allergic processes such as urticaria and anaphylactic shock?

- a) hemoglobin
- b) saurine
- c) astaxanthin
- d) carotene

20. Giant water bugs are large venomous insects of the Belastomatidae family that can sting humans. These animals also can cause:

- a) painful accidents and paralysis
- b) skin necrosis
- c) erysipelas after bites
- d) granuloma annulare

## Papers

Information for all members: The EMC-D questionnaire is now available at the homepage of the Brazilian Annals of Dermatology: [www.anaisdedermatologia.org.br](http://www.anaisdedermatologia.org.br). The deadline for completing the questionnaire is 30 days from the date of online publication.