

# Trial with Platelet-Rich Fibrin and Bio-Oss used as grafting materials in the treatment of the severe maxillar bone atrophy: clinical and radiological evaluations

F. INCHINGOLO<sup>\*,\*</sup>, M. TATULLO<sup>#</sup>, M. MARRELLI<sup>\*,\*</sup>, A.M. INCHINGOLO<sup>\*,^</sup>, S. SCACCO<sup>#</sup>, A.D. INCHINGOLO<sup>\*,\*</sup>, G. DIPALMA<sup>\*,\*</sup>, D. VERMESAN<sup>°</sup>, A. ABBINANTE, R. CAGIANO

School in "Dental Hygiene", Faculty of Medicine, University "Aldo Moro", Bari (Italy)

<sup>\*</sup>Department of Dental Sciences and Surgery, Faculty of Medicine, University of Bari (Italy)

<sup>^</sup>Dental School, Faculty of Medicine, University of Milano, Milano (Italy)

<sup>#</sup>Department of Medical Biochemistry and Medical Biology, Faculty of Medicine, University of Bari (Italy)

<sup>°</sup>University of Medicine and Pharmacy "Victor Babes", Timisoara (Romania)

<sup>\*</sup>Calabro-Dental s.r.l. Maxillo-Facial Surgery, Crotone (Italy)

**Abstract. – Objectives:** The aim of the present study is to assess the implant osteo-integration, as well as the course of bone regeneration and healing processes, thanks to the sinus lift procedure and by using PRF<sup>®</sup> as a filling material, in association with the Bio-Oss<sup>®</sup>.

**Materials and Methods:** 23 patients, requiring maxillary sinus lift in order to place implants into posterior maxillary region, were involved in this study. Selected cases, in which the height of the residual bone was superior to 5 mm, were adopted for surgical procedure of "one-stage sinus lift" (implant insertion concurrently occurred with sinus lift resulting 6-9 months the healing and integration time). Before inserting the implant, a small quantity of filling material was placed in the cavity. For this purpose the bone fragment, stored in saline solution, was employed mixed with Bio-Oss<sup>®</sup> and PRF<sup>®</sup>, after being ground.

**Results:** All patients reported no pain to percussion, no sign of tissue suffering in the soft peri-implant tissues, the presence of an optimal primary stability of the inserted implants and a significant increase in the peri-implant bone density.

**Conclusions:** In all cases included in this protocol, the Authors observed a successful implant-prosthetic rehabilitation, according with Albrektsson criteria.

*Key Words:*

PRF, Bone grafting, Sinus-Lift.

## Introduction

During the last decades, implant rehabilitation received increasing attention in odontostomatology, offering a real and practical alternative to conventional prostheses. The enthusiastic intention to treat edentulous areas with endosseous implants has often clashed with the assumption that the loss of teeth is reflected in a progressive bone reabsorption. In particular, the lateral and posterior parts of the edentulous upper jaw often present some anatomical limitations, resulting in a continuous challenge for the dental surgeon. In such areas, in fact, the primary stability of implants, as well as the elusion of intra- and post-operative complications, may be invalidated by an inadequate three-dimensional bone support, that is to say an insufficient height and/or thickness of the alveolar crest. This bone deficiency may result from an excessive pneumatization of the maxillary sinus (large sinus cavities), from an important atrophy of the alveolar crest referable to dental extractions and/or periodontal diseases, or from both of these causes. Besides, the reabsorption process, in edentulous posterior maxillary regions, could determine insufficient vertical dimensions for the implant positioning, often requiring additional surgical procedural steps. These involve the use of:

- Reabsorbable and not-reabsorbable membranes;
- Bone substitutes often combined with autologous bone;
- Surgical expansion through Le Fort I Osteotomy with interposition of bone grafts;
- Sinus lift procedures with the contextual filling of the cavity by means of several graft materials<sup>1-3</sup>.

*Le Fort I Osteotomy*, with interpositional bone grafts, represents the right choice in case of a serious horizontal defect of the maxillary bone and, in case of large intermaxillary distance, this technique cannot be applied in patients presenting an interarch distance described as inadequate. In these cases, the surgeon should opt for an inlay graft or for an increase in the bone volume at the expense of the maxillary sinus volume, subject to lifting of the *Schneider* membrane<sup>4-6</sup>.

The modern and sophisticated techniques of GBR (*Guided Bone Regeneration*) are based on four principles:

- Inhibition of undesired cell migration;
- Space creation and maintenance;
- Protection of the blood clot;
- Stability of the wound.

For this purpose, the choice of the “*filling*” material represents an essential aspect for a complete and real achievement of the above-mentioned objectives.

In the last years, various techniques have been proposed and several types of materials have been assessed; these were critically reviewed by means of clinical studies and histological investigations. The continuous pursuit of the ideal filling material has often focused the attention on the adoption and marketing of several bone substitutes, combined to a greater or lesser degree with autologous bone of intra- and extra-oral origin<sup>7,8</sup>.

In general, an ideal grafting material should have the following 4 properties:

1. *Osteointegration*, that is the capacity to functionally connect the biocompatible material to the bone surface, without fibrous tissue formation at the interface;
2. *Osteoconduction*, that is the ability to function as a physical, three-dimensional scaffold in order to facilitate bone formation;
3. *Osteoinduction*, that is the ability to provide a biologic response, in order to induce the dif-

ferentiation of undifferentiated, pluripotent cells, in a mature osteoblastic phenotype.

4. *Osteogenesis*, that is the capacity of osteoblasts progenitor cells to directly induce the formation of mineralized bone tissue, in association with osteoblasts of the receiving site. This property is expressed only in case of autogenous grafts, which are the only ones able to provide the necessary cellular elements: these are contained in the bone marrow to a greater extent, and then in the intracortical region and in the periosteum.

## Bone Grafting Materials

The bone grafting materials are commonly classified as follows: *autografts*, *allografts* and *alloplastic grafts*.

### *Autografts*

- Intraoral donor sites (greenstick grafts and bone fragments taken from the tuber, the chin area and the edentulous saddle area);
- Extraoral donor sites (bone fragments taken from the tibia, the rib and the iliac crest).

The suitable grafting material was the autologous bone from an intraoral source, due to the same embryogenetic derivation and for the presence of the bone morphogenetic protein (BMP), which promotes osteoinduction. The autologous bone represents an ideal material for sinus lift, because it is the only material presenting osteogenic properties, in addition to the osteoinductive and osteoconductive ones. From the histological point of view, the autologous bone looks similar to that of the host bone, being surrounded by newly formed bone and with its reabsorption process very slow. Histomorphometric analyses, performed in a few studies, reveal a percentage of newly formed bone around 40%.

Some limit in using the autologous bone procedure is the operating time together with the necessity to operate on two areas of the body. Therefore, in clinical practice, the allogenic or alloplastic materials result more used<sup>9-10</sup>.

### *Allografts*

- Homologous grafts, coming from another individual of the same species ([www.bonebank.com](http://www.bonebank.com));
- Heterologous grafts (or xenografts), coming from another individual of a different species,

which in general is bovine, demineralized, sterilized or frozen. Due to the absence of living osteoblasts, the allogenic bone cannot cause osteogenesis, but only osteoinduction and osteoconduction. One of the main features to take into account, while choosing the material, is the time span at which the biomaterial is reabsorbed. Obviously, slow reabsorption is more desirable, compared to a reabsorption process which is too fast, because the latter would not lead to new bone formation into the newly formed matrix. Rapid phenomena, in fact, would inhibit revascularization and continuous bone remodeling, necessary to assure osteoconduction and osteoinduction. Brunsvold and Mellonig defined the range between 250 and 270  $\mu\text{m}$  as the dimensional range which the microarchitecture of a biomaterial should always comply with, in order to ensure an optimum reabsorption time and, therefore, promote osteoinduction and osteoconduction<sup>11</sup>. Smaller or larger sizes are not desirable, as reabsorption would be too fast and too slow, respectively.

**Bio-Oss®.** Deproteinized bovine bone (Bio-Oss) is frequently used in the clinical practice of sinus lift, being it able to induce a physiological bone remodeling, with disposition and significant bone gain, thanks to its chemical-physical properties which are very similar to those of the human bone (the percentage of newly formed bone is around 39%). Apart from its good osteoinductive and osteoconductive properties and the poor reabsorbability, the bovine bone mineral does not run intolerance or infection risks. The biocompatibility of the material is due to its preparation, aiming to eliminate protein and lipid components from the original material, making it inorganic before being sterilized by heat and irradiation<sup>12-14</sup>.

**Demineralized Bone (DFDBA, Demineralized Freeze-Dried Bone Allograft).** DFDBA is obtained by treating a human bone sample from donor sites (24 hours before death) with a process of demineralization with hydrochloric acid, water washing, drying, sterilization, irradiation and freezing. In this way, the organic matrix remains intact and proteins like BMP are exposed, responsible for the osteoinductive properties of DFDBA. The good quality and quantity of bone regeneration, achieved by means of demineralized freeze-dried bone allografts, has been confirmed by several recent studies<sup>15-17</sup>.

### **Alloplastic Grafts**

*Alloplastic grafts* made up of synthetic materials<sup>18</sup>.

**Hydroxyapatite (HA).** Hydroxyapatite ( $\text{Ca}_{10}(\text{PO}_4)(\text{OH})_2$ ) is a calcium phosphate ceramic, which in nature represents 60-70% of bone and 98% of enamel. HA is a bioinert material which binds the bone, without provoking inflammatory and/or toxic reactions and shows osteoconductive properties, as it serves as a matrix for the migration of osteogenic cells within it<sup>16</sup>. It is commercially available in several forms, presenting different physical-chemical properties, such as:

- Forms of product distribution (blocks or particles);
- Porosity (dense, microporous, macroporous);
- Crystallinity (crystalline, amorphous).

For implant insertion, it is recommended to use the microporous form, characterized by an ideal reabsorption time, in order to guarantee osteoconduction and, therefore, implant osteointegration.

**Calcium Sulphate.** Calcium sulphate, in its *hemihydrate* form, has been extensively used, both in the medical treatment by implants and in periodontics, for bone and periodontal regeneration.

Periodontal regeneration is confirmed by the results of experiments in both animal and human models. With regard to bone regeneration, a study on animal models confirmed the possible use of calcium sulphate as a barrier to employ according to the principles of Guided Bone Regeneration (GBR). Calcium Sulphate (CaS), also known as *plaster of Paris*, is made up of sulphuric acid and calcium; there are three different hydration forms: *anhydrate*, *hemihydrate*, and *dihydrate*<sup>17</sup>. In case of sinus lift, its frequently used form is called *Surgiplaster Sinus*, that is calcium sulfate with a mean granulometry, specifically used for maxillary sinus lift because, thanks to its particular granulometry, it can be easily placed and also modulates reabsorption according to the regenerative requirements. It can be used alone or mixed with bank or autologous bone as a bonding agent, otherwise in combination with membranes to maintain the biological space.

**Physiograft.** It is a synthetic material made up of co-polymer of l-d-poly-lactic acid and polyglycolic acid. It is characterized by a density which is not too high, because its main mechanical function is that of space maintainer and, due to its degree of density, the reabsorption time is more uniform (between 3-4 months and 6-8 months), with relation to the implant dimension, the individual reactivity and the degree of blood stream in the implant site. This material mainly functions as a reabsorbable space former, being permeated by blood and progressively substituted by osteoprogenitor cells, up to the formation of bone tissue<sup>13</sup>.

**Pep-Gen P15.** Pep-Gen P-15 is a new material for bone regeneration, made up of a combination of an inorganic bovine bone (ABM) and a synthetic peptide (P-15). This combination is able to reproduce the collagen property to promote bond, migration and cell differentiation<sup>10</sup>. Once they have been placed, the grafting materials are completely replaced with bone substitutes, by means of a gradual process starting with the organization, in the blood clot, of a granulation tissue which incorporates the particles of the grafted material. Afterwards, there is a differentiation of the mesenchymal cells in osteoblasts, with the formation of new bone tissue. Many types of materials have been used for maxillary sinus lift: autologous bone, demineralized and freeze-dried bone, hydroxyapatite and different combinations of these materials, often with satisfactory results in terms of biocompatibility, induction of bone formation and, of course, implant stability.

**Platelet-Rich Fibrin®.** As a supplement to procedures of tissue regeneration, a platelet concentrate called PRF (Platelet Rich Fibrin) was tested for the first time in France by Choukroun et al. and introduced with the European Directive n. 2004/23/CE of March 31<sup>th</sup>, 2004. PRF (Platelet Rich Fibrin), which belongs to a new generation of platelet concentrates, is obtained without the addition of anticoagulants such as heparin, EDTA, bovine thrombin, etc. During the production of PRF, apart from platelets, other cellular elements are activated, such as leukocytes, which release cytokines after the artificial hemostatic and inflammatory phenomenon induced by centrifugation. Inside there are, therefore, three pro-inflammatory cytokines (IL-1 $\beta$ , IL-6 e TNF $\alpha$ ), an anti-inflammatory cytokine (IL-4) and an angiogenesis promoter (VEGF). Hence, PRF is able to regulate inflammation and

to stimulate the immune process of chemotaxis. PRF is an autologous graft material which eliminates any risk of disease transmission; besides, its gelatinous consistency enhances the clot and graft stability. However, it has an important defect: as it is a biomaterial directly obtained from the patient's blood, its quantity results modest. PRF has the special feature to undergo polymerization during centrifugation, naturally and slowly. Active thrombin and fibrinogen concentrations are almost physiological, because the material does not require any addition of bovine thrombin. The fibrin then assumes a three-dimensional conformation. The combination of fibrin monomers leads to the formation of a trimolecular structure, thus forming a soft and permeable mesh network and allowing rapid colonization of the scar cells. This natural material actually seems to accelerate the physiological wound healing; besides, in association with bone grafts, it seems to accelerate new bone formation<sup>18-20</sup>. In the last years, PRF concentrates have been widely used as a supplement to tissue regeneration procedures<sup>21-27</sup>. Most of the Authors who used PRF in their dental practice affirm that there was no risk of infection, disease transmission or side effects. However, some Authors supposed that the superexpression of growth factors and their receptors could depend from the neoplastic transformation. In this regard, it is absolutely necessary a careful revision of literature on the possible effects of the therapeutic use of GFs (including PRF), with relation to carcinogenesis, to their influence on tissues with epithelial dysplasia or oral carcinoma and to their relation with growth and tumor infiltration. Besides, we need to underline that little is known about the ideal concentration of each GF or the optimal dosage for each actual therapeutic situation.

## Materials and Methods

The aim of the present study is to assess the implant osteointegration, as well as the course of bone regeneration and healing process, thanks to the sinus lift procedure and by using PRF as a filling material, in association with Bio-Oss.

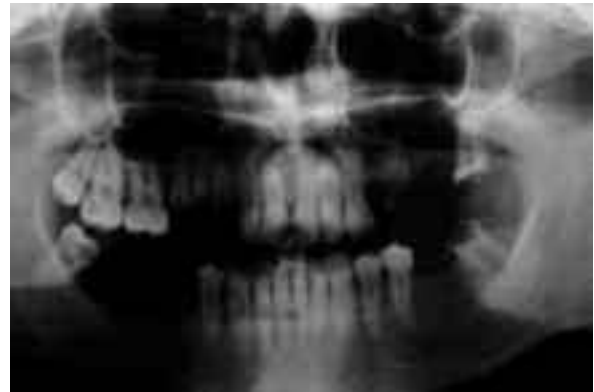23 patients were involved in this study (13 women, 10 men aged between 31 and 59 years), requiring maxillary sinus lift to place implants in

the posterior maxillary region. 13 patients were completely edentulous and 10 were partially edentulous at the level of the upper jaw. Before treatment, patients were adequately informed about the procedure, first verbally and then with a written form for the informed consent. Exclusion criteria were:

- Ongoing steroid therapy;
- Non-compensated diabetes mellitus;
- Recent cardiovascular diseases;
- Inflammation of the maxillary sinus;
- Previous radiant therapy for neoplastic pathologies;
- Unnecessary habits (smoking more than 15 cigarettes a day);
- A bone quantity inferior to 5 mm near the maxillary sinus, as it contraindicates the simultaneous placement of dental implants.

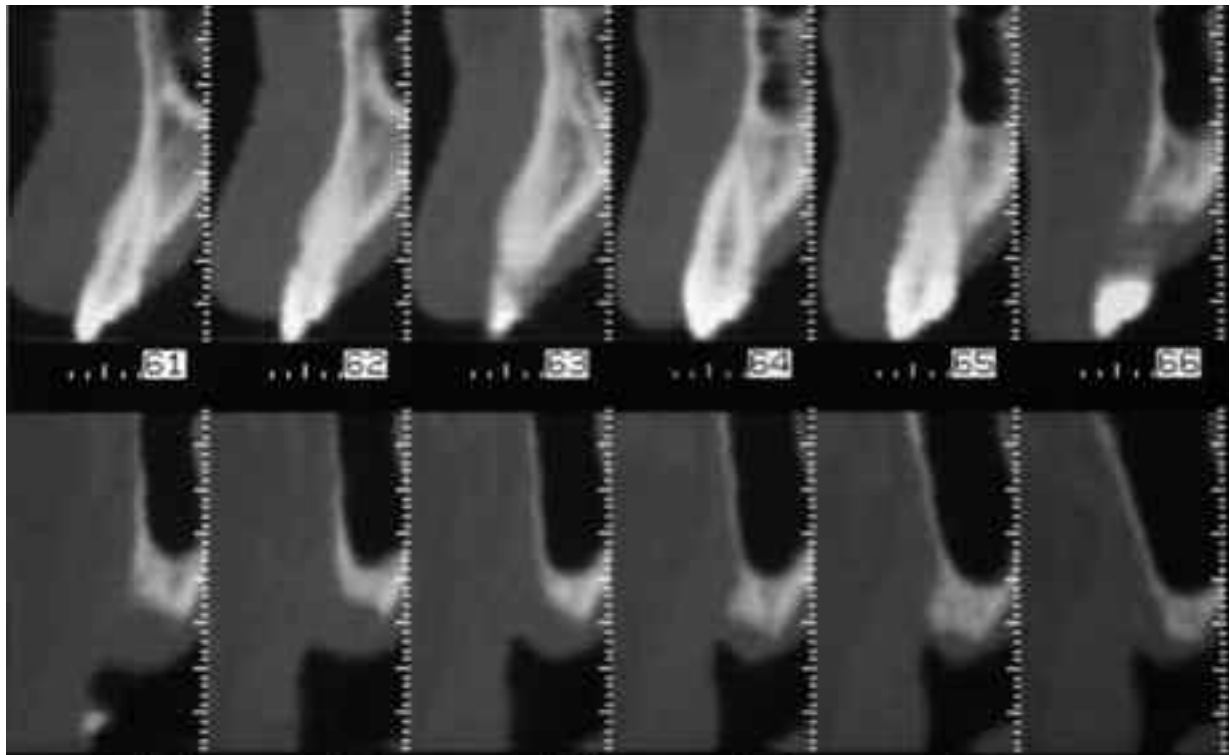
#### **Surgery Preparation**

All the patients underwent a careful hematologic and cardiologic evaluation in specialist wards in order to optimize and customize the prophylaxis and the preoperative pharmacologic therapy. The bone loss was assessed by means of



**Figure 1.** X-Ray showing the pre-operative condition of a patient enrolled in our study.

radiological investigations and Computerized Tomography (Figures 1 and 2). The choice of implants was case-specific, according to the rehabilitative necessity. Before each surgical treatment, scrupulous oral hygiene was practiced by supragingival and subgingival *scaling*. Moreover, 1 h before surgery, 2 cps of (Amoxicillin 875 mg + clavulanic acid 125 mg) per os were administered, when necessary.



**Figure 2.** Particular of Maxillary TC in order to evaluate the residual bone.

### **PRF preparation**

Protocol steps are as follows: *Take a sample of patient's venous blood* in a surgical or dental laboratory, before surgery.

**Perform its centrifugation:** 10 ml tubes (free from anticoagulant) are suddenly centrifuged at 3000 rpm along 10 minutes. In a few minutes, in the sample there is an activation of a great amount of platelets after coagulation reactions born with tube contact. After centrifugation, acellular plasma supernatant, or PPP (Platelet-Poor-Plasma), will be found at the top of the tube, PRF in the middle and blood cells at the bottom.

**This last part (PRF) will be used in two ways:** part will be included in a sterile cup (Figure 3) and mixed with Bio-Oss until an homogeneous material is obtained; the remaining part will be divided into two sterile compresses, one of which will be modeled as a resistant fibrin membrane (Figure 4) transferable to the Schneiderian membrane while the other will be transferred to the material placed in situ before closing the wound.

### **Surgical Protocol**

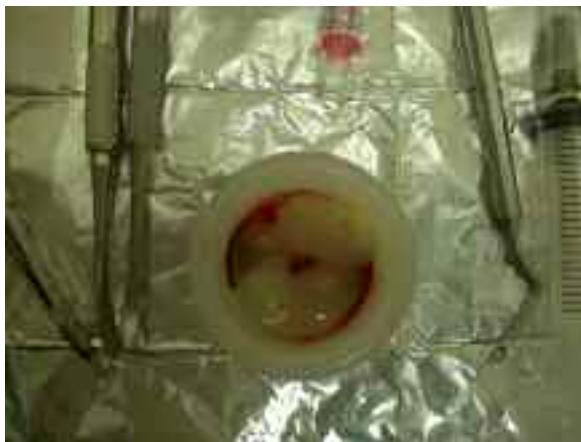As we selected cases in which the height of the residual bone was superior to 5 mm, we opted for surgical procedure of “*one-stage sinus lift*” (implant insertion occurred concurrently with si-



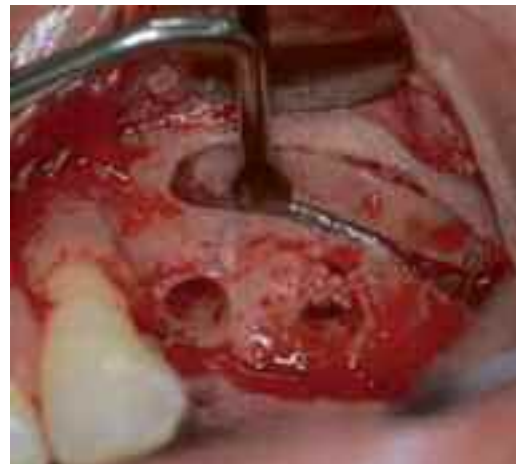**Figure 4.** Platelet-Rich Fibrin in his membranous form.

nus lift, and the healing and integration time was 6-9 months). We performed the Tatum technique<sup>28</sup> and we used the piezosurgery (Figures 5 and 6). Before inserting the implant, a small quantity of filling material was placed in the cavity. For this purpose, the bone fragment stored in saline solution was employed; after being ground, it was mixed with Bio-Oss and PRF (Figure 7). Now implants could be inserted (on average, the length was 2-4 mm in excess, compared to the height of the available bone). During the implant insertion with a slow way procedure, the filling material was displaced into the Schneiderian membrane and placed around the implant, thus avoiding the collapse of the membrane on its surface.

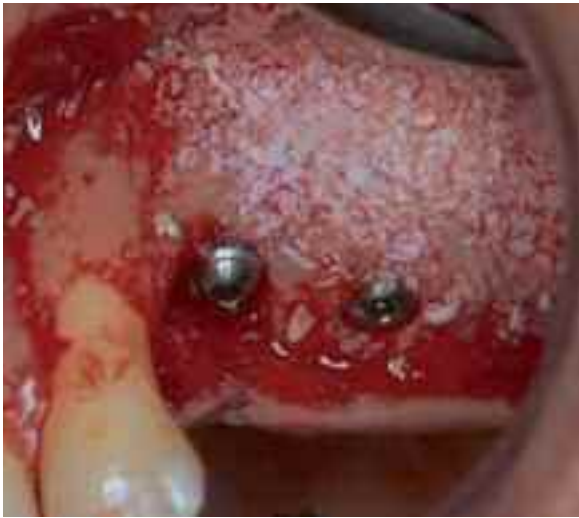The treated patients were inserted in a follow-up program which included:



**Figure 3.** Sterile cup with Platelet-Rich Fibrin in his gelly form.



**Figure 5.** Vestibular osteotomy performed by piezosurgery.



**Figure 6.** Bone window covered with filling material.

- Pharmacological treatment with amoxicillin + clavulanic acid (1 g *per os* every 12 hours for 7 days), non-steroidal anti-inflammatory drugs (Ketoprofen 100 mg *im* every 12 hours for 7 days) and chlorhexidine mouthwash (0,12%, every 12 hours for 14 days);
- Stitches removal after 7 days;
- Clinical examinations every 30 days;
- First-level radiological verifications (X-rays-OPT) and second-level radiographic examinations (Denta-Scan) after six months.

## Results

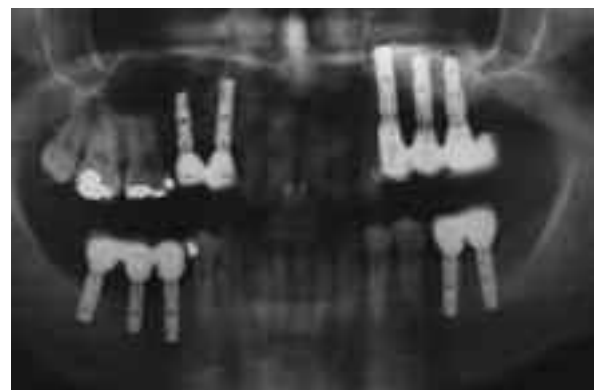
The present study involved 23 patients and 31 sinus lifts were performed, together with



**Figure 7.** Sterile cup with Platelet-Rich Fibrin mixed with Bio-Oss®.

concomitant implant insertions (95 in total). During maxillary sinus lift, there were 6 membrane perforations in 5 patients. No failure was registered; the areas with membrane perforations did not develop any postoperative complication (Figure 7). From a clinical point of view, the Authors noticed peri-implant tissue healing, without recessive phenomena or pathological conditions so serious to cause infective complications.

In all the cases included in this protocol, the Authors observed a successful implant-prosthetic rehabilitation, according with Albrektsson criteria (1986): all patients reported no pain to percussion, no sign of tissue suffering to the soft peri-implant tissues and the presence of an optimal primary stability of the inserted implants. The increase in the peri-implant bone density, which the Authors registered in the entire study population in variable proportion, was assessed by means of an Ortopantomography and DentaScan X-Rays also thanking to the personal computer and working program called Implant3D<sup>29</sup>, which allowed a three-dimensional reconstruction of the treated area. The different tomographic sections were scanned and analyzed on the personal computer, assuring that the films corresponding to pre- and post-operation conditions could be compared. The radiological examination, performed after six months, allowed to notice the presence of newly-formed bone tissue, well amalgamated with the residual bone also revealing an average increase in the peri-implant bone density of 31%. In the apical region, the Authors also noticed close contact of implants with the newly-formed bone.



**Figure 8.** X-Ray showing the post-operative condition of a patient enrolled in our study.

## Discussion

The lateral-posterior parts of the edentulous upper jaw often have anatomical limitations, which result in a continuous challenge for the dental surgeon. In these areas, in fact, the primary stability of implants and the elusion of intra- and post-operative complications may be invalidated by an inadequate three-dimensional bone support, that is to say an insufficient height and/or thickness of the alveolar crest. This bone deficiency may result from an excessive pneumatization of the maxillary sinus (large sinus cavities), from an important atrophy of the alveolar crest referable to dental extractions and/or periodontal diseases or from both of these causes<sup>9,10,18</sup>. Besides, the reabsorption process in edentulous posterior maxillary regions can determine insufficient vertical dimensions for implant positioning often requiring additional surgical procedures. These involve the use of reabsorbable and non-reabsorbable membranes, bone substitutes often combined with autologous bone, surgical expansion through Le Fort I osteotomy with interposition of bone grafts and sinus lift operations with the contextual filling of the cavity by means of several graft materials<sup>1-5</sup>. In patients presenting an interarch distance described as inadequate, the surgeon should choose an inlay graft or an increase in the bone-crestal volume at the expense of the maxillary sinus volume subject to lifting of the Schneider membrane. Many types of materials are used in sinus lift: autologous bone, demineralized and freeze-dried bone, hydroxyapatite and different combinations of these materials, often with satisfactory results in terms of biocompatibility, induction of bone formation and, of course, implant stability<sup>8,10-16</sup>. In particular, deproteinized bovine bone (Bio-Oss<sup>®</sup>) is frequently used in the clinical practice of sinus lift, as it is able to induce a physiological bone remodeling, with disposition and significant bone gain, thanks to its chemical-physical properties which are very similar to those of the human bone (the percentage of newly formed bone is around 39%)<sup>12-14</sup>. Apart from the good osteoinductive and osteoconductive properties together with a poor reabsorbability, the bovine bone mineral does not run risk the of intolerance or infection; the biocompatibility of the material is due to its preparation, aiming at eliminating the protein and lipid components from the original material, by making it inorganic before being sterilized by heat and irradiation. The data, derived

from histological and histomorphometric analyses, shows that Bio-Oss particles do not interfere with the tissue healing process. As a supplement to procedures of tissue regeneration, a platelet concentrate called PRF (Platelet Rich Fibrin) was tested for the first time in France by Choukroun et al and introduced with the European Directive n. 2004/23/CE of March 31<sup>th</sup>, 2004. Dohan et al<sup>19-21</sup>, Choukroun et al<sup>22,23</sup> reported encouraging results, by using growth factor-enriched fibrin for bone regeneration also in sinus lift. The histological analysis showed a bone growth and a better trabecular organization in areas treated with PRF and FDBA, compared to control areas which where only treated with FDBA. The rate of vital bone/inert bone of the trabecular bone, allows to appreciate the importance of a turnover. We could observe 1/3 of inert bone graft and 2/3 of new vital bone in both areas. Therefore, the Authors could conclude that, thanks to PRF, the healing time decreases so much that implant could be already placed 4 months after surgery. Four months later, histological examinations showed that the quality of bone resulted similar in the areas treated with PRF and FDBA and in the control areas. Clinical studies, concerning sinus floor lift<sup>28</sup> through osteotomes, indicate a percentage of success between 85.7% and 100%, by means of the different suggested procedures. Few studies, with a follow-up program of 5 years, report a percentage of success between 88.6% and 97%. The different materials, used for the lifting procedures (autologous bone, human and animal bone, collagen, synthetic materials), did not determine fundamental differences in the clinical results. In the clinical cases reported in the present study, there was a clinical success of 100% in sinus lift, by using PRF obtained with a laboratory centrifuge and Bio-Oss. Besides, the use of PRF reduced the healing time and brought to a faster bone regeneration<sup>19-27</sup>. Fibrin rich in growth factors is an autologous graft material which eliminates any risk of disease transmission; besides, its gelatinous consistency enhances clot and graft stability. Apart from these advantages, PRF allows to avoid the use of membranes and barriers, thus reducing the risk of possible exposure to the oral cavity and of the consequences that the bacterial contamination may have on the regenerative process. For the therapeutic success, the patients' initial motivation and their level of cooperation in the different rehabilitation phases are fundamental. Sinus lift is certainly recommended for patients in good condi-



tion, highly motivated to oral hygiene and aware from the whole surgical and prosthetic procedure. The subjects who underwent advanced osseointegration require constant monitoring and a periodical check-up from the operative staff (dental surgeon, periodontist and prosthetist).

## References

- 1) PELO S, GASPARINI G, MORO A, BONIELLO R, AMOROSO PF. Segmental Le Fort I osteotomy with bone grafting in unilateral severely atrophied maxilla. *Int J Oral Maxillofac Surg* 2009; 38: 246-249.
- 2) MUÑOZ-GUERRA MF, NAVAL-GÍAS L, CAPOTE-MORENO A. Le Fort I osteotomy, bilateral sinus lift, and inlay bone-grafting for reconstruction in the severely atrophic maxilla: a new vision of the sandwich technique, using bone scrapers and piezosurgery. *J Oral Maxillofac Surg* 2009; 67: 613-618.
- 3) CHIAPASCO M, BRUSATI R, RONCHI P. Le Fort I osteotomy with interpositional bone grafts and delayed oral implants for the rehabilitation of extremely atrophied maxillae: a 1-9-year clinical follow-up study on humans. *Clin Oral Implants Res* 2007; 18: 74-85.
- 4) STOELINGA PJ, SLAGTER AP, BROUNS JJ. Rehabilitation of patients with severe (Class VI) maxillary resorption using Le Fort I osteotomy, interposed bone grafts and endosteal implants: 1-8 years follow-up on a two-stage procedure. *Int J Oral Maxillofac Surg* 2000; 29: 188-193.
- 5) CORDARO L, TORSELLO F, ACCORSI RIBEIRO C, LIBERATORE M, MIRISOLA DI TORRESANTO V. Inlay-onlay grafting for three-dimensional reconstruction of the posterior atrophic maxilla with mandibular bone. *Int J Oral Maxillofac Surg* 2010; 39: 350-357.
- 6) FELICE P, IEZZI G, LIZIO G, PIATTELLI A, MARCHETTI C. Reconstruction of atrophied posterior mandible with inlay technique and mandibular ramus block graft for implant prosthetic rehabilitation *J Oral Maxillofac Surg* 2009; 67: 372-380.
- 7) TROMBELLI L, FARINA R, MARZOLA A, ITRO A, CALURA G. GBR and autogenous cortical bone particulate by bone scraper for alveolar ridge augmentation: a 2-case report. *Int J Oral Maxillofac Implants* 2008; 23: 111-116.
- 8) GALINDO-MORENO P, MORENO-RIESTRA I, AVILA G, FERNÁNDEZ-BARBERO JE, MESA F, AGUILAR M, WANG HL, O'VALLE F. Histomorphometric comparison of maxillary pristine bone and composite bone graft biopsies obtained after sinus augmentation. *Clin Oral Implants Res* 2010; 21: 122-128.
- 9) REINERT S, KÖNIG S, BREMERICH A, EUFINGER H, KRIMMEL M. Stability of bone grafting and placement of implants in the severely atrophic maxilla. *Br J Oral Maxillofac Surg* 2003; 41: 249-255.
- 10) SCARANO A, DEGIDI M, IEZZI G, PECORA G, PIATTELLI M, ORSINI G, CAPUTI S, PERROTTI V, MANGANO C, PIATTELLI A. Maxillary sinus augmentation with different biomaterials: a comparative histologic and histomorphometric study in man. *Implant Dent* 2006; 15: 197-207.
- 11) BRUNSVOLD MA, MELLONIG JT. Bone grafts and periodontal regeneration. *Periodontol* 2000. 1993; 1: 80-91.
- 12) YILDIRIM M, SPIEKERMANN H, BIESTERFELD S, EDELHOFF D. Maxillary sinus augmentation using xenogenic bone substitute material Bio-Oss in combination with venous blood. A histologic and histomorphometric study in humans. *Clin Oral Implants Res* 2000; 11: 217-229.
- 13) ZAFFE D, LEGHISSA GC, PRADELLI J, BOTTICELLI AR. Histological study on sinus lift grafting by Fisiograft and Bio-Oss. *J Mater Sci Mater Med* 2005; 16: 789-793.
- 14) ORSINI G, TRAINI T, SCARANO A, DEGIDI M, PERROTTI V, PICCIRILLI M, PIATTELLI A. Maxillary sinus augmentation with Bio-Oss particles: a light, scanning, and transmission electron microscopy study in man. *J Biomed Mater Res B Appl Biomater* 2005; 74: 448-457.
- 15) BROWAEYS H, BOUVRY P, DE BRUYN H. A literature review on biomaterials in sinus augmentation procedures. *Clin Implant Dent Relat Res* 2007; 9: 166-77.
- 16) HOEXTER DL. Bone regeneration graft materials. *J Oral Implantol* 2002; 28: 290-294.
- 17) MAMIDWAR. Calcium sulfate use in dentistry. *Dent Implantol Update* 2009; 20: 38-40.
- 18) SAKKA S, COULTHARD P. Bone quality: a reality for the process of osseointegration. *Implant Dent* 2009; 18: 480-485.
- 19) DOHAN DM, CHOUKROUN J, DISS A, DHOAN SL, DHOAN AJ, MOUHYI J, GOGLY B. Platelet-rich fibrin (PRF): a second-generation platelet concentrate. Part I: technological concepts and evolution. *Oral Surg Oral Med Oral Pathol Oral Radiol Endod* 2006; 101: e37-44.
- 20) DHOAN DM, CHOUKROUN J, DISS A, DHOAN SL, DHOAN AJ, MOUHYI J, GOGLY B. Platelet-rich fibrin (PRF): a second-generation platelet concentrate. Part II: platelet-related biologic features. *Oral Surg Oral Med Oral Pathol Oral Radiol Endod* 2006; 101: e45-50.
- 21) DHOAN DM, CHOUKROUN J, DISS A, DHOAN SL, DHOAN AJ, MOUHYI J, GOGLY B. Platelet-rich fibrin (PRF): a second-generation platelet concentrate. Part III: leucocyte activation: a new feature for platelet concentrate? *Oral Surg Oral Med Oral Pathol Oral Radiol Endod* 2006; 101: e51-55.

- 22) CHOUKROUN J, DISS A, SIMONPIERI A, GIRARD MO, SCHOEFFLER C, DHOAN SL, DHOAN AJ, MOUHYI J, DHOAN DM. Platelet-rich fibrin (PRF): a second-generation platelet concentrate. Part IV: clinical effects on tissue healing. *Oral Surg Oral Med Oral Pathol Oral Radiol Endod* 2006; 101: e56-60.
- 23) CHOUKROUN J, DISS A, SIMONPIERI A, GIRARD MO, SCHOEFFLER C, DHOAN SL, DHOAN AJ, MOUHYI J, DHOAN DM. Platelet-rich fibrin (PRF): a second-generation platelet concentrate. Part V: histologic evaluation of PRF effect on bone allograft maturation in sinus lift. *Oral Surg Oral Med Oral Pathol Oral Radiol Endod* 2006; 101: 299-303.
- 24) DISS A, DHOAN DM, MOUHYI J, MAHLER P. Osteotome sinus floor elevation using Choukroun's platelet-rich fibrin as grafting material: a 1-year prospective pilot study with microthreaded implants. *Oral Surg Oral Med Oral Pathol Oral Radiol Endod* 2008; 105: 572-579.
- 25) LEE HJ, CHOI BH, JUNG JH, ZHU SJ, LEE SH, HUH JY, YOU TM, LI J. Maxillary sinus floor augmentation using autogenous bone grafts and platelet-enriched fibrin glue with simultaneous implant placement. *Oral Surg Oral Med Oral Pathol Oral Radiol Endod* 2007; 103: 329-333.
- 26) KASSOLIS JD, REYNOLDS MA. Evaluation of the adjunctive benefits of platelet-rich plasma in sub-antral sinus augmentation. *J Craniofac Surg* 2005; 16: 280-287.
- 27) DHOAN DM, CHOUKROUN J, DISS A, DHOAN SL, DHOAN AJ, MOUHYI J, GOGLY B. Platelet-rich fibrin (PRF): a second-generation platelet concentrate. Part I: technological concepts and evolution. *Oral Surg Oral Med Oral Pathol Oral Radiol Endod* 2006; 101: e37-44.
- 28) WOO I, LE BT. Maxillary sinus floor elevation: review of anatomy and two techniques. *Implant Dent* 2004; 13: 28-32.
- 29) NEUGEBAUER J, STACHULLA G, RITTER L, DREISEIDLER T, MISCHKOWSKI RA, KEEVE E, ZÖLLER JE. Computer-aided manufacturing technologies for guided implant placement. *Expert Rev Med Devices* 2010; 7: 113-129.