

Atypical sarcoidosis: case reports and review of the literature

M. GIOVINALE, C. FONNESU, A. SORIANO, C. CERQUAGLIA, V. CURIGLIANO, E. VERRECCHIA, G. DE SOCIO, G. GASBARRINI, R. MANNA

Department of Internal Medicine, Catholic University of the Sacred Heart, Rome (Italy)

Abstract. – Sarcoidosis is a granulomatous disease of unknown origin, with pulmonary findings in more than 90% of patients. Extrapulmonary involvement is common and all organs can be involved (especially lymph nodes, eyes, joints, central nervous system) but it is rare to find an isolated extrapulmonary disease (less than 10% of patients). Granulomatous inflammation of the spleen and the liver is common in patients with systemic sarcoidosis, while hepatosplenic enlargement is unusual and splenic involvement rare.

We report two cases of systemic sarcoidosis, that onset with splenic and hepatosplenic disease, and one case with splenic sarcoidosis without pulmonary involvement.

In the first case a 53-year-old woman with mild abdominal pain underwent sonography and CT, which revealed one hypoechoic/hypodense splenic lesion. Laboratory tests were normal. In order to exclude a lymphoma, splenectomy was performed: histology revealed a sarcoid granuloma. After surgery the patient was asymptomatic and now, after two years, disease is silent.

The second case is a 66-year-old woman with a recent weight loss (8 kg in two months) and altered liver function tests (AST 61 U/l, ALT 72 U/l, Alkaline phosphatase 748 U/l, g-GT 381 U/l). Since she had a familiar history of colon cancer, abdominal US scan, abdominal CT scan and MRI were performed and showed inter-aorto-caval lymphadenopathies and discreet multiple bilobar hepatic and splenic substitutive lesions, with no signs of primary tumor. Upper and lower GI endoscopy, full gynecological workup, complete set of tumor markers, bone marrow biopsy were performed. All resulted negative for neoplasia. Small pulmonary infiltrations were observed on chest-CT scan but cytology on BAL was normal. Infections were also excluded. An exploratory laparotomy showed whitish peritoneal, hepatic and splenic nodules. The histological exam revealed chronic granulomatous lesions typical for sarcoidosis. During a two-year follow-up after the splenectomy the patient feels well without any treatment.

The third patient is a 32-year-old woman with mild epigastric pain after meals. Neck-thoracic CT, bone scintigraphy and upper GI endoscopy were negative. Abdominal US and MR showed splenomegaly with multiple splenic lesions. Splenectomy was performed and histological exam showed chronic granulomatous lesions typical for sarcoidosis. Further laboratory tests were normal, except for ACE (66 U/l). After the surgery ACE became normal and now, three years later, the patient is still asymptomatic.

We conclude that hepatosplenic involvement is less rare than it is thought. It is often oligosymptomatic or accompanied with unspecific manifestations and laboratory abnormalities. The diagnosis could be difficult; in fact typical laboratory findings of sarcoidosis such as ACE, lysozyme, calcium, were not diagnostic. Ultrasonography and CT were important but the diagnosis was established only with the histological examination of suspected lesions. This latter required to differentiate liver and/or spleen sarcoidosis from tuberculosis and other infections, primary biliary cirrhosis, metastasis or malignant lymphoma.

Key Words:

Sarcoidosis, ACE, Hepatosplenic involvement, Pulmonary granulomatous lesions.

Introduction

Sarcoidosis is a systemic granulomatous disease of unknown origin, characterized by the presence of non-caseating granulomatous lesions^{1,2}. It is a ubiquitous disease with a prevalence (varying according to age, sex, race and geographic origin) estimated at around 16.5/100,000 in men and 19/100,000 in women¹. Although possible at all ages, sarcoidosis usually presents in adults under 40³. The lungs are involved in more than 90% of patients³. Therefore, chest X-ray remains a key investigation for diag-

nosis¹. There are four stages of pulmonary sarcoidosis, based on the presence of lymphadenopathy and pulmonary infiltrations with or without fibrosis¹. Pulmonary sarcoidosis may be asymptomatic in up to 60% of patients⁴. Dry cough and dyspnoea may be present⁵.

Although the lung is predominantly affected, virtually every organ may be involved, including skin, eye and abdominal organs⁴. Frequently, extrapulmonary manifestations of the disease are the major cause of morbidity⁶.

Extra-thoracic disease can occur in association with or in the absence of intra-thoracic disease⁷. Isolated extrapulmonary manifestations of sarcoidosis occur in only 10% of cases⁸.

Because sarcoidosis can involve any organ system, the clinical presentation is often variable. Common symptoms are vague, such as fatigue, weight loss, fever and night sweats¹. Löfgren's syndrome, an acute presentation consisting of erythema nodosum, arthritis and bilateral hilar adenopathy, occurs in 9 to 34% of patients⁵. Sarcoidosis sometimes onsets such as Heerfordt syndrome, an acute variant of the disease, that is characterized by parotid gland enlargement, fever, uveitis and cranial nerve palsies⁹. Two thirds of patients with sarcoidosis generally have few or no consequences without relapses. Unfortunately, up to a third of patients have unremitting disease, leading to clinically significant organ impairment⁵.

Routine laboratory evaluation is often unrevealing. However, peripheral lymphopenia with CD4 depletion, elevated levels of serum-angiotensin converting enzyme (S-ACE), lysozyme, β -2 microglobulin, hypercalcemia and hypercalciuria can help the diagnosis¹⁰. ACE¹¹, in particular, is elevated in 60% of cases, whereas hypercalcemia or hypercalciuria occur in about 10-40% of patients⁵. Lymphocytic alveolitis with a high CD4/CD8 ratio in bronchoalveolar lavage (BAL) fluid is highly suggestive of the disease¹⁰.

The diagnosis of sarcoidosis is based on compatible clinical and radiographical findings, but the most important criterion used for final diagnosis is patho-histological evidence of epithelioid non-caseating granuloma in biopsic material of lymph node, skin, lung or other accessed organs⁹. If pulmonary tissue is required, transbronchial biopsy by means of bronchoscope has a diagnostic yield of at least 85% when multiple lung segments are sampled. A diagnosis of sarcoidosis is reasonably certain without biopsy in patients who present with Löfgren's syndrome⁵.

Because sarcoidal granulomas have no unique histological features to differentiate them from other granulomas, alternative granulomatous disease must be excluded^{1,9,12}. These include neoplasia (lymphoma and solid tumours), autoimmunity disorders (Wegener's granulomatosis and primary biliary cirrhosis), farmer's lung disease (hypersensitivity pneumonitis), drug reactions, occupational and environmental exposures (e.g. beryllium, talc) and infections^{1,9,12}. Therefore, stains and culture for fungi and mycobacteria should always be obtained when the diagnosis of sarcoidosis is considered¹². In infants under four years old, the Blau syndrome has also to be considered, especially in absence of thoracic involvement^{1,6}.

We report three cases with atypical sarcoidosis, in which ultrasound, CT scan and Magnetic Resonance Imaging (MRI) of abdomen can guide the diagnosis of sarcoidosis. In particular, this report shows a rare case of isolated granulomatous disease of the spleen diagnosed and treated laparoscopically, and two cases of unusual presentation of systemic sarcoidosis that onset with early nodular hepatosplenic and splenic lesions, respectively.

Case Reports

Case 1

A 53-years-old woman was presented to the Department of Internal Medicine, with a 3 months history of epigastric repletion. She did not present pyrosis, acid regurgitation, or retrosternal burning. On physical examination the patient had tender splenomegaly. Laboratory studies were in normal range. The X-ray of the chest, electrocardiogram and echocardiography were normal. Endoscopic assessment of the esophagus revealed reflux esophagitis (Los Angeles classification Grade B). Abdominal ultrasonographic scan was performed. Multiple cysts varying in size from 0.5 cm to 5 cm were scattered in the liver. The spleen was enlarged, with isolated hypoechogenic nodular lesion localized in the upper-median part of spleen. Color and power Doppler imaging did not show any hypervascularity. On contrast-enhanced computed tomography (CECT) of the abdomen (Figure 1), the splenic lesion was hypodense relative to adjacent normal spleen. Peripheral enhancement was not seen after intravenous

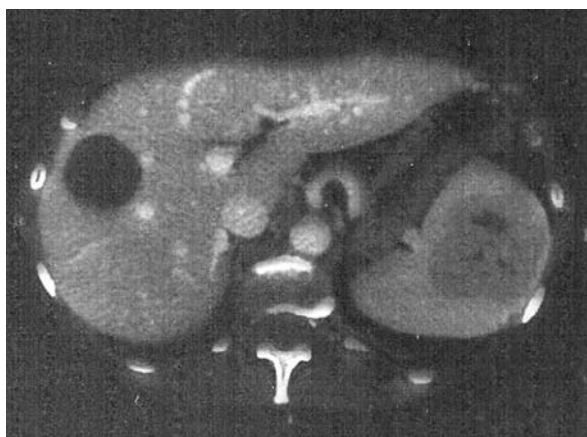


Figure 1. Contrast-enhanced CT scan shows splenomegaly with isolated hepatic cyst and splenic hypodense nodule.

contrast injection. In view of the possibility of this lesion representing a lymphoma, a fine-needle aspiration and small-gauge core biopsy of spleen were performed under ultrasound guidance and showed no malignant cells. Further laboratory tests, including serologic tests for viruses and bacteria and Tuberculin skin test, were negative. At this point, splenectomy was recommended. Macroscopically the spleen had a brownish appearance. The spleen measured $13 \times 7 \times 7$ cm and weighed 240 g. On sectional view whitish nodular lesion was found, with a cranio-caudal diameter of 5.5 cm. On histological examination, light microscopic appearance of the spleen was characterised by non caseating granulomas typical for compatible with sarcoidosis. Pathologic examination revealed also presence of sarcoidosis in three lymph nodes of the splenic hilum. Further laboratory test (see Table I), including serum ACE, lysozyme, calcium, liver enzymes (alanine transaminase, aspartate transaminase, al-

kaline phosphatase), creatinine, blood urea nitrogen levels and urine analysis were in normal range. Chest high resolution computed tomography (HRCT) corresponded to age, and no hilar adenopathy was observed. The pulmonary function test demonstrated normal spirometry with normal diffusing capacity monoxide. The final diagnosis was splenic sarcoidosis. The patients did well with no further treatment and after second-year follow-up had no sign of thoracic involvement.

Case 2

A 66-year-old woman was scheduled to remove a benign cheek nevus. On admission to the Department of Surgical Science, the patient was asymptomatic and physical examination was essentially negative. Pre-operative laboratory tests were normal except for liver enzymes levels, which were elevated: Alanine transaminase (AST) = 72 U/l (normal 4-37 U/l), Aspartate transaminase (ASP) = 61 U/l (normal 9-38 U/l), Alkaline phosphatase (AP) = 748 U/l (normal 42-172 U/l), g-glutamyl-transpeptidase, g-GT = 381 U/l (normal 8-45 U/l). Serological tests for hepatitis A, B and C virus and Mantoux test were negative. Autoantibody screens, including antinuclear antibody (ANA), antimitochondrial antibody (AMA), smooth-muscle antibody (SMA) and liver kidney microsome antibody (LKM) were all in normal range. Electrocardiogram and chest x-ray were normal. Ultrasound of the abdomen scan showed multiple bi-lobar large-nodes liver lesions, suspected for metastases. Recent weight loss (8 kg in two months) without change in nutrition habits and a familiar history of colonic cancer were present. For this reason, a

Table I. Laboratory finding of the patient 1.

Parameters	Values	Normal range
ACE	45 U/l	8-52 U/l
Lysozyme	0.10 mg/l	< 2 mg/l
Lysozyme/creatinine	0.08 mg/l	< 2 mg/l
Serum calcium	9.3 mg/l	8.5-10.5 U/l
24 h urine calcium	221 mg	100-250 mg
CRP	2 mg/l	< 5 mg/l
AP	50 U/l	38-126 U/l
γ GT	37 U/l	0-85 U/l
ALT	45 U/l	0-50 U/l

complete set of serum markers, including CEA, CA 19.9, CA-125 were made without positive response. Oesophago-gastro-duodenoscopy and colonoscopy showed no macroscopic or histological signs of primary tumor. CT scan (Figure 2) and MRI of the abdomen documented inter-aorto-caval lymph adenopathies and multiple bilobar hepatic and splenic substitutive lesions. Because the findings were highly suspicious of tumor, GI endoscopy, colonoscopy and full gynecological workup, including trans-vaginal sonography (TVS), were performed but they were all negative. A flow cytometric evaluation of the bone marrow was negative for hematologic tumors and a bone marrow core biopsy specimen revealed normocellular marrow with maturing trilineage hematopoiesis.

Conversely, CT chest showed peri-broncovascular interstitial thickening and two small nodules, without adenopathies. The cytology on BAL was negative for neoplastic cells.

At this point, both fine needle aspirate and biopsy of liver were carried out. Histology and cytology on lesions reported mild hepatocyte dysplasia with focal areas of necrosis. Because the histological exam of liver biopsy specimen was unclear, she underwent an exploratory laparoscopy (Figure 3). Macroscopic examination showed whitish peritoneal, hepatic and splenic nodules. Pathologic findings revealed chronic non caseating epithelioid cell granulomas with Langhans multinucleated giant cells, diagnostic of sar-

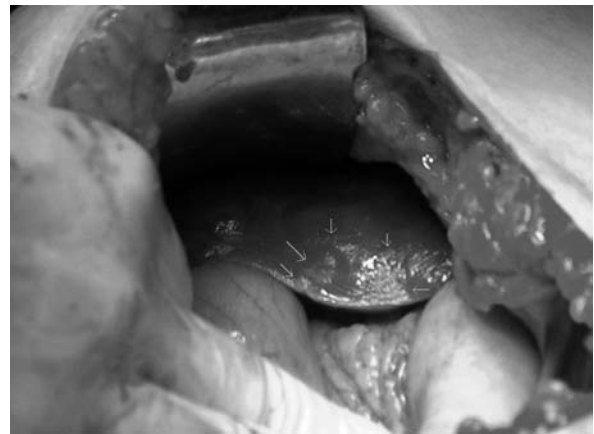


Figure 3. Photograph obtained at laparoscopy reveals plaques studding liver, corresponding to sarcoid granulomas.

coidosis. Further laboratory studies showed no ACE, calcium or lysozyme abnormalities. The final diagnosis was sarcoidosis, with hepatosplenic involvement (nodular pattern). After four months of steroid therapy (prednisone 25 mg/die), liver enzymes values nearly normalized, and sonography showed the reductions of hepatosplenic lesions.

Case 3

A 32-year-old woman complaining of epigastric repletion after meals, was admitted to the hospital. She did not have weight loss or fever. Physical examination revealed mild pain by palpation in the left upper abdomen. Laboratory finding at admission were in normal range, apart from blood counts, which showed a mild anaemia (Hb 10.6 g/dl). Electrocardiogram, heart ultrasound and X-ray of the chest were normal. Hiatus hernia and erosive esophagitis were discovered at upper endoscopy. So reason, she was treated with pump proton-inhibitors (PPIs) for three months, with no good response. Ultrasonographic examination of the upper abdomen revealed an heterogeneous enlarged spleen with numerous round hypoechogenic, approximately 1.5 cm nodules, in the spleen. Liver and lymph nodes were normal. Evaluation by MRI showed multiple foci that correlated with US. Mycobacterial, fungal, bacterial and parasitic infections were excluded. Neck and thoracic CT were carried out but were not suggestive of lymphoma or solid neoplasm. Moreover, there was no evidence

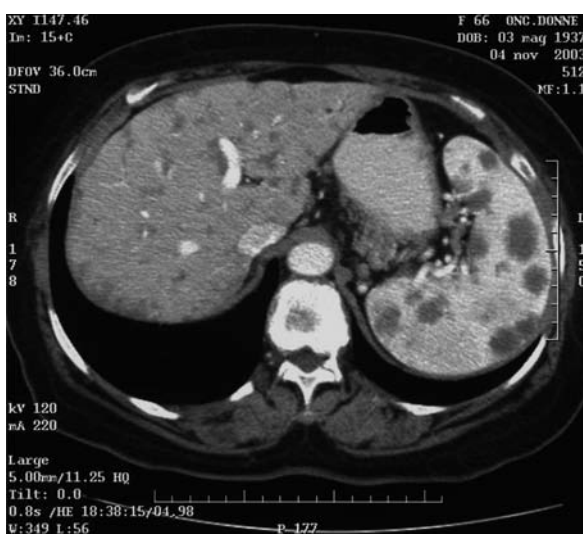

Figure 2. Contrast-enhanced CT scan shows hepatosplenomegaly with multiple small hepatic and splenic hypodense nodules.

of skeletal abnormality on bone scintigraphy. At this point, the patient underwent a laparoscopic splenectomy. Then the specimen was sent to the Pathologic Department. Macroscopically the spleen had elastic consistence with many nodules on the surface. The weight and size of the spleen were 280 g and $15 \times 7.4 \times 6$ cm, respectively. Special stains were negative for both acid fast and fungal organisms and final pathology report showed extensive involvement of the splenic parenchyma by non caseating epithelioid granulomas, accompanied by giant multinucleated cells, consistent with the sarcoid-like reaction. Together with these findings an increased activity of the ACE (66 U/l) indicated splenic sarcoidosis. Postoperative examination showed no change compared to preoperative findings, except for CT of the chest, which revealed mediastinic, paratracheal, thraceobrochial and hilar sub-centimetric lymphadenopathies, whereas skull-TC was normal. Because the patient had no respiratory symptoms, she was not treated with systemic corticosteroids. After, three years the patient was still asymptomatic. C-reactive protein (0.5 mg/dl) and erythrocyte sedimentation rate (11 mm/hr) were normal. ACE was 44 U/l. CT of chest revealed no change of pulmonary lesions and the reduction of mediastinic and bilateral hilar lymph adenopathies. Abdominal TC was unchanged.

Discussion

Sarcoidosis is a granulomatous disease of unknown aetiology¹. Lung and lymphatic system are the principal localizations¹. Clinical presentations are various depending on involved organs¹³. Some clinical manifestations, which are typical and frequent, are easily recognized¹³. The unusual and less frequent presentations, such as nodular lesions of spleen and/or liver², are difficult to diagnose in absence of clinical suspicious of sarcoidosis. The diagnosis of sarcoidosis could be more complicated especially if abdominal sarcoidosis represents the exclusive involvement without systemic disease.

Clinical studies indicate involvement of the liver and spleen in approximately 20-30% of patients affected with sarcoidosis and their detection should be based on a standardized diagnostic procedure¹⁴.

Involvement of the abdominal viscera frequently occurs in the context of more extensive chest disease (such as the two above-mentioned patients), but abdominal sarcoidosis without pulmonary or mediastinic involvement is not rare, such as our patient with isolated splenic sarcoidosis⁹.

Spleen Involvement of Sarcoidosis

Autopsy studies have revealed splenic involvement in 38-77% of patients with disease⁹. Moreover, isolated splenic sarcoidosis is rare⁹. We have described three patients with sarcoidosis of spleen. The first patient presented only isolated sarcoidosis splenic without systemic disease, but the others developed pulmonary involvement.

Symptoms

Sarcoidosis of the spleen does not usually cause symptoms. Left upper quadrant abdominal pain and systemic symptoms, including fever, malaise and weight less occasionally occur in number of patients with sarcoidosis of spleen^{15,16}. Two out of three patients, that we have described, presented epigastric repletion.

Laboratory tests

Laboratory tests are usually normal¹. However, patients with splenic involvement can develop anaemia, thrombocytopenia and neutropenia¹. Two of the three patients, that we have presented, have no blood counts abnormalities, but the third patient was anaemic. A linear relationship between serum ACE level and spleen size as well as between ACE level and the presence of hepatosplenic nodules was observed⁹. ACE level of our patients were in normal range, apart from ACE levels of third case. One study documented that the mean serum ACE level was 3.1 times the upper limits in the patient with splenic nodules while the mean ACE level was 1.3 times the normal level in cases without splenic nodules⁹.

Radiology

Diagnostic image scanning methods, including abdominal ultrasonic scan, contrast-enhanced CT, MRI, and Ga or Tc scintiscan) can easily detect the splenic lesion¹⁷.

Splenomegaly (greatest splenic dimension >14 cm)⁹ is the most common splenic manifestation⁹. The organ is usually homogeneous, but multiple low-attenuating nodular lesions are occasionally noted and easily mistaken for lymphoma, metastases or infections¹⁸. Isolated or predominant in-

involvement of the spleen by nodules is more common than isolated or predominant hepatic nodular disease⁹. In fact, we have seen that all patients present splenic sarcoidosis on admission to Hospital but only in one there were hepatic nodules. Only in one of these cases the sarcoid splenic lesion was single and isolated.

Treatment and Prognosis

Our patients required a laparoscopic splenectomy for diagnostic purposes. Indications for splenectomy, in fact, include symptomatic splenomegaly, severe hypersplenism, prophylaxis for splenic rupture, and neoplastic exclusion⁸. The extent of pulmonary involvement, once splenic sarcoidosis diagnosed, it was evaluated both at the diagnosis and subsequent follow-up visits. We have seen that the progressive development of the disease is variable: the patient first described with initial diagnosis of isolated splenic sarcoidosis did not present pulmonary involvement for two subsequent follow-up years, while the other two patients developed a systemic sarcoidosis.

Because the first and third patients were asymptomatic, we have not started medical therapy with prednisone, methotrexate, and/or anti-malarial drugs. In these cases, in fact, the splenectomy resulted an efficacious treatment.

Liver Involvement of Sarcoidosis

Our case shows that the diagnosis of sarcoidosis of liver may be difficult. Autopsy studies on subjects with systemic sarcoidosis revealed liver involvement in 44, 6%⁷. Although evidence of liver involvement is frequently obtained at microscopy examination, symptomatic liver disease occurs in less than 5% of patients with sarcoidosis^{7,9}. For this reason, diagnosis of liver sarcoidosis is difficult¹⁹. Isolated liver involvement without lung disease is less frequent, and seen in only 13% of patients with sarcoidosis²⁰.

Symptoms

Hepatic sarcoidosis covers a broad spectrum from asymptomatic hepatic granulomas and slightly deranged liver function tests to clinically evident disease^{19,21}. Systemic symptoms are represented by fever, weight loss, and asthenia⁹ but these manifestations are not present in our patient with hepatosplenic involvement. Other clinical hepatic manifestations of sarcoidosis may include jaundice (consistent with intra or extrahepatic chronic cholestasis), itching, anorexia and

abdominal pain. These two last manifestations are present in our patient. Portal hypertension with variceal bleeding, hepatopulmonary syndrome with refractory hypoxemia, and cirrhosis leading to liver failure occur in only 1% of patients with sarcoidosis^{5,19}. Budd Chiari syndrome is described rarely^{19,21}. Chronic intrahepatic sarcoid cholestasis can mimic sclerosing cholangitis or primary biliary cirrhosis^{20,22}. Involvement of hepatic duct can mimic Klatskin's cholangiocarcinoma²³. Moreover, sarcoidosis can coexist with these two diseases²⁰. Extra hepatic sarcoid disease can involve the common duct or compress the hepatic hilum by adenopathies¹⁹.

Laboratory Tests

Laboratory evidence of liver dysfunction is seen in 2-60% of patients⁹, as the second case report that we described. Alkaline phosphatase level is most commonly affected⁹. Other laboratory tests often show an increase in γ GT, CA 19-9 (as in other cholestatic diseases) and in IgA and IgG²⁴. ACE is increased in 55-91% of patients and false-positive results are <5%^{5,20}. ACE, calcium and lysozyme were not increased in our second patient.

Radiology

About liver sarcoidosis, imaging includes ultrasonography, CT, contrast-enhanced CT and MRI²⁵. The most common radiographic finding of hepatic sarcoidosis is hepatomegaly. Focal nodules are also noted in the livers of patients with sarcoidosis⁹, such as is observed in our second patients. The nodules are typically numerous and variable in size (ranging from 1 mm to 3 cm in diameter²⁵). In our case (second case), there was hepatomegaly with multiple nodular pattern.

Treatment and Prognosis

When the only manifestation is non caseating granulomas, with no evidence of symptoms related to the liver or a sign of liver dysfunction, no treatment is needed¹⁹. The decision to treat should be based on symptoms and severity of disease. In our patient, we have used glucocorticoid treatment, which represents first-line therapy for hepatic sarcoidosis, improving symptoms and abnormal laboratory values. However, steroids generally have no effect on progression of disease. Alternatives drugs (e.g. azathioprine, methotrexate, hydroxychloroquine) to corticosteroids have been tried, and their use has primarily been limited to steroid refractory disease^{26,27}.

In these cases, Infliximab can be useful²⁶. However, there is no drug that has been shown to prevent progression of disease. In advanced sarcoidosis of liver, the transplantation is considered the definitive treatment^{26,27}.

Conclusion

Sarcoidosis is a systemic granulomatous disease. It can occur with atypical onset such as splenic or hepatosplenic involvement. It is also possible that there is an exclusive involvement of these organs without pulmonary disease.

Similar findings have been noted in other studies in which the authors concluded that there was no correlation between the degree of chest abnormality and the involvement of liver and spleen⁹. In these cases, however, the diagnosis of sarcoidosis could be very difficult because sarcoidosis is usually not suspected.

In fact hepatosplenic or/and splenic sarcoidosis is often asymptomatic or accompanied by unspecific symptoms and laboratory abnormal values, although it is possible that serum levels of Alkaline phosphatase increase. SACE, lysozyme, urine and serum calcium, were present infrequently in isolated extrapulmonary sarcoidosis and often in systemic form with hepatic and splenic disease, especially if spleen is involved. US and CT were important but the diagnosis was established only with the histological examination of suspected lesion, that is required to differentiate liver and/or spleen sarcoidosis from tuberculosis, primary biliary cirrhosis, metastasis or malignant lymphoma and other granulomatous diseases. After diagnosis, continual follow-up for systemic manifestations is indicated. Asymptomatic spleen and liver sarcoidosis usually has a good prognosis also without medical therapy; by contrast, treatment of hepatic sarcoidosis should be started for patients who developing laboratory abnormalities or some symptoms.

References

- 1) NUNES H, BOUVRY D, SOLER P, VALEYRE D. Sarcoidosis. *Orphanet J Rare Dis* 2007; 2: 46.
- 2) THANOS L, ZORMPALA A, BROUNTZOS E, NIKITA A, KELEKIS D. Nodular hepatic and splenic sarcoidosis in a patient with normal chest radiograph. *Eur J Radiol* 2002; 41: 10-11.
- 3) WU JJ, SCHIFF K. Sarcoidosis. *Am Fam Physician* 2004; 70: 312-322.
- 4) JUNDSON MA. Hepatic, splenic and gastrointestinal involvement with sarcoidosis. *Semin Resp Crit Care Med* 2002; 23: 529-541.
- 5) IANNUZZI MC, RYBICKI PA, TEIRSTEIN AS. Sarcoidosis. *N Engl J Med* 2007; 357: 2153-2165.
- 6) JUDSON MA. Extrapulmonary sarcoidosis. *Semin Respir Crit Care Med* 2007; 28: 83-101.
- 7) KATAOKA M, NAKATA Y, HIRAMATSU J, OKAZAKI K, FUJIMORI Y, UENO Y, TANIMOTO Y, KANEHIRO A, TADA S, HARADA M. Hepatic and splenic sarcoidosis evaluated by multiple imaging modalities. *Intern Med* 1998; 37: 449-453.
- 8) ZIA H, ZEMON H, BRODY F. Laparoscopic splenectomy for isolated sarcoidosis of the spleen. *J Laparoendosc Adv Surg Tech A* 2005; 15: 160-162.
- 9) WARSHAUER DM, LEE JKT. Imaging manifestations of abdominal sarcoidosis. *AJR* 2004; 182: 15-28.
- 10) BERGOIN C, LAMBLIN C, WALLAERT B. Biological manifestations of sarcoidosis. *Ann Med Interne (Paris)* 2001; 152: 34-38.
- 11) BAUDIN B. Angiotensin I-converting enzyme (ACE) for sarcoidosis diagnosis. *Pathol Biol (Paris)* 2005; 53: 183-188.
- 12) JUNDSON MA. Sarcoidosis: clinical presentation, diagnosis and approach to treatment. *Am J Med Sci* 2008; 335: 26-33.
- 13) BOUVRY D, UZUNHAN Y, NACCACHE JM, NUNES H, BRILLET PY, VALEYRE D. Atypical sarcoidosis. *Rev Med Interne* 2008; 29: 46-53.
- 14) SKODRIĆ-TRIFUNOVIĆ V, VUCINIĆ V, COLOVIĆ R, VIDENOVIĆ J, ZUGIĆ V, STOJSIĆ J. Liver and splenic sarcoidosis: diagnostic procedures. *Med Pregl* 2004; 57: 462-466.
- 15) WARSHAUER DM. Splenic sarcoidosis. *Semin Ultrasound CT MR* 2007; 28: 21-27.
- 16) JUDSON MA. Sarcoidosis: clinical presentation, diagnosis and approach to treatment. *Am J Med Sci* 2008; 335: 26-33.
- 17) KITAMURA M, ISHIZAKI T. Sarcoidosis of the liver and spleen in Japan. *Nippon Rinsho* 1994; 52: 1595-1598.
- 18) MOHAN A, SOOD R, SHARIFF N, GULATI MS, GUPTA SD, DUTTA AK. Sarcoidosis manifesting as massive splenomegaly: a rare occurrence. *Am J Med Sci* 2004; 328: 170-172.
- 19) BLICH M, EDOUTE Y. Clinical manifestations of sarcoid liver disease. *J Gastroenterol Hepatol* 2007; 19: 732-737.
- 20) HARDER H, BUCHER MW, FROHLICH B, STROBEL P, BERGMANN F, NEFF W. Extrapulmonary sarcoidosis

of liver and pancreas: a case report and review of the literature. *World J Gastroenterol* 2007; 13: 2504-2509.

- 21) KARAGIANNIDIS A, KARAVALAKI M, KOULAOUZIDIS A. Hepatic sarcoidosis. *Ann Hepatol* 2006; 5: 251-256.
- 22) TOMBAZZI C, WATERS B, ISMAIL MK, SYLVESTRE PB, MARTINEZ-HERNANDEZ A, RIELY CA. Sarcoidosis mimicking primary sclerosing cholangitis requiring liver transplantation. *Ann Hepatol* 2008; 7: 83-86.
- 23) PUNGPAPONG S, STEERS JS, WALLACE MB, KRISHNA M, KEAVENY AP. Hepatobiliary sarcoidosis mimicking Klatskin's cholangiocarcinoma. *Gastrointest Endosc* 2006; 64: 124-126.
- 24) PÉREZ-GRUESO MJ, REPISO A, GÓMEZ R, GONZALEZ C, DE ARTAZA T, VALLE J, GARCÍA A, CARROBLES JM. Splenic focal lesions as manifestation of sarcoidosis: Characterization with contrast-enhanced sonography. *J Clin Ultrasound* 2007; 35: 405-408.
- 25) DOURAKIS SP, COKKINOS DD, SOULTATI AS, ALEXOPOULOU A, NEZI V, ARCHIMANDRITIS AJ. A case of liver sarcoidosis mimicking cirrhosis. *Clin Imaging* 2007; 31: 47-49.
- 26) AYYALA US, PADILLA ML. Diagnosis and treatment of hepatic sarcoidosis. *Curr Treat Options Gastroenterol* 2006; 9: 475-483.
- 27) KENNEDY PTF, ZAKARIA N, MODAWI SB, PAPADOPOULOU AM, MURRAY-LYON I, DU BOIS RM. Natural history of hepatic sarcoidosis and its response to treatment. *Eur J Gastroenterol Hepatol* 2006; 18: 721-726.