

Ophthalmological aspects of IBD

C. MANGANELLI, S. TURCO, E. BALESTRAZZI

Department of Ophthalmology, Catholic University of the Sacred Heart, Rome (Italy)

Abstract. – Ocular manifestations occur in 4-12% of patients with IBD. Uveitis and iritis are more frequently associated with ulcerative colitis while episcleritis is more common in Crohn's disease. Some ocular manifestations in IBD can be secondary to treatment and/or effects of the intestinal disease itself.

The specific management of ocular manifestations in IBD requires the use of topical steroids and FANS, cycloplegics, systemic steroids or immunosuppressive drugs.

When conventional therapies fail to control the ocular manifestations in IBD, the new biologic drugs can be considered as good alternative treatments. Early diagnosis and effective treatment may avoid the onset of severe and sometimes persisting complications. In some cases, a surgical approach is required to treat eye complications, i.e. cataract, and to improve the patient's quality of life.

Key Words:

Ocular manifestations, Uveitis, Episcleritis, IBD.

Introduction

Systemic and extraintestinal manifestations (EIM) are common in patients with Inflammatory Bowel Disease (IBD). These manifestations can involve almost any organ, however the eyes with skin, joints and biliary tract are most frequently affected.

The occurrence of one EIM predisposes to other extracolonic involvements (ocular and/or joint manifestations have been described in 50 to 90% of patients affected by active IBD and pyoderma gangrenosum).

Pathophysiological mechanisms of EIMs in IBD are not clearly understood, but genetic and immunologic factors play an important role.

Genetic polymorphisms not only determine the susceptibility of developing Crohn's disease or ulcerative colitis but also influence the phenotype of the disease, including EIMs.

Immunological mechanisms are linked to autoimmunity. Many observations confirm the presence of autoantibodies in patients with IBD and the occurrence of immunologic interactions between bacterial endotoxins and host immune system. The efficacy of immunomodulatory therapies confirms this autoimmune hypothesis.

Ocular manifestations occur in 4-12% of patients with IBD (Table I).

Uveitis and iritis are more frequently associated with ulcerative colitis while episcleritis is more common in Crohn's disease. Other described eye complications are: conjunctivitis, keratitis, scleritis, retinal vasculitis, papillitis and orbital myositis. These manifestations are usually associated with active bowel disease, but asymptomatic uveitis can occur more frequently in patients with Crohn's colitis (18%) rather than in those with small bowel lesions. Since asymptomatic uveitis has been reported in IBD children with a frequency of 6% slit-lamp routine examination is recommended in this group of patients.

Some ocular manifestations in IBD can be secondary to treatment and/or effects of the intestinal disease itself (i.e. steroid cataract or emeralopia and xerophthalmia due to vitamin A malabsorption).

Table I. Ocular manifestations of IBD.

Episcleritis, scleritis
Uveitis
Neurophthalmologic complications (papillitis, retrobulbar neuritis, neuroretinitis)
Retinal vascular disease
Corneal infiltrates
Orbital pseudotumour
Orbital myositis
Recurrent nonspecific follicular conjunctivitis
Nonspecific blepharitis
Lid swelling

Clinical Pictures

Episcleritis (Figure 1) is an inflammation of the episclera presenting with hyperemia of the conjunctiva and episclera. It is generally painless and can occur in nodular or diffuse forms. Scleritis is rare, bilateral in 1/3 of cases. Acute pain, deep and periorbital is characteristic. An important visual loss can be present in 30% of cases and the eye is deeply red. Four different forms are described: anterior nodular scleritis, anterior diffuse scleritis, necrotizing scleritis without inflammatory signs (scleromalacia perforans), posterior scleritis. It is generally associated with systemic diseases mostly RA and Wegener's disease, but an association with IBD is reported. The diagnosis is clinical and additional information can be derived by fluorescein angiography or UBM echography.

Anterior uveitis in IBD is classified as an endogenous non infectious inflammation of the anterior uvea. Pain, photophobia, tearing and blurred vision are characteristic, but sometimes it can be asymptomatic. The clinical picture is characterized by hyperemia, perikeratic injection, exudates in the anterior chamber, keratic precipitates and iris involvement. The diagnosis is clinical.

Retinal vasculitis can involve arterial or venous vessels with peri or endovasculitis. Periphlebitis is the most frequent manifestation. Vascular walls show diffuse or focal sheathing and infiltration. Vasculitis can induce vascular occlusion with following neovascularization and retinal hemorrhages. Fluorescein angiography is

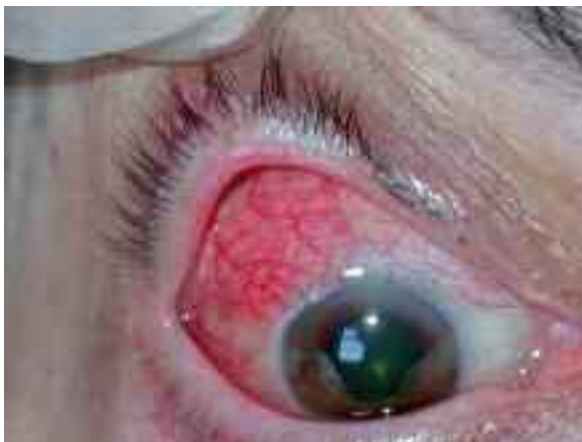

Figure 1. Episcleritis.

the main diagnostic investigation. Signs of occlusive arteritis can predominate in patients affected by periarteritis with cotton wool spots, ischemia and neovascularization.

Retinal vasculitis may lead to cystoid macular edema (Figure 2) and/or optic disc edema and optic atrophy.

Papillitis (Figure 3) is inflammation of the optic nerve head based on immunoallergic phenomena. The mechanism is related to a vasculitis and perivasculitis process involving retinal and neuroretinal vessels. It can be transient and reversible or it may proceed toward optic atrophy. Fluorescein angiography and perimetry are employed for the diagnosis.

Corneal infiltrates are clumps of leukocytes: they can occur in association with active corneal infections or under sterile conditions for an immunologic response. The overlying cornea can be normal or show an epithelial defect with a central or peripheral ulcer.

Treatment

Some extraintestinal manifestations may respond to underlying IBD treatment.

Episcleritis is generally influenced by the activity of the intestinal disease while uveitis tends to have an independent course.

The specific management of ocular manifestations in IBD requires the use of topical steroids and FANS, cycloplegics, systemic steroids or immunosuppressive drugs such as cyclosporine A, methotrexate, tacrolimus, azathioprine for the autoimmune pathogenetic mechanism.

When conventional therapies fail to control the ocular manifestations in IBD, the new biologic drugs can be considered as good alternative treatments. Tumor Necrosis Factor- α blockade

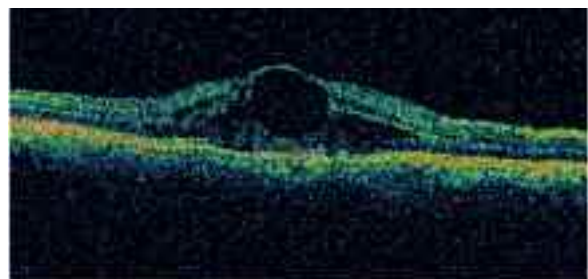


Figure 2. Severe macular edema (OCT).

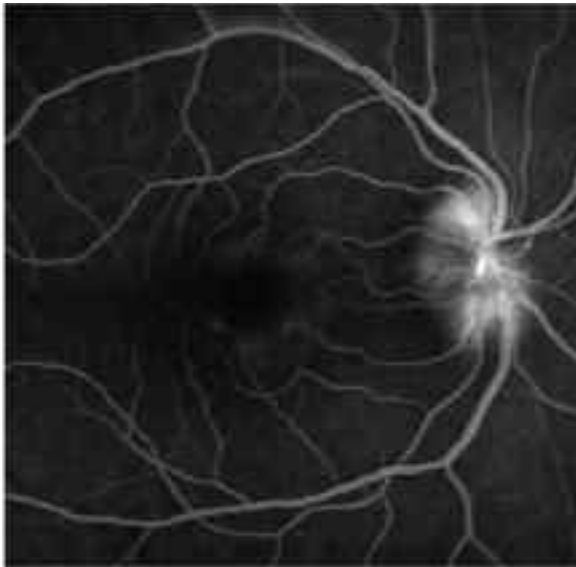

Figure 3. Papillitis (fluorescein angiography).

has been effective after failure of conventional immunosuppression since TNF- α is a proinflammatory cytokine which has been implicated as an important mediator in autoimmune ocular inflammatory disease pathogenesis. This treatment is empirical and supported by small case series in the literature due to the relatively low prevalence of ocular manifestations in IBD.

Infliximab, a chimeric monoclonal antibody to TNF- α , and *etanercept*, an anti-TNF- α recombinant fusion protein, have been used in some cases of ocular inflammation in IBD. Retrospective studies show that infliximab seems more effective in the treatment of uveitis. The need for retreatment because of relapses and high cost represent limiting factor for the use of biologics.

In conclusion, a multidisciplinary approach is recommended in the management of patients with IBD, including ocular manifestations. Early diagnosis and effective treatment may avoid the onset of severe and sometimes persisting complications. In some cases, a surgical approach is required to treat eye complications, i.e. cataract, and to improve the patient's quality of life.

References

- 1) IMRIE FR, DICK AD. Biologic in the treatment of uveitis. *Curr Opin Ophthalmol* 2007; 18: 481-486.
- 2) TAYLOR SRJ, MCCLUSKEY P, LIGHTMAN S. The ocular manifestations of inflammatory bowel disease. *Curr Opin Ophthalmol* 2006; 17: 538-555.
- 3) DUKER JS, BROWN GC, BROOKS L. Retinal vasculitis in Crohn's disease. *Am J Ophthalmol* 1987; 103: 664-668.
- 4) HUDSON M, CHITOLIE A, HUTTON RA, SMITH MS, POUNDER RE, WAKEFIELD AJ. Thrombotic vascular risk factors in inflammatory bowel disease. *Gut* 1996; 38: 733-777.
- 5) SALMON JF, WRIGHT JP, MURRAY AD. Ocular inflammation in Crohn's disease. *Ophthalmology* 1991; 98: 480-484.
- 6) GEERARDS AJ, BEEKHUIS WH, REMEYER L, RIJNEVELD AJ, VREUGDENHIL W. Crohn's colitis and the cornea. *Cornea* 1997; 16: 227-231.
- 7) VERBRAAK FD, SCHREINEMACHERS MC, TILLER A, VAN DEVENTER SJ, DE SMET MD. Prevalence of subclinical anterior uveitis in adult patients with inflammatory bowel disease. *Br J Ophthalmol* 2001; 85: 219-221.
- 8) ERNST BB, LOWDER CY, MEISLER DM, GUTMAN FA. Posterior segment manifestations of inflammatory bowel disease. *Ophthalmology* 1991; 98: 1272-1280.
- 9) WEINSTEIN JM, KOCH K, LANE S. Orbital pseudotumor in Crohn's colitis. *Ann Ophthalmol* 1984; 16: 275-278.
- 10) HEUER DK, GAGER WE, REESER FH. Ischemic optic neuropathy associated with Crohn's disease. *J Clin Neuroophthalmol* 1982; 2: 175-181.
- 11) SAMSON CM, WAHEED N, BALTATZIS S, FOSTER CS. Methotrexate therapy for chronic non-infectious uveitis: analysis of a case series of 160 patients. *Ophthalmology* 2001; 108: 1134-1139.
- 12) NUSSENBLATT RB, PALESTINE AG, CHAN CC. Cyclosporine therapy for uveitis: long-term follow-up. *J Ocul Pharmacol* 1985; 1: 369-382.
- 13) KILMARTIN DJ, FORRESTER JV, DICK AD. Tacrolimus (FK506) in failed cyclosporine A therapy in endogenous posterior uveitis. *Ocul Immunol Inflamm* 1998; 6: 101-109.
- 14) HALE S, LIGHTMAN S. Anti-TNF therapies in the management of acute and chronic uveitis. *Cytokine* 2006; 33: 231-237.
- 15) HOFLEY P, ROARTY J, MCGINNITY G, GRIFFITHS AM, MARCON M, KRAFT S, SHERMAN P. Asymptomatic uveitis in children with chronic inflammatory diseases. *J Pediatr Gastroenterol Nutr* 1993; 17: 397-400.