

Posterior cortical atrophy

Sebastian J Crutch, Manja Lehmann, Jonathan M Schott, Gil D Rabinovici, Martin N Rossor, Nick C Fox

Lancet Neurol 2012; 11: 170–78

Dementia Research Centre,
Institute of Neurology,
University College London,
London, UK (S J Crutch PhD,
M Lehmann PhD, J M Schott MD,
M N Rossor FRCP, N C Fox FRCP);
and Memory and Aging Center,
University of California at
San Francisco, San Francisco,
CA, USA (M Lehmann,
G D Rabinovici MD)

Correspondence to:
Dr Sebastian J Crutch, Dementia
Research Centre, Box 16,
National Hospital for Neurology
and Neurosurgery, Queen
Square, London WC1N 3BG, UK
s.crutch@dr.cion.ucl.ac.uk

Posterior cortical atrophy (PCA) is a neurodegenerative syndrome that is characterised by progressive decline in visuospatial, visuo-perceptual, literacy, and praxic skills. The progressive neurodegeneration affecting parietal, occipital, and occipitotemporal cortices that underlies PCA is attributable to Alzheimer's disease in most patients. However, alternative underlying causes, including dementia with Lewy bodies, corticobasal degeneration, and prion disease, have also been identified, and not all patients with PCA have atrophy on clinical imaging. This heterogeneity has led to inconsistencies in diagnosis and terminology and difficulties in comparing studies from different centres, and has restricted the generalisability of findings from clinical trials and investigations of factors that drive phenotypic variability. Important challenges remain, including the identification of factors associated not only with the selective vulnerability of posterior cortical regions but also with the young age of onset of PCA. Greater awareness of the syndrome and agreement over the correspondence between syndrome-level and disease-level classifications are needed to improve diagnostic accuracy, clinical management, and the design of research studies.

Introduction

Posterior cortical atrophy (PCA) is a neurodegenerative condition characterised by a progressive, often striking, and fairly selective decline in visual-processing skills and other functions that depend on parietal, occipital, and occipitotemporal regions of the brain. Age at onset of PCA is typically 50–65 years, and the syndrome is associated with various underlying pathological features. PCA has been recognised for more than two decades and yet, compared with other conditions, is relatively neglected by researchers. Patients often face considerable delays in diagnosis owing to the young age at onset and unusual symptoms at presentation. Furthermore, the term PCA has been applied inconsistently, making comparison across studies difficult to achieve. Although there have been moves to define neurodegenerative diseases by their underlying pathological features, such progress in relation to PCA is limited currently by scant specificity in available diagnostic criteria and an absence of clarity with respect to relations between PCA and related syndromic classifications, such as aphasic, amnesic, and dysexecutive Alzheimer's disease phenotypes and corticobasal syndrome.

In this Review we outline the clinical, psychological, imaging, epidemiological, genetic, and pathological features of PCA. We argue that, within pathological subgroups, characterisation of atypical phenotypes such as PCA will enable identification of biological factors that promote or protect against pathological changes in specific brain networks. Problems with and possible solutions to current diagnostic and terminological conundrums are considered, with particular reference to implications for future design of clinical and research trials that include people with PCA. We also aim to increase awareness and improve identification of early and unusual symptoms of PCA and to provide guidance on the provision of support, care, and education for patients, carers, and health-care professionals.

History and definitions

The term PCA was first used to describe people with predominant deficits in higher-order visual processing, a subset of whom also presented with striking atrophy in parieto-occipital areas of the brain.¹ The outlined syndrome accorded with other early reports of patients with similar clinical characteristics.^{2–9} Without histopathological data, Benson and colleagues¹ deemed the clinical presentation of PCA to be sufficiently distinct from that of Alzheimer's or Pick's disease “to warrant classing them separately until definitive pathologic information becomes available”. Subsequent histopathological studies identified Alzheimer's disease as the most common underlying pathological feature, leading to synonymous use of the terms PCA, biparietal Alzheimer's disease, and visual variant of Alzheimer's disease in some studies.^{10–14} The term progressive posterior cortical dysfunction has also been used to describe clinical symptoms in affected individuals who do not have clear posterior atrophy.¹⁵ However, PCA is also associated with pathological features that are not linked to Alzheimer's disease, which has led to calls for PCA to be regarded as a distinct nosological entity with its own diagnostic criteria.^{16,17}

Epidemiology

The prevalence and incidence of PCA are currently unknown; obtaining these data will depend on the adoption of consistent diagnostic criteria. Furthermore, any value is likely to be an underestimate because of poor general awareness of the syndrome. However, Snowden and colleagues¹⁸ noted that, of 523 patients with Alzheimer's disease presenting to one specialist centre for cognitive disorders, 24 (5%) had a visual presentation (also labelled PCA) and a further 13 (3%) had an apraxic presentation.

Age at onset tends to be much earlier in patients with PCA than in those with typical amnesic Alzheimer's disease, with most studies recording age of PCA symptom onset from mid-50s to early 60s,^{17,19} although some

researchers have reported a wider age spread (45–74 years,²⁰ 40–86 years).²¹ In terms of sex distribution, no difference in prevalence has been noted on the basis of sex,^{15,17,19} whereas other groups have reported an over-representation in women.^{18,20–24}

Neuropsychological features

The neuropsychological deficits cited most frequently in individuals with PCA are visuospatial and visuo-perceptual impairments, alexia, and features of Bálint's syndrome (simultanagnosia, oculomotor apraxia, optic ataxia, environmental agnosia) and Gerstmann's syndrome (acalculia, agraphia, finger agnosia, left–right disorientation; figure 1).^{15,17,19–21,25–31} Deficits in working memory and limb apraxia have also been noted.²⁰ Findings of longitudinal studies indicate that anterograde memory, executive functions, and linguistic skills, which are sometimes preserved strikingly in earlier stages of disease, gradually deteriorate in some patients with PCA as they progress to a more global dementia state.^{10,19,23}

Although higher-order visual problems, such as difficulties with object and space perception, are reported more often than are basic visual impairments, many such problems are at least partly due to deficits in more basic visual processing—eg, form, motion, colour, and point localisation. In a detailed comparison of basic and higher-order perception,³² all patients with PCA showed impairment in at least one basic visual process, emphasising the vulnerability of fundamental aspects of vision associated with occipital cortical dysfunction. This study also indicated specific correlations of basic visual processing with higher-order visuospatial and visuo-perceptual skills, but not with non-visual parietal functions (such as calculation and spelling), suggesting specific involvement of visual networks in PCA.³²

Basic and higher-order visual deficits, in combination, have predictable outcomes on the performance of PCA patients on general neuropsychological tests—eg, performance IQ in patients is often up to 30–40 points lower than verbal IQ. Performance on cognitive tasks with any relevant visual component (eg, visual memory recall, trail-making test, Stroop test) is vulnerable to impairment and misinterpretation, and thus accurate assessment requires selection of tasks that minimise visual demands (eg, auditory-verbal memory tasks, naming from verbal description).

Many patients with PCA also have unusual symptoms, referred to as positive perceptual phenomena, which include abnormally prolonged colour after-images,³³ reverse size phenomena,^{34,35} perception of movement of static stimuli,³⁵ and in one individual,³⁵ 180° upside-down reversal of vision. Reading skills can be limited by several processes, including visual disorientation (getting lost on the page), reverse size phenomena (accurately perceiving small but not large print), and visual crowding (impaired identification of constituent letters of a word owing to excessive integration of visual features from surrounding

letters).^{36–38} PCA can also lead to primary peripheral dyslexias.^{39,40} Anecdotally, individuals with PCA frequently report heightened sensitivity to glare from shiny surfaces and can experience a range of localised sensation and pain phenomena and disturbances of balance and bodily orientation, which could potentially be linked to deranged visuovestibular interactions.

Should PCA be deemed a unitary clinicoanatomical syndrome or, rather, a collection of related but distinct syndromic subtypes? By extrapolation from basic neuroscientific evidence of distinct cortical streams that process different types of visual information,^{41,42} researchers have suggested that separate parietal (dorsal), occipitotemporal (ventral), and primary visual (striate cortex, caudal) forms of PCA exist.^{12,13} However, these claims are based on findings from individual case reports. Subsequent studies of neuropsychological case series have failed to provide evidence to support a pure ventral-stream syndrome¹⁹ and, rather, have indicated considerable overlap in neuropsychological profiles and patterns of cortical thinning in patients with behaviourally defined predominantly dorsal-stream or ventral-stream



Figure 1: Visual dysfunction in posterior cortical atrophy

Individuals with posterior cortical atrophy have difficulty identifying objects and faces, particularly when they consist of many parts or are viewed from an unfamiliar (non-canonical) perspective. Eye-tracking studies contrasting scene perception in healthy individuals (A) and people with posterior cortical atrophy (B) suggest that patients have poor top-down guidance and control of oculomotor function. Circles represent fixation locations and circle size represents fixation duration. Patients with posterior cortical atrophy fixate prominent features initially (eg, dome on pier), but subsequently fixate relatively uninformative aspects of the scene (eg, sea or sky) and miss important contextual details (eg, beachfront or near the end of the pier). Images from Tim Shakespeare and Sebastian Crutch (unpublished).

Panel: Case study

A 62-year-old right-handed woman presented with 4 years of progressive visuospatial dysfunction. Her first symptom was difficulty seeing when driving at night. In the following years she frequently dented her car when parking, tended to bump into doors on her right side, and had trouble locating items even when they were directly in front of her. She reported problems reading, trouble distinguishing between currency bank notes, and difficulty deciding whether to push or pull a door to open it. When she watched television, images seemed to move slowly. She was referred to the cognitive neurology clinic by an ophthalmologist, who had ruled out primary ocular disease. On neurological assessment she was fully oriented and was an excellent historian. On testing of visual fields, she was inconsistent in counting fingers in the right hemifield. Pupillary responses and extraocular movements were normal, although she was slow initiating saccades and had difficulty reaching for items under visual guidance. Her physical neurological examination was otherwise normal. On cognitive testing, her MMSE score was 26/30, and she showed severe impairment when copying intersecting pentagons and the Benson figure (figure 2A). She was able to name colours correctly but showed moderate difficulty matching faces. She had severe difficulty reading, which was improved by spelling words out loud, and had mild deficits in confrontation naming (improved with cues) and category fluency. Verbal memory, phonemic fluency, and attention were intact. She could not complete many tasks because of visual dysfunction. Brain MRI showed striking atrophy in bilateral parietal, posterior temporal, and lateral occipital cortex (figure 2B [upper row]), and fluorodeoxyglucose (FDG)-PET (figure 2B [middle row]) showed hypometabolism in the same regions, left worse than right. Frontal cortex, medial temporal cortex, and hippocampus were spared. Pittsburgh compound (PIB)-PET showed diffuse cortical uptake throughout posterior and anterior cortical regions alike (figure 2B [lower row]), consistent with underlying amyloid- β plaques.

impairments.³² Thus, these findings suggest that phenotypic differences might most appropriately be judged to represent points on a continuum of variation within PCA.

Clinical features

Clinical presentation of PCA is affected by several factors. These include time taken before an individual presents to medical services or is referred to a cognitive specialist; the specific pattern of deficits; in some people, the underlying pathological features; and the patient's psychological response to their symptoms. The relative rarity of PCA, the sometimes unusual nature of its symptoms, and the fairly young age at onset can lead to misdiagnosis of many patients as depressed, anxious, or even malingering in early stages of the disease. Early anxiety is (at least anecdotally) a common feature, perhaps indicating that patients with PCA typically have some insight into the possibility that they have a medical problem, even if its nature is unclear. Furthermore, even to experienced cognitive neurologists, a patient's initial history can be more suggestive of anxiety, until examination shows impairment that relates to function of the parietal lobe, the occipital lobe, or both of these areas. Patients are usually referred first to opticians and ophthalmologists in the belief that an ocular abnormality is causing their visual symptoms, sometimes leading to unnecessary medical procedures such as cataract surgery.

The symptoms reported by a patient with PCA probably indicate broadly their individual pattern of neuropsychological impairment. Visual symptoms are perhaps more likely to be mentioned than other posterior deficits, with individuals describing difficulties reading lines of text, judging distances (often leading to repeat minor car accidents or difficulties parking), identifying static objects within the visual field, or having problems with stairs and escalators (panel). Visual symptoms such as light sensitivity or visual distortions can be mistaken for migraine. Careful history taking could reveal some of the more unusual visual phenomena described above, including the presence of prolonged after-images or visual crowding. Individuals might volunteer difficulties in using common objects, suggesting dyspraxia, or describe progressive difficulty with calculations or spelling. The presence of other neurological symptoms, including visual hallucinations (reported in up to 25% of patients with PCA)^{19,21,43} and rapid eye movement (REM) sleep behaviour disorder, could be suggestive of underlying dementia with Lewy bodies. Very occasionally, the patient's history might be consistent with occipital lobe seizures.

Careful bedside testing can elicit signs of disproportionate parietal or occipital dysfunction, including (but not restricted to) visual disorientation, difficulties resolving degraded stimuli, ideational or ideomotor dyspraxia (or both), dyscalculia, and problems with spelling (figure 2A). The physical examination in most cases of PCA is unremarkable; however, if severe cortical visual impairments are present, interpretation of visual acuity and visual fields can be difficult, with hemianopia sometimes misdiagnosed owing to the presence of higher-order visual attentional impairments. Finger myoclonus is also not uncommon. Snowden and colleagues¹⁸ reported similar frequencies of extrapyramidal signs (41%), myoclonus (24%), and grasp reflex (26%) in individuals with PCA compared with those seen in patients with typical Alzheimer's disease. Nonetheless, features of clear symmetrical motor parkinsonism (suggestive of Lewy body pathology) or prominent asymmetric myoclonus and dystonia (suggestive of corticobasal degeneration) can give important clues to the underlying cause of PCA, although pathological data on which these clinical observations can be confirmed are currently sparse.

Neuroimaging

Increasingly advanced image analysis techniques have been used to localise and quantify (typically group) differences in patterns of atrophy in patients with PCA, compared either with controls or with patients with typical Alzheimer's disease. Cross-sectional voxel-based morphometry has shown widespread differences in grey matter between patients with PCA and healthy controls, with the most significant reductions found in regions of the occipital and parietal lobes followed by areas in the

temporal lobe.^{24,30} Direct comparison between individuals with PCA and typical Alzheimer's disease, using both voxel-based morphometry and cortical thickness measures, has shown greater right parietal and less left medial temporal and hippocampal atrophy in patients with PCA. It is noteworthy that in several studies, researchers report asymmetric atrophy patterns in PCA (right greater than left), but these differences could be due to selection biases in the diagnosis and recruitment of patients with prominent visual dysfunction. Limited data from diffusion tensor imaging studies also suggest that PCA reduces the integrity of white matter tracts in posterior brain regions.⁴⁴⁻⁴⁶ However, considerable regional overlap in atrophy has also been reported, with regions including the posterior cingulate gyri, precuneus, and inferior parietal lobe being affected in both PCA and typical Alzheimer's disease.²³ Such findings suggest that PCA, when associated with Alzheimer's disease, exists on a spectrum of variation with other phenotypes of Alzheimer's disease.^{23,32} Fluid registration of longitudinally acquired structural magnetic resonance (MR) images shows the evolution of PCA (figure 3), with findings of group studies indicating that, by 5 years of symptom duration, atrophy is widespread throughout the cortex, including medial temporal lobe structures.³¹

Data from functional imaging studies using single photon emission computed tomography (SPECT) and fluorodeoxyglucose (FDG) PET accord largely with structural changes in parieto-occipital areas (figure 2B).^{20,47-51} In addition to posterior regions, FDG-PET has indicated specific areas of hypometabolism in the frontal eye fields bilaterally, which can occur secondary to loss of input from occipitoparietal regions and be the cause of oculomotor apraxia in PCA (figure 1).^{20,52} In a few studies, researchers have also assessed patterns of amyloid deposition with Pittsburgh compound B (PiB)-PET in patients with PCA. Case studies and small series have shown increased accumulation of amyloid- β , predominantly in the occipital and parietal lobes, relative to individuals with typical Alzheimer's disease.⁵³⁻⁵⁶ However, in two studies in which PiB uptake was compared in large groups of patients with PCA and typical Alzheimer's disease, no significant difference was reported in amyloid deposition between these groups, with both showing diffuse PiB uptake throughout frontal, temporoparietal, and occipital cortex (figure 2B).^{22,57}

Genetics

To date, no reports have been published of a PCA phenotype associated with autosomal dominant familial Alzheimer's disease; however, in a case series,⁵⁸ the PCA syndrome was described in familial prion disease associated with a 5-octapeptide insertion into the prion protein. Findings from available PCA case series suggest that there is no significant difference in the number of patients with a positive family history of

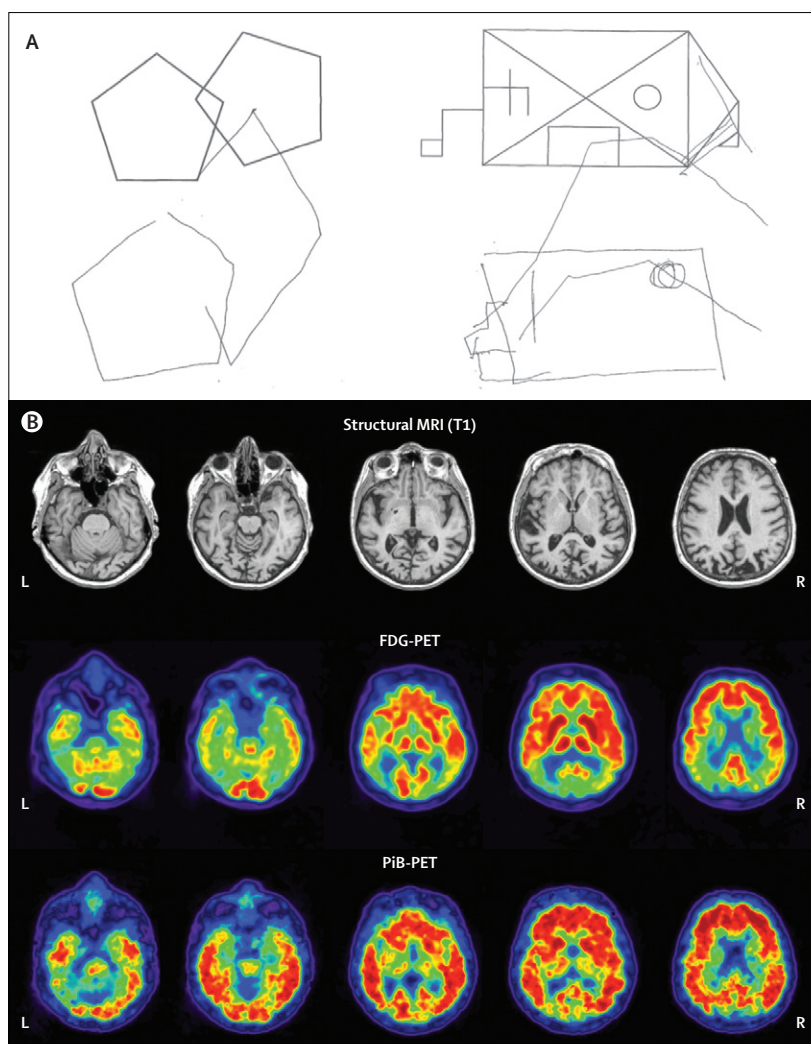


Figure 2: Neuropsychological and neuroimaging evidence of posterior cortical atrophy
Neurological testing (A) and brain imaging (B) of a 62-year-old woman with visuospatial dysfunction. Images are in neurological orientation. See the panel for a description of the case history and imaging findings.

dementia in PCA and with typical Alzheimer's disease.^{17,21} In some studies, significant differences between apolipoprotein E (APOE) genotypes have been noted in patients with PCA versus amnesic Alzheimer's disease.^{14,18,59} However, in other studies, no difference in APOE was recorded between PCA and typical Alzheimer's disease (table).^{17,21-23,60-64} Discrepancies between these studies could be attributable to differences in the inclusion criteria used to define PCA and typical Alzheimer's disease and age at onset. In particular, scant pathological confirmation is a major limitation of these studies.

Does the APOE $\epsilon 4$ allele drive the degenerative pattern in patients with Alzheimer's disease (ie, to or away from medial temporal structures)? Is the low frequency of APOE $\epsilon 4$ in PCA that is reported in some studies attributable to patients with non-Alzheimer's disease

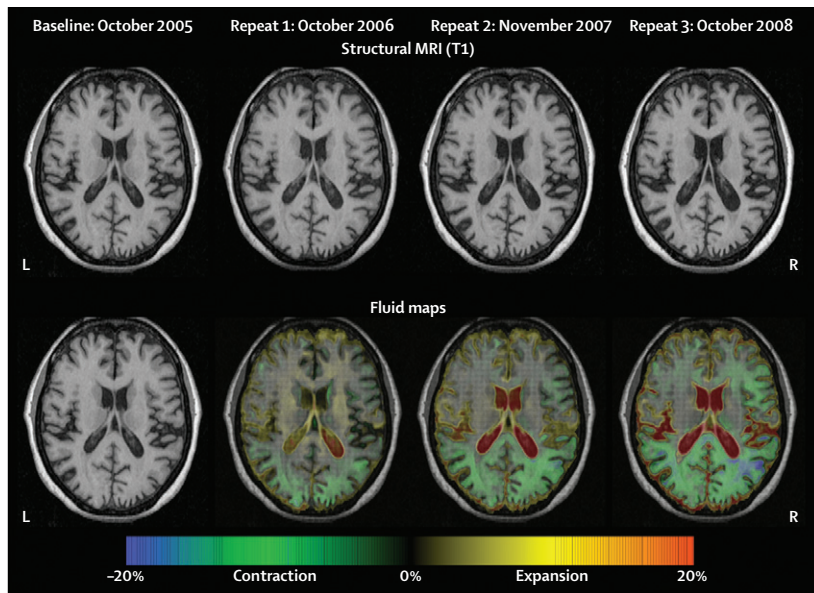


Figure 3: Evolution of neurodegeneration in posterior cortical atrophy
Registered serial MRIs showing axial views of a woman with posterior cortical atrophy at four timepoints (age 59–63 years old). Repeat scans were fluid-registered to the baseline image and colour-coded voxel-compression maps were produced. The scale shows the percentage volume change per voxel (–20 to 20%), with green and blue representing contraction and yellow and red representing expansion.

pathology? Do different (as yet unrecognised) genetic factors underlie PCA compared with so-called typical late-onset Alzheimer's disease? Studies with large sample sizes, consistent definitions of PCA, and post-mortem confirmation of diagnosis are needed to obtain conclusive results. Genome-wide association studies to assess frequencies of other genetic risk factors for sporadic Alzheimer's disease will be useful.

Pathology

Findings of pathological studies all show that Alzheimer's disease is the most common underlying cause of PCA.^{13,15,21,65–67} However, some cases are attributable to other causes, such as corticobasal degeneration,^{15,68,69} dementia with Lewy bodies,^{15,70} prion disease (including CJD and familial fatal insomnia),^{15,71} and subcortical gliosis.⁷¹ In the largest series studied to date, Renner and colleagues¹⁵ reported pathological data for 21 patients with PCA, of whom 13 had Alzheimer's disease, two had pathological features of an Alzheimer's disease-Lewy body variant, one had Alzheimer's disease with coexisting Parkinson's disease, one had dementia with Lewy bodies with coexisting subcortical gliosis, two had corticobasal degeneration, and two had prion disease (CJD and fatal familial insomnia). Tang-Wai and colleagues²¹ reported that seven of nine patients with PCA had pathological features of Alzheimer's disease, whereas the other two had corticobasal degeneration.²¹

Although the distribution patterns of pathological features differ between PCA and typical Alzheimer's disease, the exact pattern of pathological changes is

inconsistent and based on very few cases. Some studies have shown differences in both plaques and neurofibrillary tangles between PCA and typical Alzheimer's disease,^{10,12,72} whereas others have recorded no differences in plaque distribution.^{15,21} For example, Levine and colleagues¹⁰ reported pathological findings of one patient with PCA who showed the greatest density of senile plaques and neurofibrillary tangles in occipitoparietal regions and the lowest density in frontal lobe regions. Hof and co-workers^{72,73} reported similar findings, with plaques and tangles found predominantly in primary visual and visual association areas around the occipitoparietotemporal junction, whereas frontal regions—such as the prefrontal cortex—had very low densities of pathological changes. By contrast, Tang-Wai and colleagues²¹ looked at pathological changes in nine patients with PCA versus 30 with typical Alzheimer's disease. The PCA group showed significantly higher densities of neurofibrillary tangles in visual and visual-association cortices and fewer tangles and senile plaques in the hippocampus and subiculum. However, density of senile plaques in other cortical areas was comparable in both groups.²¹ Reasons for the discrepant findings in these autopsy studies could include differences in inclusion criteria and demographic characteristics (such as age and disease severity) and differences in the methods used to quantify pathological changes (such as different staining techniques and discrimination between diffuse and neuritic plaques). Studies in which CSF biomarkers ($A\beta_{1-42}$, T-tau, and P-tau_{181}}) were assessed have recorded similar findings in patients with PCA compared with Alzheimer's disease,^{27,56,60,74} lending support to previous reports that PCA is associated typically with underlying Alzheimer's disease pathology.

Diagnostic and research criteria

Two sets of diagnostic criteria for PCA have been proposed.^{17,21} Suggested core features for a diagnosis of PCA include insidious onset and gradual progression; presentation of visual deficits in the absence of ocular disease; relatively preserved episodic memory, verbal fluency, and personal insight; presence of symptoms including visual agnosia, simultanagnosia, optic ataxia, ocular apraxia, dyspraxia and environmental disorientation; and absence of stroke or tumour. Supportive features include alexia, ideomotor apraxia, agraphia, acalculia, onset before the age of 65 years, and neuroimaging evidence of PCA or hypoperfusion.

Although these criteria have proved useful in several clinical and research contexts, they are based on clinical experience at single centres and have not been validated more widely. Without objective evidence linking clinical phenotype to underlying pathology, there continues to be inconsistency, with the term PCA being used as a descriptive syndromic term and as a diagnostic label. Such inconsistencies present several difficulties in

	Posterior cortical atrophy					Alzheimer's disease					Controls		
	Total (n)	Age at onset (years)*	APOE (n)	ε4 frequency (%)	ε4-positive (%)	Total (n)	Age at onset (years)*	APOE (n)	ε4 frequency (%)	ε4-positive (%)	Total (n)	ε4 frequency (%)	ε4-positive (%)
Mendez (2002) ³⁷	15	58.2 (5.1)	8	25	50	176†	..	176	40
Tang-Wai (2004) ²¹	40	60.5 (8.9)	27	26	48	5107‡	..	5107	37	59	6262‡	14	26
Schott (2006) ^{34,§}	10	56.1 (4.1)	10	10	20	29	65.6 (6.9)	29	52	86
Snowden (2007) ^{18,§}	24	58.0 (4.0)	30	321	58.0 (4.0)	82¶	767	14	27
Migliaccio (2009) ²³	14	..	11	..	55	16	..	9	..	56	44	..	23
Baumann (2010) ⁶⁰	9	56.7 (7.6)	9	..	39	11	58.3 (5.1)	11	..	50	14	..	14
Rosenbloom (2011) ²²	12	57.5 (7.4)	9	33	44	14	58.8 (9.6)	11	59	73

Data are from seven studies that have reported APOE ε4 frequency in posterior cortical atrophy, typical (or sporadic) Alzheimer's disease, and healthy controls. *For whole groups of patients with posterior cortical atrophy and Alzheimer's disease, the age at onset for the subsample of patients with APOE ε4 was unknown, except for Schott³⁴ and Baumann.⁶⁰ †Saunders (1993).⁶¹ ‡Farrer (1997).⁶² §Reported significant difference in APOE ε4 between patients with posterior cortical atrophy and Alzheimer's disease. ¶Amnesic Alzheimer's disease; 80% were ε4-positive in the memory and semantic Alzheimer's disease group. ||Pendleton (2002).⁶⁴

Table: Prevalence of the APOE ε4 allele in posterior cortical atrophy and Alzheimer's disease

attributing and assessing the validity of a diagnosis of PCA and, particularly, in the design and interpretation of research studies and clinical trials. First, although a syndromic classification could be adequate for some types of research study (eg, brain-behaviour, behavioural intervention), other investigations will need direct consideration of probable underlying pathological features (eg, clinical trials of disease-specific drugs). Second, at present, we have no evidence base on which to judge the effectiveness of pharmacological treatments for Alzheimer's disease in individuals with PCA attributable to probable Alzheimer's disease or to decide whether individuals with PCA should be included or excluded from conventional clinical trials of Alzheimer's disease—eg, because of the potential unsuitability of study outcome measures (eg, visual memory tasks) selected for patients with more typical amnesic or global clinical presentations. Third, current criteria provide no guidance about the degree of specificity needed for a diagnosis of PCA. For example, in the relatively large series reported by Renner and colleagues,¹⁵ nine of 27 patients presented with PCA as a fairly isolated disorder, whereas in the remaining 18 people it was the prominent feature of a more generalised dementia. Several groups have suggested that PCA, when attributable to probable Alzheimer's disease, lies on a phenotypic continuum with other typical and atypical Alzheimer's phenotypes (eg, amnesic Alzheimer's disease, global cognitive impairment, logopenic or phonological aphasia),^{18,23,32} but the boundaries between such phenotypes are defined imprecisely. Fourth, the presentation of visual complaints is a core feature of existing criteria but some patients with neurodegenerative disorders present with predominant impairment of other posterior cortical functions, such as calculation, spelling, and praxis,^{6,18,27,48,75} such individuals could be deemed to fall within the PCA spectrum. Finally, the value of biomarkers might differ in PCA compared with typical

Alzheimer's disease or dementia with Lewy bodies (eg, relative absence of hippocampal atrophy). This issue is especially important in view of the increasing incorporation of such biomarkers in disease-specific diagnostic criteria.^{76,77}

Future resolution of these issues and development of clinical and research criteria for the definition of PCA are likely to be based on a consensus of opinion from many specialist centres, supported by objective evidence of the relation between clinical presentation, neuroimaging and CSF biomarkers, and histopathological data. Establishment of the relative likelihood of different pathologies in large, multicentre datasets would improve the discrimination of potential disease subtypes necessary for trials of disease-modifying agents. One possible approach would be to apply a range of criteria to a multicentre dataset to establish sets of inclusion and exclusion criteria that identify specific disease subgroups (eg, PCA with Alzheimer's disease). By consensus, experts could also investigate frameworks for making criteria useable, in terms of a quantifiable set of diagnostic markers, to help with enrolment into research studies and to improve the comparability of data between institutions.

Management

As far as we know, no reports have been published that assess the effectiveness of acetylcholinesterase inhibitors (eg, donepezil, rivastigmine, and galantamine) in PCA. However, these drugs are frequently and, in our view (since Alzheimer's disease is the most likely underlying pathology), appropriately administered. Clinical experience and a few case reports suggest some clinical benefit,⁷⁸ most probably in patients with underlying pathological features of Alzheimer's disease or dementia with Lewy bodies. Antidepressant drugs might also be appropriate in patients with persistent low mood, and trials of levodopa or carbidopa could be useful in individuals with parkinsonism.

Because of poor awareness of PCA, patients with this disorder typically receive scant or inappropriate care and advice, whereby difficulties that are less important to the individual (eg, memory problems) are targeted while vital perceptual difficulties (eg, many activities in day centres and nursing homes are visually mediated) are, in general, not considered. Preservation of skills such as memory, language, and insight in PCA, especially in mild-to-moderate stages of the disease, enables patients to take advantage of peer-support meetings and group, couple, and individual psychological treatments when the need exists. Support group meetings are especially useful in tackling social isolation, allowing patients to share the experience of what is often a long and difficult route to diagnosis, and to exchange practical tips and coping strategies and advice. Patients with PCA often benefit from resources designed primarily for blind and partially sighted people, such as mobile phones with simplified displays, voice recognition software, talking books and watches, culinary aids, and lamps to increase ambient light levels in the home. Referral to an occupational therapist or sensory team could be appropriate to help a patient participate more fully in activities of daily living. An individual might also need to be referred to an ophthalmologist to register as partially sighted under statutory invalidity schemes, which might then provide access to financial and social benefits and services. Driving a car is not appropriate for many people with PCA, particularly those with prominent visual disturbance. Physical therapy can also be helpful for individuals with parkinsonism and gait disturbance. Scant empirical evidence shows the effect of management strategies in PCA, but a rehabilitation programme that included psychoeducation, compensatory strategies, and cognitive exercises was tested in an individual with PCA,⁷⁹ resulting in small improvements in visuoperceptual functioning.

Conclusions

Posterior cortical atrophy is a debilitating and under-recognised focal degenerative syndrome that is associated with a range of different disease pathologies. The core features of the syndrome are sufficiently homogeneous to justify regarding PCA as an independent nosology, with Alzheimer's disease as the most common underlying cause. However a lack of consistency in the classification of PCA is likely to continue unless diagnostic criteria and terminology are standardised. The criteria proposed in this Review attempt to take both the clinical and histopathological features of PCA into account and to introduce quantifiable behavioural inclusion criteria for research studies of PCA. Better understanding and awareness of the syndrome by medical and lay workers is necessary to improve diagnosis and treatment and to enhance support services for individuals with PCA and their families. Identification of the distinctive patterns of structural, functional, cognitive, and genetic changes in PCA could provide

Search strategy and selection criteria

We identified references for this Review by searching PubMed with the terms: "posterior cortical atrophy", "biparietal Alzheimer's disease", "visual dementia", and "Balint's syndrome dementia". We looked for articles published between 1970 and November, 2011. We also identified articles by searching our own files. Only reports published in English were reviewed, with the exception of historical manuscripts (before 1988). The final reference list was generated on the basis of originality and relevance to the broad scope of this Review.

new insights into the pathogenesis and clinical features of typical Alzheimer's disease and into general mechanisms of visual network function and degeneration. Dedicated trials are needed to assess the effectiveness of pharmacological and non-pharmacological interventions in PCA, and to identify factors that drive phenotypic variability in this small but important population of patients who typically have early-onset dementia.

Contributors

All authors contributed to the writing and reviewing of this Review.

Conflicts of interest

NCF has served on scientific advisory boards of the Alzheimer's Research Forum, the Alzheimer's Society, and the Alzheimer's Research Trust, and holds a patent for QA Box that might accrue revenue. In the past 5 years his research group has received payment for consultancy or for undertaking studies from Abbott Laboratories, Elan Pharmaceuticals, Eisai, Eli Lilly, GE Healthcare, IXICO, Lundbeck, Pfizer, Sanofi-Aventis, and Wyeth Pharmaceuticals. JMS has received payment for undertaking studies from AVID Radiopharmaceuticals. SJC, ML, GDR, and MNR declare that they have no conflicts of interest.

Acknowledgments

This work was undertaken at University College London Hospital (UCLH) and UCL, which received a proportion of funding from the Department of Health's National Institute for Health Research (NIHR) Biomedical Research Centres funding scheme. The Dementia Research Centre is an Alzheimer's Research UK coordinating centre and has received equipment funded by Alzheimer's Research UK. SC is supported by an Alzheimer's Research UK senior research fellowship and equipment grant. ML is supported by the Alzheimer's Society. JMS is a UK Higher Education Funding Council for England (HEFCE) clinical senior lecturer and receives grant support from Alzheimer's Research UK. GDR receives research support from the US National Institutes of Health [NIA K23-AG031861 (PI)], the Alzheimer's Association, and the John Douglas French Alzheimer's Foundation. NCF is supported by a Medical Research Council (UK) senior clinical fellowship. MNR and NCF hold NIHR senior investigator awards.

References

- 1 Benson F, Davis J, Snyder BD. Posterior cortical atrophy. *Arch Neurol* 1988; **45**: 789–93.
- 2 Crystal HA, Horoupian DS, Katzman R, Jotkowitz S. Biopsy-proved Alzheimer's disease presenting as a right parietal lobe syndrome. *Ann Neurol* 1982; **12**: 186–87.
- 3 Faden MAI. Myoclonus and Alzheimer's disease: reply. *Arch Neurol* 1976; **33**: 730.
- 4 Grunthal E. Zur hirnpathologischen analyse der Alzheimerschen krankheit. *Psychiatr Neurol Wochenschr* 1928; **36**: 401–07.
- 5 Cogan DG. Visual disturbances with focal progressive dementing disease. *Am J Ophthalmol* 1985; **100**: 68–72.
- 6 De Renzi E. Slowly progressive visual agnosia or apraxia without dementia. *Cortex* 1986; **22**: 171–80.

- 7 Critchley M. The parietal lobes. New York: Hafner, 1953.
- 8 Pick A. Über eine eigenthümliche sehstörung seniler dementer. *Jahrbücher Psychiatrie Neurologie* 1902; 22: 35–44.
- 9 Morel F. Les aires striées, parastriées et peristriées dans les troubles de la fonction visuelle au cours de la maladie d'Alzheimer. *Confin Neurol* 1945; 6: 238–42.
- 10 Levine DN, Lee JM, Fisher CM. The visual variant of Alzheimer's disease: a clinicopathologic case study. *Neurology* 1993; 43: 305–13.
- 11 Bokde ALW, Pietrini P, Ibanez V, et al. The effect of brain atrophy on cerebral hypometabolism in the visual variant of Alzheimer disease. *Arch Neurol* 2001; 58: 480–86.
- 12 Ross SJ, Graham N, Stuart-Green L, et al. Progressive biparietal atrophy: an atypical presentation of Alzheimer's disease. *J Neurol Neurosurg Psychiatry* 1996; 61: 888–95.
- 13 Galton CJ, Patterson K, Xuereb JH, Hodges JR. Atypical and typical presentations of Alzheimer's disease: a clinical, neuropsychological, neuroimaging and pathological study of 13 cases. *Brain* 2000; 123: 484–98.
- 14 Schott JM, Ridha BH, Crutch SJ, et al. Apolipoprotein E genotype modifies the phenotype of Alzheimer disease. *Arch Neurol* 2006; 63: 155–56.
- 15 Renner JA, Burns JM, Hou CE, McKeel DW Jr, Storandt M, Morris JC. Progressive posterior cortical dysfunction: a clinicopathologic series. *Neurology* 2004; 63: 1175–80.
- 16 Tang-Wai D, Mapstone M. What are we seeing? Is posterior cortical atrophy just Alzheimer disease? *Neurology* 2006; 66: 300–01.
- 17 Mendez MF, Ghajaramia M, Perryman KM. Posterior cortical atrophy: clinical characteristics and differences compared to Alzheimer's disease. *Dement Geriatr Cogn Disord* 2002; 14: 33–40.
- 18 Snowden JS, Stopford CL, Julien CL, et al. Cognitive phenotypes in Alzheimer's disease and genetic risk. *Cortex* 2007; 43: 835–45.
- 19 McMonagle P, Deering F, Berliner Y, Kertesz A. The cognitive profile of posterior cortical atrophy. *Neurology* 2006; 66: 331–38.
- 20 Kas A, de Souza LC, Samri D, et al. Neural correlates of cognitive impairment in posterior cortical atrophy. *Brain* 2011; 134: 1464–78.
- 21 Tang-Wai DF, Graff-Radford NR, Boeve BF, et al. Clinical, genetic, and neuropathologic characteristics of posterior cortical atrophy. *Neurology* 2004; 63: 1168–74.
- 22 Rosenbloom MH, Alkalay A, Agarwal N, et al. Distinct clinical and metabolic deficits in PCA and AD are not related to amyloid distribution. *Neurology* 2011; 76: 1789–96.
- 23 Migliaccio R, Agosta F, Rascofsky K, et al. Clinical syndromes associated with posterior atrophy early age at onset AD spectrum. *Neurology* 2009; 73: 1571–78.
- 24 Lehmann M, Crutch SJ, Ridgway GR, et al. Cortical thickness and voxel-based morphometry in posterior cortical atrophy and typical Alzheimer's disease. *Neurobiol Aging* 2011; 32: 1466–76.
- 25 Charles RF, Hillis AE. Posterior cortical atrophy: clinical presentation and cognitive deficits compared to Alzheimer's disease. *Behav Neurol* 2005; 16: 15–23.
- 26 Silveri MC, Ciccarelli N, Cappa A. Unilateral spatial neglect in degenerative brain pathology. *Neuropsychology* 2011; 25: 554–66.
- 27 Seguin J, Formaglio M, Perret-Liaudet A, et al. CSF biomarkers in posterior cortical atrophy. *Neurology* 2011; 76: 1782–88.
- 28 Gafoor VA, Jose J, Saifudheen K, Musthafa M. Posterior cortical atrophy: a rare visual variant of Alzheimer's disease. *Neurol India* 2011; 59: 297–99.
- 29 Andrade K, Samri D, Sarazin M, et al. Visual neglect in posterior cortical atrophy. *BMC Neurol* 2010; 10: 68.
- 30 Whitwell JL, Jack CR, Kantarci K, et al. Imaging correlates of posterior cortical atrophy. *Neurobiol Aging* 2007; 28: 1051–61.
- 31 Lehmann M, Barnes J, Ridgway GR, et al. Global grey matter changes in posterior cortical atrophy: a serial imaging study. *Alzheimers Dement* (in press).
- 32 Lehmann M, Barnes J, Ridgway GR, et al. Basic visual function and cortical thickness patterns in posterior cortical atrophy. *Cerebral Cortex* 2011; 21: 2122–32.
- 33 Chan D, Crutch SJ, Warrington EK. A disorder of colour perception associated with abnormal colour after-images: a defect of the primary visual cortex. *J Neurol Neurosurg Psychiatry* 2001; 71: 515–17.
- 34 Stark ME, Grafman J, Fertig E. A restricted 'spotlight' of attention in visual object recognition. *Neuropsychologia* 1997; 35: 1233–49.
- 35 Crutch SJ, Lehmann M, Gorgoraptis N, et al. Abnormal visual phenomena in posterior cortical atrophy. *Neurocase* 2011; 17: 160–77.
- 36 Price CJ, Humphreys GW. Contrasting effects of letter-spacing in alexia: further evidence that different strategies generate word length effects in reading. *Q J Exp Psychol A* 1995; 48: 573–97.
- 37 Crutch SJ, Warrington EK. Foveal crowding in posterior cortical atrophy: a specific early-visual-processing deficit affecting word reading. *Cogn Neuropsychol* 2007; 24: 843–66.
- 38 Crutch SJ, Warrington EK. The relationship between visual crowding and letter confusability: towards an understanding of dyslexia in posterior cortical atrophy. *Cogn Neuropsychol* 2009; 26: 471–98.
- 39 Crutch SJ, Warrington EK. Word form access dyslexia: understanding the basis of visual reading errors. *Q J Exp Psychol (Hove)* 2007; 60: 57–78.
- 40 Catricala E, Della Rosa PA, Ortelli P, et al. The evolution of alexia in two cases of posterior cortical atrophy. *Behav Neurol* 2011; 24: 229–36.
- 41 Goodale MA, Milner AD. Separate visual pathways for perception and action. *Trends Neurosci* 1992; 15: 20–25.
- 42 Ungerleider LG, Mishkin M. Two cortical visual systems. In: Ingle DJ, Goodale MA, Mansfield RJW, eds. Analysis of visual behaviour. Cambridge: MIT Press, 1982: 549–86.
- 43 Josephs KA, Whitwell JL, Boeve BF, et al. Visual hallucinations in posterior cortical atrophy. *Arch Neurol* 2006; 63: 1427–32.
- 44 Duning T, Warnecke T, Mohammadi S, et al. Pattern and progression of white-matter changes in a case of posterior cortical atrophy using diffusion tensor imaging. *J Neurol Neurosurg Psychiatry* 2009; 80: 432–36.
- 45 Yoshida T, Shiga K, Yoshikawa K, Yamada K, Nakagawa M. White matter loss in the splenium of the corpus callosum in a case of posterior cortical atrophy: a diffusion tensor imaging study. *Eur Neurol* 2004; 52: 77–81.
- 46 Migliaccio R, Agosta F, Toba MN, et al. Brain networks in posterior cortical atrophy: a single case tractography study and literature review. *Cortex* 2011; published online Oct 20, 2011. DOI:10.1016/j.cortex.2011.10.002.
- 47 Gardini S, Conconi L, Pagliara S, Ghetti C, Venneri A, Caffarra P. Visuo-spatial imagery impairment in posterior cortical atrophy: a cognitive and SPECT study. *Behav Neurol* 2011; 24: 123–32.
- 48 Aharon-Peretz J, Israel O, Goldsher D, Peretz A. Posterior cortical atrophy variants of Alzheimer's disease. *Dement Geriatr Cogn Disord* 1999; 10: 483–87.
- 49 Goethals M, Santens P. Posterior cortical atrophy: two case reports and a review of the literature. *Clin Neurol Neurosurg* 2001; 103: 115–19.
- 50 Pietrini P, Furey ML, Graff-Radford N, et al. Preferential metabolic involvement of visual cortical areas in a subtype of Alzheimer's disease: clinical implications. *Am J Psychiatry* 1996; 153: 1261–68.
- 51 Wakai M, Honda H, Takahashi A, Kato T, Ito K, Hamanaka T. Unusual findings on PET study of a patient with posterior cortical atrophy. *Acta Neurol Scand* 1994; 89: 458–61.
- 52 Nestor PJ, Caine D, Fryer TD, Clarke J, Hodges JR. The topography of metabolic deficits in posterior cortical atrophy (the visual variant of Alzheimer's disease) with FDG-PET. *J Neurol Neurosurg Psychiatry* 2003; 74: 1521–29.
- 53 Ng SY, Villemagne VL, Masters CL, Rowe CC. Evaluating atypical dementia syndromes using positron emission tomography with carbon 11 labeled Pittsburgh compound B. *Arch Neurol* 2007; 64: 1140–44.
- 54 Kambe T, Motoi Y, Ishii K, Hattori N. Posterior cortical atrophy with [C-11] Pittsburgh compound B accumulation in the primary visual cortex. *J Neurol* 2010; 257: 469–71.
- 55 Tenovuo O, Kemppainen N, Aalto S, Nägren K, Rinne JO. Posterior cortical atrophy: a rare form of dementia with in vivo evidence of amyloid-beta accumulation. *J Alzheimers Dis* 2008; 15: 351–55.
- 56 Formaglio M, Costes N, Seguin J, et al. In vivo demonstration of amyloid burden in posterior cortical atrophy: a case series with PET and CSF findings. *J Neurol* 2011; 258: 1841–51.
- 57 de Souza LC, Corlier F, Habert MO, et al. Similar amyloid- β burden in posterior cortical atrophy and Alzheimer's disease. *Brain* 2011; 134: 2036–43.

- 58 Depaz R, Stéphane H, Peoc'h K, et al. Long-standing prion dementia manifesting as posterior cortical atrophy. *Alzheimer Dis Assoc Disord* 2011; published online Sept 28. DOI:10.1097/WAD.0b013e318231e449.
- 59 van der Flier WM, Schoonenboom SNM, Pijnenburg YAL, Fox NC, Scheltens P. The effect of APOE genotype on clinical phenotype in Alzheimer disease. *Neurology* 2006; **67**: 526–27.
- 60 Baumann TP, Duyar H, Sollberger M, et al. CSF-tau and CSF-A β_{1-42} in posterior cortical atrophy. *Dement Geriatr Cogn Disord* 2010; **29**: 530–33.
- 61 Saunders AM, Strittmatter WJ, Schmechel D, et al. Association of apolipoprotein E allele epsilon 4 with late-onset familial and sporadic Alzheimer's disease. *Neurology* 1993; **43**: 1467–72.
- 62 Farrer LA, Cupples LA, Haines JL, et al. Effects of age, sex, and ethnicity on the association between apolipoprotein E genotype and Alzheimer disease: a meta-analysis. *JAMA* 1997; **278**: 1349–56.
- 63 Balasa M, Gelpi E, Antonell A, et al. Clinical features and APOE genotype of pathologically proven early-onset Alzheimer disease. *Neurology* 2011; **76**: 1720–25.
- 64 Pendleton N, Payton A, van den Booger EH, et al. Apolipoprotein E genotype does not predict decline in intelligence in healthy older adults. *Neurosci Lett* 2002; **324**: 74–76.
- 65 Hof PR, Bouras C, Constantinidis J, Morrison JH. Selective disconnection of specific visual association pathways in cases of Alzheimer's disease presenting with Balint's syndrome. *J Neuropathol Exp Neurol* 1990; **49**: 168–84.
- 66 Hof PR, Bouras C, Constantinidis J, Morrison JH. Balint's syndrome in Alzheimer's disease: specific disruption of the occipito-parietal visual pathway. *Brain Res* 1989; **493**: 368–75.
- 67 Alladi S, Xuereb J, Bak T, et al. Focal cortical presentations of Alzheimer's disease. *Brain* 2007; **130**: 2636–45.
- 68 Tang-Wai DF, Josephs KA, Boeve BF, Dickson DW, Parisi JE, Petersen RC. Pathologically confirmed corticobasal degeneration presenting with visuospatial dysfunction. *Neurology* 2003; **61**: 1134–35.
- 69 Jellinger KA, Grazer A, Petrovic K, et al. Four-repeat tauopathy clinically presenting as posterior cortical atrophy: atypical corticobasal degeneration? *Acta Neuropathol* 2011; **121**: 267–77.
- 70 Tang-Wai DF, Josephs KA, Boeve BF, Petersen RC, Parisi JE, Dickson DW. Coexistent Lewy body disease in a case of "visual variant of Alzheimer's disease". *J Neurol Neurosurg Psychiatry* 2003; **74**: 389.
- 71 Victoroff J, Ross GW, Benson DF, Verity MA, Vinters HV. Posterior cortical atrophy: neuropathologic correlations. *Arch Neurol* 1994; **51**: 269–74.
- 72 Hof PR, Vogt BA, Bouras C, Morrison JH. Atypical form of Alzheimer's disease with prominent posterior cortical atrophy: a review of lesion distribution and circuit disconnection in cortical visual pathways. *Vision Res* 1997; **37**: 3609–25.
- 73 Hof PR, Archin N, Osmand AP, et al. Posterior cortical atrophy in Alzheimer's disease: analysis of a new case and reevaluation of a historical report. *Acta Neuropathol* 1993; **86**: 215–23.
- 74 de Souza LC, Lamari F, Belliard S, et al. Cerebrospinal fluid biomarkers in the differential diagnosis of Alzheimer's disease from other cortical dementias. *J Neurol Neurosurg Psychiatry* 2011; **82**: 240–46.
- 75 Green RC, Goldstein FC, Mirra SS, Alazraki NP, Baxt JL, Bakay RAE. Slowly progressive apraxia in Alzheimer's disease. *J Neurol Neurosurg Psychiatry* 1995; **59**: 312–15.
- 76 Dubois B. Markers of prodromal Alzheimer's disease in the clinic. *Alzheimers Dement* 2010; **6** (4 suppl): S86–87 (abstr F2-01-01). DOI:10.1016/j.jalz.2010.05.261.
- 77 McKhann GM, Knopman DS, Chertkow H, et al. The diagnosis of dementia due to Alzheimer's disease: recommendations from the National Institute on Aging-Alzheimer's Association workgroups on diagnostic guidelines for Alzheimer's disease. *Alzheimers Dement* 2011; **7**: 263–69.
- 78 Kim E, Lee Y, Lee J, Han SH. A case with cholinesterase inhibitor responsive asymmetric posterior cortical atrophy. *Clin Neurol Neurosurg* 2005; **108**: 97–101.
- 79 Roca M, Gleichgerricht E, Torralva T, Manes F. Cognitive rehabilitation in posterior cortical atrophy. *Neuropsychol Rehabil* 2010; **20**: 528–40.