

**Fabrice Compain,
Dominique Decré,
Isabelle Frazier,
Astrid Ramahefasolo,
Marie Lavollay,
Etienne Carbonnelle,
Hidayeth Rostane, Arzu Tackin,
Anne Berger-Carbonne,
and Isabelle Podglajen**

Author affiliations: Hôpital Européen Georges Pompidou, AP-HP, Paris, France (F. Compain, I. Frazier, A. Ramahefasolo, M. Lavollay, E. Carbonnelle, H. Rostane, A. Tackin, A. Berger-Carbonne, I. Podglajen); Université Pierre et Marie Curie, Paris (D. Decré); Université Paris Descartes, Paris (M. Lavollay, E. Carbonnelle, I. Podglajen); Collège de France Centre de Recherche Interdisciplinaire en Biologie, Paris (I. Podglajen); and Institut National de la Santé et de la Recherche Médicale, Paris (M. Lavollay, E. Carbonnelle, I. Podglajen)

DOI: <http://dx.doi.org/10.3201/eid2007.131638>

References

- Savard P, Perl TM. A call for action: managing the emergence of multidrug-resistant *Enterobacteriaceae* in the acute care settings. *Curr Opin Infect Dis*. 2012;25:371–7. <http://dx.doi.org/10.1097/QCO.0b013e3283558c17>
- Glasner C, Albiger B, Buist G, Tambić Andrasević A, Canton R, Carmeli Y, et al.; European Survey on Carbapenemase-Producing Enterobacteriaceae Working Group. Carbapenemase-producing *Enterobacteriaceae* in Europe: a survey among national experts from 39 countries, February 2013. *Euro Surveill*. 2013;18:20525.
- Centers for Disease Control and Prevention, National Center for Emerging and Zoonotic Infectious Diseases. Guidance for control of infections with carbapenem-resistant or carbapenemase-producing *Enterobacteriaceae* in acute care facilities [cited 2013 Mar 5]. <http://www.cdc.gov/hai/pdfs/cre/CRE-guidance-508.pdf>
- Vaux S, Carbonne A, Thiolet JM, Jarlier V, Coignard B; RAISIN and Expert Laboratories Groups. Emergence of carbapenemase-producing *Enterobacteriaceae* in France, 2004 to 2011. *Euro Surveill*. 2011;16:19880.
- Cantón R, Akóva M, Carmeli Y, Giske CG, Glupczynski Y, Gniadkowski M, et al.; European Network on Carbapenemases. Rapid evolution and spread of carbapenemases among *Enterobacteriaceae* in Europe. *Clin Microbiol Infect*. 2012;18:413–31. <http://dx.doi.org/10.1111/j.1469-0691.2012.03821.x>
- Lepelletier D, Andremont A, Grandbastien B; National Working Group. Risk of highly resistant bacteria importation from repatriates and travelers hospitalized in foreign countries: about the French recommendations to limit their spread. *J Travel Med*. 2011;18:344–51. <http://dx.doi.org/10.1111/j.1708-8305.2011.00547.x>
- Haut Conseil de la Santé Publique. Prévention de la transmission croisée des Bactéries Hautement Résistantes aux antibiotiques émergentes (BHRé) [cited 2013 Jul 10]. http://www.hcsp.fr/Explore.cgi/Telecharger?NomFichier=hcsp20130710_recoprevtransxbhre.pdf
- Vardakas KZ, Rafailidis PI, Konstantelias AA, Falagas ME. Predictors of mortality in patients with infections due to multidrug resistant Gram negative bacteria: the study, the patient, the bug or the drug? *J Infect*. 2013;66:401–14. <http://dx.doi.org/10.1016/j.jinf.2012.10.028>
- Dortet L, Poirel L, Nordmann P. Rapid identification of carbapenemase types in *Enterobacteriaceae* and *Pseudomonas* spp. by using a biochemical test. *Antimicrob Agents Chemother*. 2012;56:6437–40. <http://dx.doi.org/10.1128/AAC.01395-12>
- Dortet L, Cuzon G, Nordmann P. Dissemination of carbapenemase-producing *Enterobacteriaceae* in France. *J Antimicrob Chemother*. 2014;69:623–7. <http://dx.doi.org/10.1093/jac/dkt433>

Address for correspondence: Isabelle Podglajen, Service de Microbiologie, Assistance Publique-Hôpitaux de Paris, Hôpital Européen Georges Pompidou, 20 rue Leblanc, 75015, Paris, France; email: isabelle.podglajen@egp.aphp.fr

Zoonotic Filariasis Caused by Novel *Brugia* sp. Nematode, United States, 2011

To the Editor: Zoonotic brugian filariasis is an incidental infection of humans with *Brugia* spp. nematodes

that primarily parasitize nonhuman vertebrates, rarely humans (1–3). In contrast to classical lymphatic filariasis caused by *B. malayi* and *B. timori*, which are found in Asia, most zoonotic *Brugia* infections have been reported from the northeastern United States (2,3) or South America (3). We report a case of symptomatic brugian infection in a New York City resident who had not traveled to the Eastern Hemisphere.

In 2011, a 53-year-old White man first noted tenderness and swelling behind his penis and in his right groin after having fallen 3 months earlier. The tenderness was relieved by non-steroidal antiinflammatory drugs, but the swelling continued; an oral antimicrobial drug, prescribed for presumed cellulitis, produced no improvement. At the time of examination, the patient had no fever or other signs or symptoms. Only a 3.0-cm × 3.0-cm firm, nonfixed right inguinal nodule without warmth or tenderness was noted. Laboratory findings were remarkable for total leukocytes of 6.4×10^9 , eosinophilia (12%, 600 cells/mm³), decreased hemoglobin level (10.0 g/dL), and low hematocrit of 31.2%. An excisional biopsy sample revealed intralymphatic adult nematodes with viable-appearing microfilaria (online Technical Appendix Figure, wwwnc.cdc.gov/EID/article/20/7/13-1654-Techapp1.pdf).

The patient had been born and raised in Champlain, Illinois, and had resided in the Bronx, New York, since 1979; he had no history of travel to filariasis-endemic regions. Characteristics of the adult worms and microfilaria were most consistent with those of *Brugia* spp., which was surprising because classical brugian lymphatic filariasis seems to be limited to Asia (*B. malayi*) and Indonesia (*B. timori*) (4,5). However, the adult filariae were smaller than expected for *B. malayi* or *B. timori* nematodes, prompting consideration of zoonotic filariasis (1,6). The adult worms and microfilaria seemed to be viable, although zoonotic *Brugia* spp. in histologic

sections often appear degenerated (1,2,6). The diameters of the adult worms were similar to those reported from South America (females 90–100 μm , males 50 μm) (7,8) rather than those from North America (females 35–75 μm , males 32–52 μm) (1). Peripheral blood was repeatedly negative for microfilaria. Serum sent to the Centers for Disease Control and Prevention (Atlanta, GA, USA) for ELISA testing for *B. malayi* anti-filarial IgG 4 showed optical density of 0.13, below the ELISA cutoff for filariasis.

Because micromorphologic information was not adequate for species identification, paraffin-embedded biopsy specimens were submitted for molecular testing. Genomic DNA extracted from paraffin-embedded tissue with the QIAamp DNA–formalin-fixed, paraffin-embedded tissue procedure was amplified by using the primer sets DiBu-F(5' GCTAGATATGCTACCAACAAA-3')/ITS1 R(5'-CTCAATGCGTCTGCAATTCGC-3') and BuF2-(5-CATTATGCTAGATATGCTACCAAC-3')/ITS1-R.

The products were fractionated on 2% agarose gel and stained with ethidium bromide. The internal transcribed spacer (ITS) 1 PCR product (182 bp) was automatically sequenced by using the same primers used for PCR. Lasergene software (DNASTAR, Madison, WI, USA) was used to align the sequences obtained with *Brugia* spp. sequences deposited in GenBank; detailed sequence comparison identified the isolate as a novel *Brugia* (Nematoda: Onchocercidae) species closely related to *B. pahangi* and *B. malayi* (Figure). The ITS-1 sequence was submitted to the EMBL Nucleotide Sequence Database (accession no. HE856316).

Removal of an affected lymph node without additional treatment is often considered sufficient treatment for zoonotic filariases. However, for the patient reported here, persistence of inguinal swelling prompted a repeat biopsy 4 months later; the specimen again demonstrated reactive follicular hyperplasia, although no parasites were seen. Because the patient's initial

clinical signs and subsequent persistent adenopathy were reminiscent of unilateral lymphadenitis, lymphangitis, and induration that are typical of *B. malayi* or *B. timori* filariasis, and the microfilariae in the original biopsy sample appeared to be viable, we empirically prescribed a standard dosage of oral doxycycline for 6 weeks, followed by single doses of ivermectin at 400 $\mu\text{g}/\text{kg}$ and 800 mg albendazole. The patient has been well, without further adenopathy or eosinophilia, for >2 years. Because adult filariae can live for >10 years, the place of acquisition cannot be stated with certainty.

The prevalence of zoonotic infection with *Brugia* spp. nematodes is unknown. Many reported cases are asymptomatic or diagnosed incidentally during evaluation for persistent adenopathy (1–3). Conversely, differentiation of zoonotic from classical filariasis is unlikely in disease-endemic areas; most cases published since the initial 1962 case report (1) occurred in the United States. Most case-patients were from the Northeast,

JQ327146	--AAAAAAAAAAAAAAAAAGACATACAAAAAATTATATATATATATATTATAGTAATAATAA	58
EU373624	---AAAAAAAAAAAAAAAAAGACATACAAAAAAT--TATATATATATATTATAGTAATAATAA	56
EU419348	--AAAAAAAAAAAAAAAAAGACATACAAAAAAT----ATATATATATATTATAGTAATAATAA	54
EU373632	-----AAAAAAAAAAAAACATACAAAAAAGT---TATATATATATTATAGTAATAACAA	50
EU373630	-----AAAAAAAAAAAAACATACAAAAAAGT---TATATATATATTATAGTAATAACAA	50
AY621469	AAAAAAAAAAAAAAAAAACATACAAAAAAGT---TATACATATATTATAGTAATAACAA	57
EU419351	-----AAAAAAAAAAAAACATACAAAAAAGT---TATACATATATTATAGTAATAACAA	53
HE856316	---AAAAAAAAAAAAAACATACACATAAATTTG--TATATATATAATAGTAATAACAA	57
EU373647	-----AAAAAAAAAAAAACATACAAAAAAGT---TATATATATATTATAGTAATAACAA	51
	*****..*****.*:** *** *****:***** **	
JQ327146	T-AAAATTTTTTTAACTCTTAGCGGTGGATCACTTGGCTCATGGATCGATGAGGAACG	117
EU373624	T-AAAATTTTTTTAACTCTTAGCGGTGGATCACTTGGCTCATGGATCGATGAAGAACG	115
EU419348	TAAAATTTTTTTAACTCTTAGCGGTGGATCACTTGGCTCATGGATCGATGAAGAACG	114
EU373632	T---AAAATTTTTTTAACTCTTAGCGGTGGATCACTTGGCTCATGGATCGATGAAGAACG	107
EU373630	T---AAAATTTTTTTAACTCTTAGCGGTGGATCACTTGGCTCATGGATCGATGAAGAACG	107
AY621469	T---AAAATTTTTTTAACTCTTAGCGGTGGATCACTTGGCTCATGGATCGATGAAGAACG	115
EU419351	T---AAAATTTTTTTAACTCTTAGCGGTGGATCACTTGGCTCATGGATCGATGAAGAACG	111
HE856316	T---AAAATTTTTTTAACTCTTAGCGGTGGATCACTTGGCTCATGGATCGATGAAGAACG	114
EU373647	T---AAAATTTTTTTAACTCTTAGCGGTGGATCACTTGTCTCATGGATCGATGAAGAACG	108
	* ***:*****	
JQ327146	CAGCTAGCTGCGA	130 (92.13%)
EU373624	CAGCTAGCTGCGA	128 (92.80%)
EU419348	CAGCTAGCTGCGA	127 (94.35%)
EU373632	CAGCTAGCTGCGA	120 (95.83%)
EU373630	CAGCTAGCTGCGA	120 (95.00%)
AY621469	CAGCTAGCTGCGA	128 (93.60%)
EU419351	CAGCTAGCTGCGA	124 (94.31%)
HE856316	CAGCTAGCTGCGA	127
EU373647	CAGCTAGCTGCGA	121 (94.21%)

Figure. Pile-up of partial ribosomal DNA sequences from *Brugia* NY strain (HE856316) and from other related *Brugia* spp. strains and clones, *B. malayi* BM28 (JQ327146), *B. malayi* C27Cat5 (EU373624), *B. pahangi* C61CAT5 (EU419348), *B. pahangi* C14Cat6 (EU373632), *B. pahangi* C7Cat6 (EU373630), *B. pahangi* Bp-1 (AY621469), *B. pahangi* C46CAT5 (EU419351), and *B. pahangi* C27Cat7 (EU373647). Boxes indicate the *Brugia* NY strain (HE856316); asterisks (*) indicate conserved residues; periods (.) indicate nucleotide changes; colons (:) indicate nucleotide changes just in the *Brugia* NY isolate; hyphens (-) are included in the sequences to maximize the comparisons among the 9 DNA molecules. Italicized numbers in parentheses indicate the percentage of similarity with the *Brugia* NY isolate.

including New York (8 cases), Massachusetts, Pennsylvania, Connecticut, and Rhode Island (3 cases each) (1,2); single cases have been identified in Michigan, Ohio, North Carolina, Oklahoma, New Jersey, Louisiana, Florida, and California (1,2). Four other cases have been reported: 3 in South America (Colombia, Brazil, Peru) (3,7,8) and 1 in Africa (Ethiopia) (9). Only a few *Brugia* species have been identified, including *B. leporis*, found in rabbits in the northeastern United States (1,10); *B. beaveri*, found in raccoons and bobcats in the southern United States; and *B. guyanensis*, found in coati-mundi and other vertebrates in South America (8). Definitive identification with molecular techniques will better identify causative species and help clarify many of the ecologic and epidemiologic questions surrounding zoonotic filarial infections.

This work was supported by the Instituto de Salud Carlos III, Fondo de Investigaciones Sanitarias, through the sixth national plan of research plus development plus innovation (2008–2011), Instituto de Salud Carlos III–General Sub-Direction of Networks and Centers for Collaborative Research (Red Temática de Investigación Cooperativa–Red de Investigación Cooperativa en Enfermedades Tropicales, grant no. RD12/0018/003).

**Alberto Enrique Paniz-Mondolfi,
Teresa Gárate,
Christine Stavropoulos,
Wen Fan,
Luis Miguel González,
Mark Eberhard,
Fred Kimmelstiel,
and Emilia Mia Sordillo**

Author affiliations: Yale University School of Medicine, New Haven, Connecticut, USA (A.E. Paniz-Mondolfi); St. Luke's-Roosevelt Hospital Center of Columbia University College of Physicians and Surgeons, New York, New York, USA (A.E. Paniz-Mondolfi, C. Stavropoulos, W. Fan, F. Kimmelstiel, E.M. Sordillo); Servicio Autonomo

Instituto de Biomedicina/Instituto Venezolano de los Seguros Sociales, Caracas, Venezuela (A. Paniz Mondolfi); Instituto de Salud Carlos III, Madrid, Spain (T. Gárate, L.M. González); and Centers for Disease Control and Prevention, Atlanta, Georgia, USA (M. Eberhard)

DOI: <http://dx.doi.org/10.3201/eid2007.131654>

References

1. Orihel TC, Eberhard ML. Zoonotic filariasis. *Clin Microbiol Rev*. 1998;11:366–81.
2. Eberhard ML, DeMeester LJ, Martin BW, Lammie PJ. Zoonotic *Brugia* infection in western Michigan. *Am J Surg Pathol*. 1993;17:1058–61. <http://dx.doi.org/10.1097/0000478-199310000-00012>
3. Orihel TC, Beaver PC. Zoonotic *Brugia* infections in North and South America. *Am J Trop Med Hyg*. 1989;40:638–47.
4. Taylor MJ, Hoerauf A, Bockarie M. Lymphatic filariasis and onchocerciasis. *Lancet*. 2010;376:1175–85. [http://dx.doi.org/10.1016/S0140-6736\(10\)60586-7](http://dx.doi.org/10.1016/S0140-6736(10)60586-7)
5. Schneider MC, Aguilera XP, Barbosa da Silva Junior J, Ault SK, Najera P, Martinez J, et al. Elimination of neglected diseases in Latin America and the Caribbean: a mapping of selected diseases. *PLoS Negl Trop Dis*. 2011;5:e964. <http://dx.doi.org/10.1371/journal.pntd.0000964>
6. Gutierrez Y. Diagnostic features of zoonotic filariae in tissue sections. *Hum Pathol*. 1984;15:514–25. [http://dx.doi.org/10.1016/S0046-8177\(84\)80004-0](http://dx.doi.org/10.1016/S0046-8177(84)80004-0)
7. Kozek WJ, Reyes MA, Ehrman J, Garrido F, Nieto M. Zoonotic *Brugia* infection in a two-year old Colombian girl. *Am J Trop Med Hyg*. 1984;33:65–9.
8. Baird JK, Neafie RC. South American brugian filariasis: report of a human infection acquired in Peru. *Am J Trop Med Hyg*. 1988;39:185–8.
9. Menéndez MC, Bouza M. *Brugia* species in a man from western Ethiopia. *Am J Trop Med Hyg*. 1988;39:189–90.
10. Beaver PC, Orihel TC. Human infection with filariae of animals in the United States. *Am J Trop Med Hyg*. 1965;14:1010–29.

Address for correspondence: Alberto E. Paniz-Mondolfi, Yale–New Haven Hospital, Microbiology Laboratory (PS656), 55 Park St, New Haven, CT 06511, USA; email: albertopanz@yahoo.com

**Search past
issues of EID at
wwwnc.cdc.gov/eid**

***Candida auris*– Associated Candidemia, South Africa**

To the Editor: We noted the report by Chowdhary et al. (1) and report *Candida auris* as a causative agent of candidemia in South Africa, with an estimated prevalence of 0.3% (N.P. Govender et al., unpub. data). First isolated in 2009, *C. auris* is an emerging species associated with clinical disease (2–6). We analyzed 4 isolates submitted to the National Institute for Communicable Diseases (Johannesburg, South Africa) from 4 patients with candidemia who had been admitted to different public- and private-sector hospitals from October 2012 through October 2013.

Identification of the isolates was undertaken by using ChromAgar *Candida* medium (Mast Diagnostics, Merseyside, UK), Vitek-2 YST (bioMérieux, Marcy l'Etoile, France), API 20C AUX (bioMérieux), and sequencing of internal transcribed spacer (ITS) and D1/D2 domains of the ribosomal RNA gene (7), followed by microbroth dilution susceptibility testing (8). All isolates were misidentified as *C. haemulonii* and *Rhodotorula glutinis* by Vitek-2 YST and API 20C AUX assays, respectively (Table).

Similar to the findings of Chowdhary et al., all isolates assimilated *N*-acetyl-glucosamine (1). With the use of the CBS-KNAW database, pairwise sequence alignment of ITS region showed 99% sequence homology to Kuwait isolates, and alignment of D1/D2 domain showed 98% homology to the Kuwait/India isolates (9). In a neighbor-joining phylogenetic tree based on ITS sequences, South Africa isolates formed a cluster with India and Kuwait isolates (online Technical Appendix Figure, <http://wwwnc.cdc.gov/EID/article/20/7/13-1765-Techapp1.pdf>).

Zoonotic Filariasis Caused by Novel *Brugia* sp. Nematode, United States

Technical Appendix

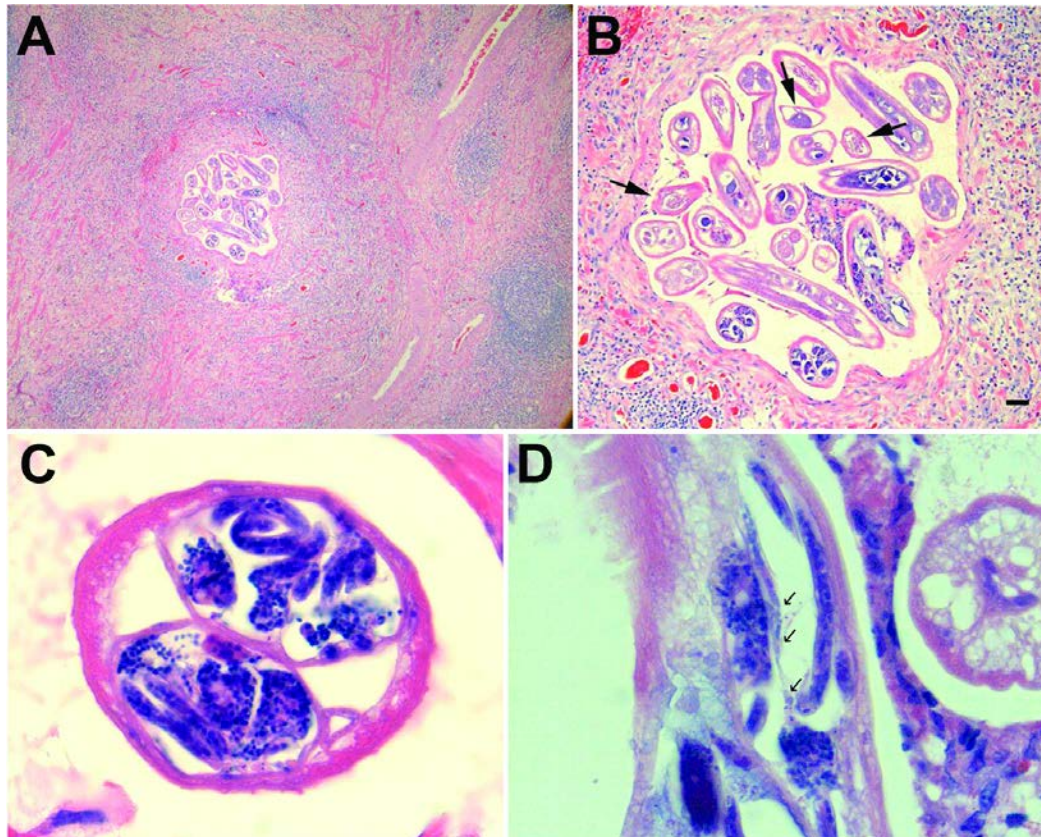


Figure. Histocytologic appearance of *Brugia* nematodes in 53-year-old White man from New York, USA. A) Male and female nematodes within the lymph node with reactive follicular hyperplasia and a lymphohistiocytic granulomatous infiltrate permeated by few scattered eosinophils. Hematoxylin and eosin stain, magnification $\times 5$. B) Male (arrows) and female worms in varying longitudinal and transverse planes. Note that males are smaller than females and have a pseudocoelomic cavity containing a single reproductive tube and intestine. Females are larger and contain paired uterine tubes. Scale bar = 50 μm , hematoxylin and eosin stain, magnification $\times 20$. C) Gravid female. The pseudocoelom is mostly occupied by 2 uterine tubes filled with developing eggs and microfilariae, and the small simple intestine. Note the thin cuticle, which becomes thickened and more prominent over the lateral cords; the low musculature consists of few muscle cells. Hematoxylin and eosin stain, magnification $\times 40$. D) Mature microfilariae in the uterus. The arrows point out the 3 posterior nuclei. Note that the width of the microfilariae ranged from 4.5 μm to 5.5 μm . Hematoxylin and eosin stain, magnification $\times 100$.