

## Reindeer Warble Fly–associated Human Myiasis, Scandinavia

**To the Editor:** We report migratory myiasis that occurred during 1991–2012 caused by the reindeer warble fly, *Hypoderma tarandi* (online Technical Appendix Figures 1, 2, [wwwnc.cdc.gov/EID/article/19/5/13-0145-Techapp1.pdf](http://wwwnc.cdc.gov/EID/article/19/5/13-0145-Techapp1.pdf)), in 7 tourists to reindeer habitats of northern Scandinavia. We also report 2 additional women (patients 8 and 9), independent of each other, who were asymptomatic but sought medical care in August 2012 after finding 30–60 parasite eggs in scalp hair 3 days after hiking in Kebnekaise and Jämtland Mountains (northern Sweden), respectively.

Patients 1–7 (Table) had enlarged regional lymph nodes and migratory dermal swelling of the head and upper face. Rounded cutaneous swelling of 2–5 cm occurred 1 at a time, persisted for 1–3 days, and reappeared after 2–34 days.

In mid-January 2009, 4 months after initial symptoms, patient 1 felt a sudden pain in his left eye; 10 days later, an ophthalmologist discovered an intraocular larva (online Technical Appendix Figure 3). Patient 3 had a swelling on his forehead, which reappeared 2' before his right eyelid swelled; the day after the eyelid swelling disappeared, vision decreased in his right eye. Patients 1, 3, and 7 underwent eye surgery; 1 living larva was extracted from each patient. Patients 3 and 7 lost vision in the affected eye.

For 5 patients, ivermectin was administered orally ( $\approx 200$ – $350$   $\mu\text{g}/\text{kg}$  body weight), on 3–5 occasions in relation to the swellings. Patients 8 and 9 also each received 1 dose of ivermectin; they remained asymptomatic. Patient 3 received the first dose on day 5 after the living larva was extracted because of a new swelling. Swelling recurred on 3 occasions 2 weeks–1.5

months after surgery. In patient 7, swelling reappeared on several occasions 10–30 days after eye surgery, indicating that retrieval of 1 larva does not exclude concomitant occult infestations. This probably was also the case for patient 2, who had a swelling on his upper forehead when pain developed at the root of his nose, where a new swelling appeared 4 days later.

The 3 larvae removed from patients 1, 3, and 7 were identified as *H. tarandi*, 2 by morphology and 1 by molecular-specific amplification and sequencing (1). Antibodies against hypodermin C, an enzyme released by the larva during migration in host tissues, were detected in 5 of the symptomatic patients (2,3).

*H. tarandi* eggs take 4–7 days to hatch, depending on the temperature of the hair layer (4); thus, patients 8 and 9 were treated soon after oviposition and were seronegative. Newly hatched *H. tarandi* larvae can easily dry, so their chance of survival is higher when they are close to scalp skin. Eggs from patient 2 were initially misidentified as head lice eggs but were eventually identified as *H. tarandi* by T.G. Jaenson (Uppsala). Published photographs of the *H. tarandi* eggs alongside the eggs of head lice (5) helped identify *H. tarandi* eggs in patients 8 and 9. According to those patients, *H. tarandi* eggs could not be removed from the hair with a lice comb. The *H. tarandi* fly is well adapted to sub-Arctic climate; nearly all reindeer were found to be infested in some districts of northern Finland and Norway (6). Reindeer habitats attract tourists, mostly during summer. *H. tarandi* is mainly active on warm summer days; warm weather perhaps does not encourage persons to cover their heads, which may predispose for oviposition. Also, persons moving around probably attract more flies than do those staying still, and strong wind, rain, and temperatures  $<10^{\circ}\text{C}$ – $12^{\circ}\text{C}$  are thought to inhibit the warble fly's flight activity and oviposition (7).

Awareness of human infestation by *H. tarandi* warble flies increased in Sweden and Norway after news media in Sweden described patient 2 (5; [www.lakartidningen.se/engine.php?articleId=14643](http://www.lakartidningen.se/engine.php?articleId=14643)). This publication helped in the recognition of symptoms and in shortening diagnostic delay in patients 3–6, 8, and 9. Of the 3 cases for which diagnosis was not delayed, patients 4 and 5 were children of a physician who read our publication and recognized the symptoms; patient 6, herself a physician, also read the article (5). Increased awareness, rather than increased incidence, explains the emergence of new cases. Nine of 12 cases of proven *H. tarandi* myiasis found in the literature occurred in persons who had ophthalmomyiasis interna (3,8,9); migratory dermal swellings, the clinical signature of hypodermosis, have been reported only in 1 case (10). Such swellings occurred in all the patients reported here, suggesting that clinicians overlooked this finding, possibly because of the overtaking severity of eye complications and the reporting of most previous cases by ophthalmologists (3,8,9). Persons who seek care for migratory dermal swellings during August–December should be asked about recent travel to reindeer habitats.

For 3 patients with ophthalmomyiasis reported here, ophthalmologists initially had difficulty establishing a diagnosis, raising the possibility that some cases of “idiopathic” uveitis from *H. tarandi*–endemic areas may be caused by *H. tarandi*. Ophthalmomyiasis should be considered in cases of unilateral uveitis, lens subluxation, and suspicion of intraocular foreign body (3,8,9). Eosinophilia might be absent and should not be used to guide treatment.

**Boris Kan, Kjetil Åsbakk,  
Kristian Fossen, Arne Nilssen,  
Rosario Panadero,  
and Domenico Otranto**

Table. Myiasis caused by warble reindeer fly (*Hypoderma tarandi*), Scandinavia, 1991–2012\*

Characteristic	Case-patient no.						
	1	2	3	4†	5	6	7‡
Age, y/sex	8/M	10/M	10/M	10/M	6.5/F	56/F	28/M
Date of symptom onset	2008 Sep 15	2009 Aug 15	2010 Sep 12	2010 Sep 3	2010 Dec 3	2011 Oct 10	1991 Aug
Signs and symptoms	Enlarged occipital and retroauricular lymph nodes	Eggs in scalp hair; enlarged occipital and cervical lymph nodes	Forehead swelling	Enlarged occipital and cervical lymph nodes	Forehead and eyebrow swelling	Occipital swelling	Occipital swelling
Travel							
Dates	2008 late Jul–early Aug	2009 Jul 20–Aug 7	2010 Jul 7–16	2010 Aug 14–19	2010 Aug 14–19	2011 Jul	1991 Jul
Destination	Norway, extreme northeast: patient resides in Troms County where reindeer are occasionally seen	Sweden: Lapland	Sweden: Kiruna, Riksgränsen, Abisko (several short hiking tours) Norway: Bodö	Sweden: family undertook a 5-d hiking tour in Lunndörrsfjällen, a mountain area in Jämtland County	Sweden: family undertook a 5-d hiking tour in Lunndörrsfjällen, a mountain area in Jämtland County	Norway: Lapland	Sweden: short trips to Arvidsjaur (Lapland) and Jämtland Mountains
Observed reindeer	Yes	Yes§	No	Yes; at close range	Yes; at close range	Yes	Yes
Migratory swellings, no.	Temple, 1	Head, 1; forehead, 5	Forehead, 4; eyelid, 1; behind ear, 1	Forehead and eyelid, 5	Forehead and eyelid, 2	Head, temple, eyelid, >5	Head, >5
Fever	Yes	No	No	Yes	No	No	No
Eosinophilia (highest value)¶	Yes (1,0)	Yes (0,6)	Yes (0,8)	Yes (3,8)	No	No	Unknown
Other signs and symptoms	Uveitis, failure to gain weight	Localized exanthema	Itching of scalp, enlarged retroauricular lymph nodes, headache, uveitis	Fever, headache, nausea	No	Enlarged nuchal lymph nodes	Uveitis, glaucoma, retinal hemorrhage
Diagnostic delay, d#	74	25	14	0	0	1	>60
Diagnosis	Positive serology, morphologic identification of larva	Positive serology, identification of eggs	Positive serology, molecular identification of larva	Positive serology	Positive serology	Negative serology**	Negative serology in 2011 and 2012, morphologic identification of larva in 1991
Drugs received							
Ivermectin	No	5 doses	5 doses††	5 doses	3 doses	2 doses	No
Antihistamines	No	Yes	Yes	Yes	Yes	Yes	Unknown
Oral steroids	Yes	No	No	Yes	Yes	Yes	Steroids, antimicrobial drugs given after surgery
Outcome	After eye surgery glaucoma; visual acuity 0,9	Good	Eye surgery; visual loss, right eye	Good	Good	Good	Eye surgery; visual loss, right eye

\*Patients 8 and 9 are not included in the table because myiasis did not develop in them.

†Patients 4 and 5 are siblings.

‡Patient 7 was discovered by the father of patients 4 and 5 among his acquaintances, suggesting the possibility of additional unreported cases in the population.

§In Jukkasjärvi (Sweden), the child had visited an enclosure where the reindeer were agitated because of swarms of flies.

¶Referent 0–0.5 × 10<sup>9</sup>/L.

#Interval between date of first visit for myiasis-associated symptoms and date when treatment began.

\*\*The diagnosis could not be confirmed, but her clinical picture and response to treatment were similar to those of other patients.

††Ivermectin was given first after eye surgery.

Author affiliations: Karolinska University Hospital, Stockholm, Sweden (B. Kan); Hospital of Northern Norway, Tromsø, Norway (K. Fossen); Tromsø University Museum, Tromsø (A. Nilssen); Universidad de Santiago de Compostela, Lugo, Spain (R. Panadero); Università degli Studi di Bari, Valenzano, Italy (D. Otranto)

DOI: <http://dx.doi.org/10.3201/eid1905.130145>

## References

- Otranto D, Colwell DD, Traversa D, Stevens JR. Species identification of *Hypoderma* affecting domestic and wild ruminants by morphological and molecular characterization. *Med Vet Entomol*. 2003;17:316–25. <http://dx.doi.org/10.1046/j.1365-2915.2003.00446.x>
- Asbakk K, Oksanen A, Nieminen M, Haugerud RE, Nilssen AC. Dynamics of antibodies against hypodermin C in reindeer infested with the reindeer warble fly, *Hypoderma tarandi*. *Vet Parasitol*. 2005;129:323–32. <http://dx.doi.org/10.1016/j.vetpar.2005.02.007>
- Lagacé-Wiens PR, Dookeran R, Skinner S, Leicht R, Colwell DD, Galloway TD. Human ophthalmomyiasis interna caused by *Hypoderma tarandi*, northern Canada. *Emerg Infect Dis*. 2008;14:64–6. <http://dx.doi.org/10.3201/eid1401.070163>
- Karter AJ, Folstad I, Anderson JR. Abiotic factors influencing embryonic development, egg hatching, and larval orientation in the reindeer warble fly, *Hypoderma tarandi*. *Med Vet Entomol*. 1992;6:355–62. <http://dx.doi.org/10.1111/j.1365-2915.1992.tb00632.x>
- Kan B, Åsen C, Åsbakk K, Jaenson TG. Suspected lice eggs in the hair of a boy revealed dangerous parasite [in Swedish]. *Lakartidningen*. 2010;107:1694–7.
- Folstad I, Nilssen AC, Halvorsen O, Andersen J. Why do male reindeer (*Rangifer t. tarandus*) have higher abundance of second and third instar larvae of *Hypoderma tarandi* than females? *Oikos*. 1989;55:87–92. <http://dx.doi.org/10.2307/3565877>
- Anderson JR, Nilssen AC. Trapping oestrid parasites of reindeer: the response of *Cephenemyia trompe* and *Hypoderma tarandi* to baited traps. *Med Vet Entomol*. 1996;10:337–46. <http://dx.doi.org/10.1111/j.1365-2915.1996.tb00754.x>
- Syrdalen P, Stenkula S. Ophthalmomyiasis interna posterior. *Graefes Arch Clin Exp Ophthalmol*. 1987;225:103–6. <http://dx.doi.org/10.1007/BF02160340>
- Gjötterberg M, Ingemansson SO. Intraocular infestation by the reindeer warble fly larva: an unusual indication for acute vitrectomy. *Br J Ophthalmol*. 1988;72:420–3. <http://dx.doi.org/10.1136/bjo.72.6.420>
- Chirico J, Stenkula S, Eriksson B, Gjötterberg M, Ingemansson SO, Pehrson-Palmqvist G, et al. Reindeer warble fly larva as a cause of 3 cases of human myiasis [in Swedish]. *Lakartidningen*. 1987;84:2207–8.

Address for correspondence: Boris Kan, Infectious Diseases Unit, Karolinska University Hospital; 171, 76 Stockholm, Sweden; email: boris.kan@karolinska.se

## Azole-Resistant *Aspergillus fumigatus*, Iran

**To the Editor:** *Aspergillus fumigatus* causes a variety of diseases in humans. The drugs recommended for treatment of *Aspergillus* diseases are the mold-active azole antifungal drugs (1). However, a wide range of mutations in *A. fumigatus* confer azole resistance, which commonly involves modifications in the *cyp51A* gene (2), the target for azole antifungal drugs.

Azole resistance is thought to be selected for as a result of patient therapy or exposure to azole compounds in the environment; resistance in clinical *A. fumigatus* isolates has been increasingly reported in several European countries, Asia, and the United States (3–7). The most frequently reported resistance mechanism is a 34-bp tandem repeat (TR<sub>34</sub>) in combination with a substitution at codon 98 (TR<sub>34</sub>/L98H) (4); this mechanism is believed to have been selected for through environmental exposure to azole fungicides.

Because routine in vitro susceptibility testing of clinical *Aspergillus* isolates is not common in many centers worldwide, the prevalence of azole resistance might be underestimated. We investigated the prevalence of azole resistance in clinical *A. fumigatus* isolates stored for 6 years (2003–2009) at Tehran University Mycology Reference Centre and Islamic Azad University, Ardabil Branch, Iran.

We investigated 124 clinical *A. fumigatus* isolates obtained from patients with *Aspergillus* diseases (online Technical Appendix Table 1, [wwwnc.cdc.gov/EID/article/19/5/13-0075-Techapp1.pdf](http://wwwnc.cdc.gov/EID/article/19/5/13-0075-Techapp1.pdf)). We conducted strain identification, in vitro antifungal susceptibility testing, and sequence-based analysis of the *Cyp51A* gene, as described (4). We performed microsatellite genotyping of all *A. fumigatus* isolates for which the MIC of

itraconazole was  $\geq 16$  mg/L (8) by using a short tandem repeat *A. fumigatus* assay, and we compared the results with those reported for the Netherlands (20 isolates) and other European countries (24 isolates) (online Technical Appendix Figure).

The distribution of azole-resistant and wild-type *A. fumigatus* isolates examined in this study, according to year of isolation, is shown in online Technical Appendix Table 1. Of 124 *A. fumigatus* isolates, 4 grew on the wells containing itraconazole and voriconazole, indicating a multidrug-resistant phenotype. Of these resistant isolates, 3 were from patients with chronic pulmonary aspergillosis and 1 was from a patient with allergic bronchopulmonary aspergillosis (Table).

Sequence analysis of the *CYP51A* gene indicated the presence of TR<sub>34</sub>/L98H in 3 isolates and no mutations in the other isolate (Table). The first TR<sub>34</sub>/L98H isolate had been recovered in 2005, which is relatively early compared with reported isolations in other countries (online Technical Appendix Table 2). Microsatellite typing of 6 short tandem repeat loci demonstrated identical patterns for 2 of the 3 azole-resistant isolates from Iran, but the TR<sub>34</sub>/L98H isolates from Iran did not cluster with those from the Netherlands and other European countries, indicating no close genetic relatedness (online Technical Appendix Figure).

The TR<sub>34</sub>/L98H azole resistance mechanism was first described in 1998 in the Netherlands; since then, its presence in clinical and environmental *A. fumigatus* isolates in multiple European countries and recently in Asia has been increasingly reported (online Technical Appendix Table 2) (3–7). In the study reported here, prevalence of azole resistance in clinical *A. fumigatus* isolates obtained from patients in Iran was 3.2%; most isolates exhibited the TR<sub>34</sub>/L98H resistance mechanism. The fact that the first TR<sub>34</sub>/L98H isolate was found relatively early, in 2005, underscores the possibility that prevalence

# Reindeer Warble Fly–associated Human Myiasis, Scandinavia

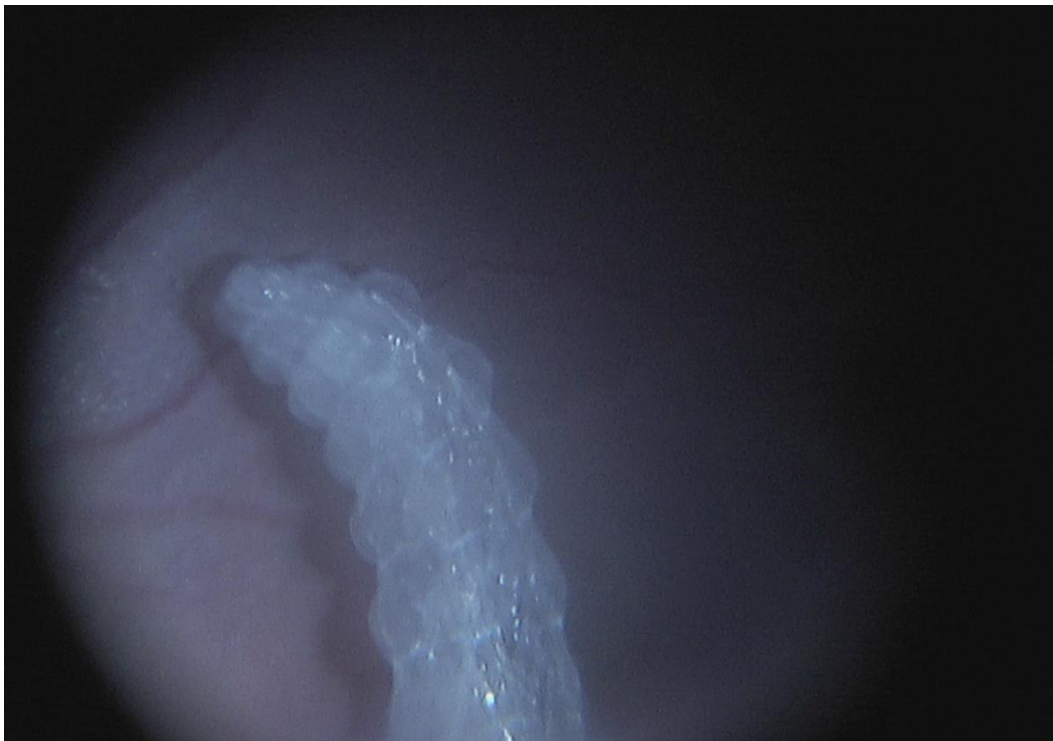
## Technical Appendix



Technical Appendix Figure 1. Female *Hypoderma tarandi* reindeer warble fly in flight. The parasite can fly for many hours and may cover 600–900 km during its lifetime. This flight capacity has evolved to find reindeers. They do not feed as adults. Photo by A. Nilssen.



Technical Appendix Figure 2. Eggs of *Hypoderma tarandi* stick to a reindeer hair with an attachment organ and a glue-like liquid. Upon hatching, the larvae borrow through the skin near the root of the hair shaft. Photo by K. Åsbakk.



Technical Appendix Figure 3. Intraocular larvae crawling on retinal surface of patient 1. Photo taken intraoperatively by K. Fossen.