

# Supplemental Material

## Quantitative Fundus Autofluorescence Distinguishes *ABCA4*-associated and non-*ABCA4*- associated Bull's-Eye Maculopathy

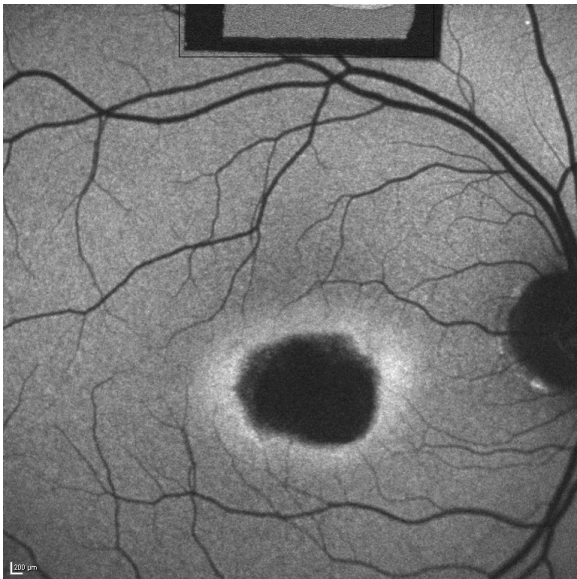
Duncker et al.

AF images of all BEM eyes included in the study are  
presented in the following format:

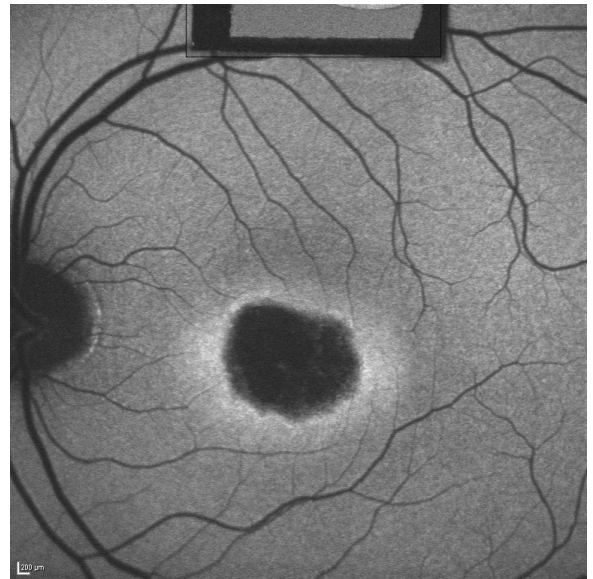
OD

Patient #  
(Table)

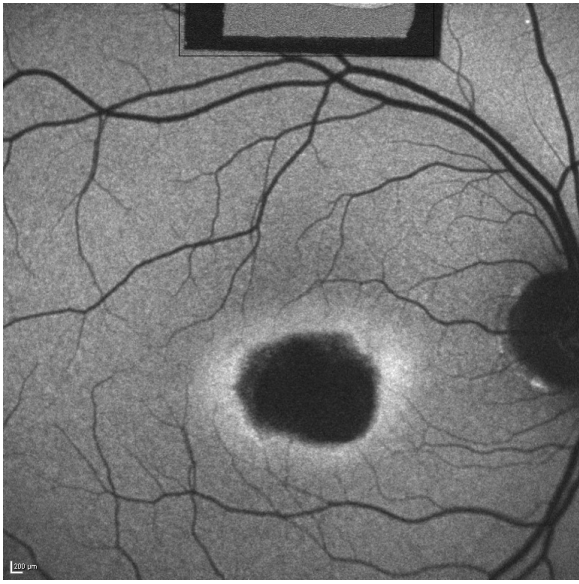
OS



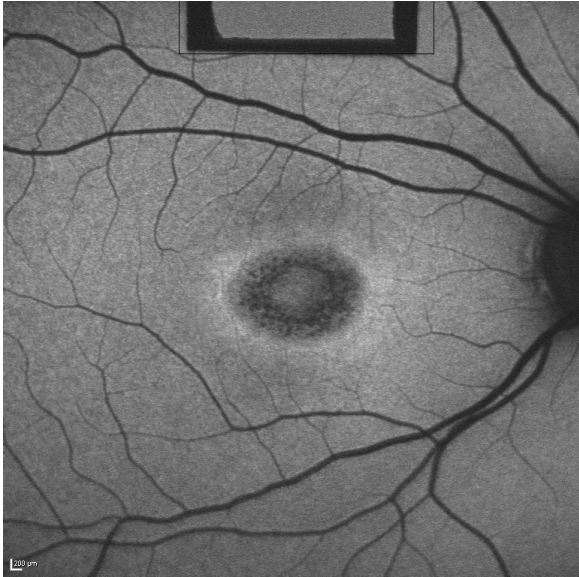
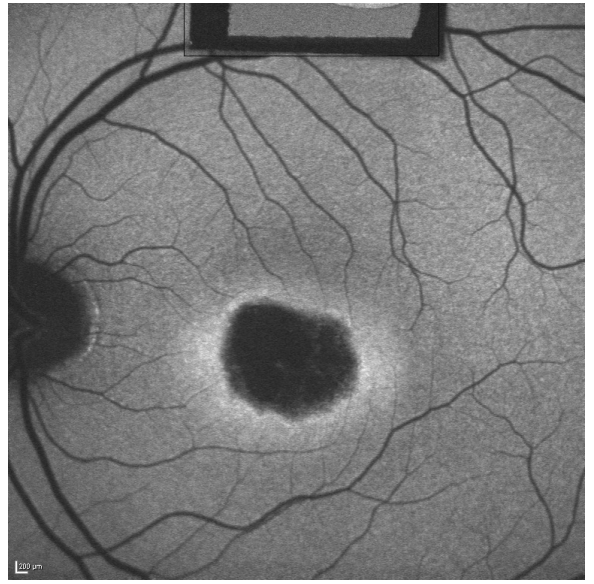
1  
+



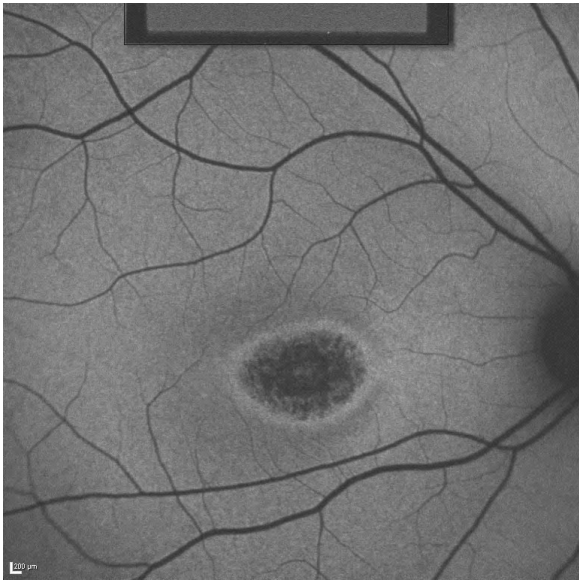
*ABCA4*  
+ / -



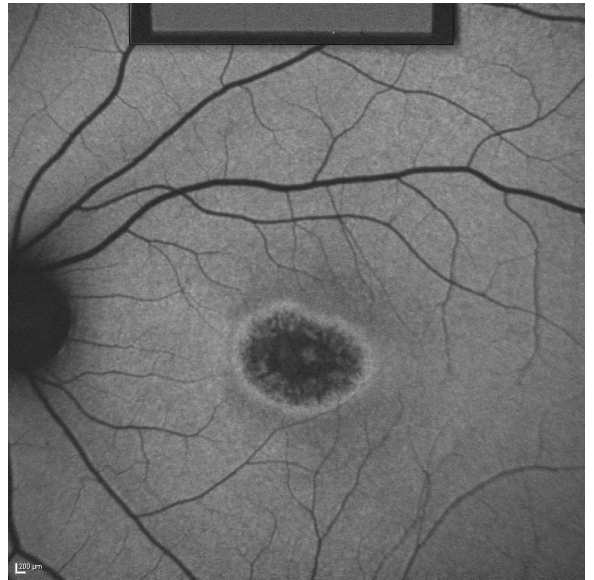
1  
+

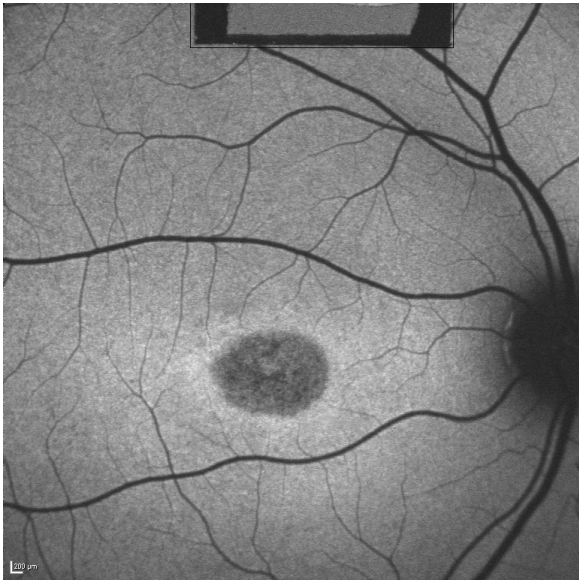


2  
+

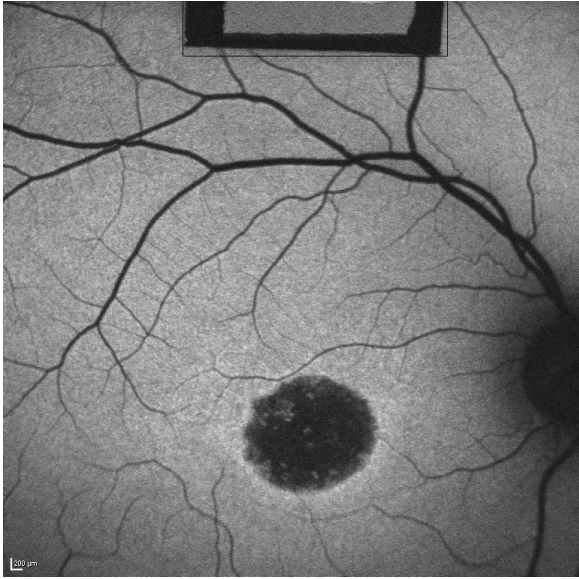
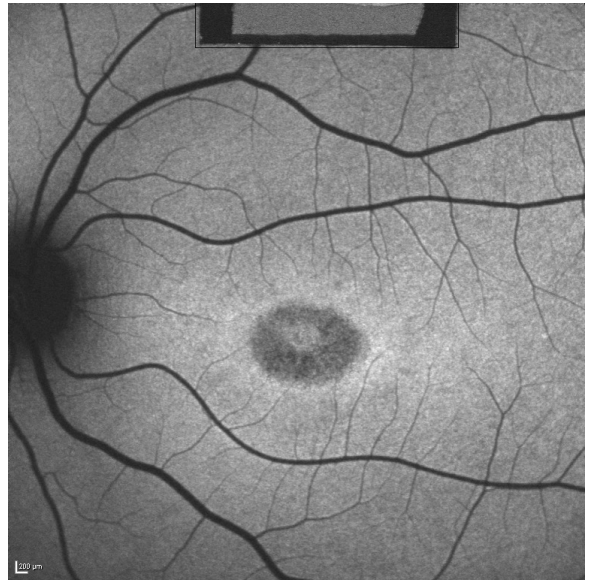


3  
+

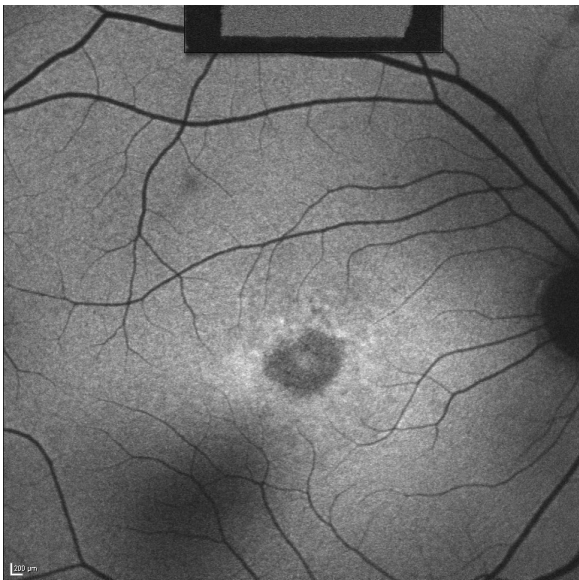
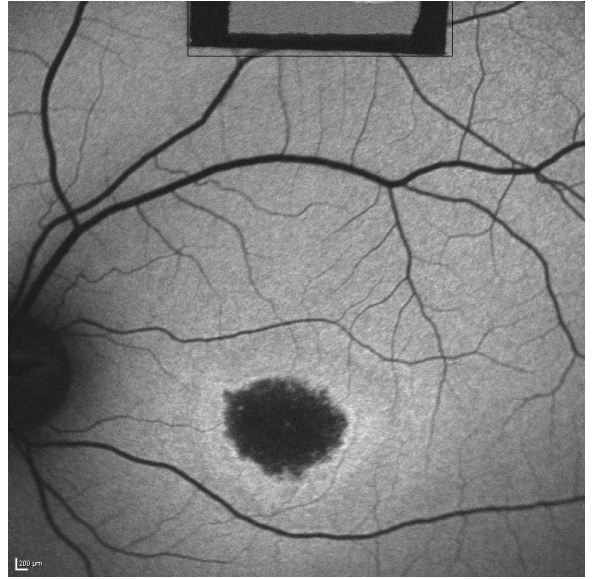




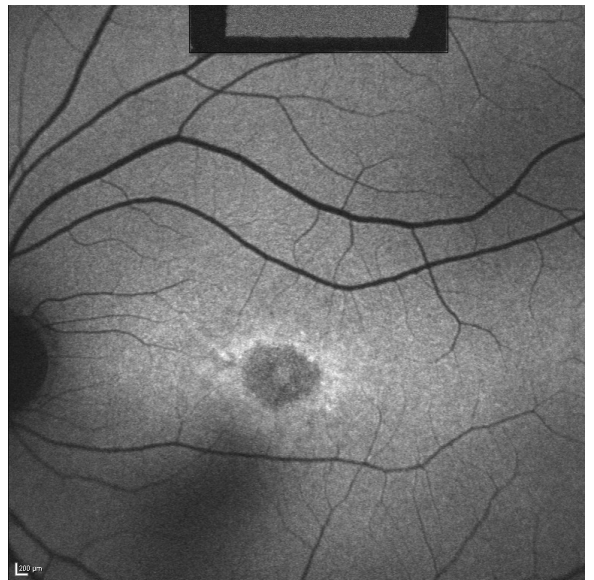
4  
+

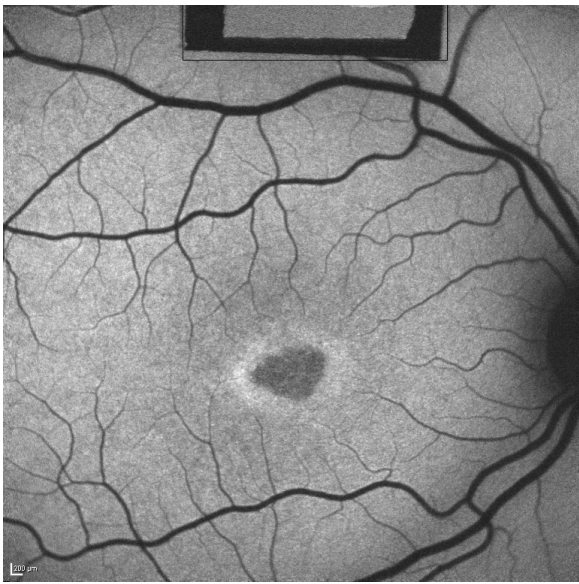


5  
+

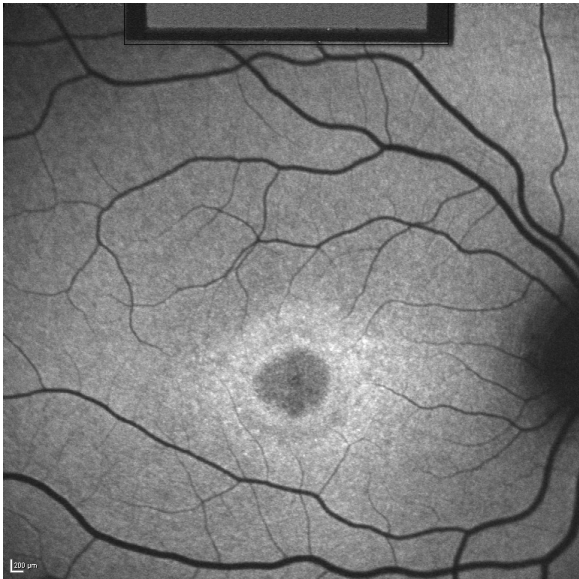


6  
+

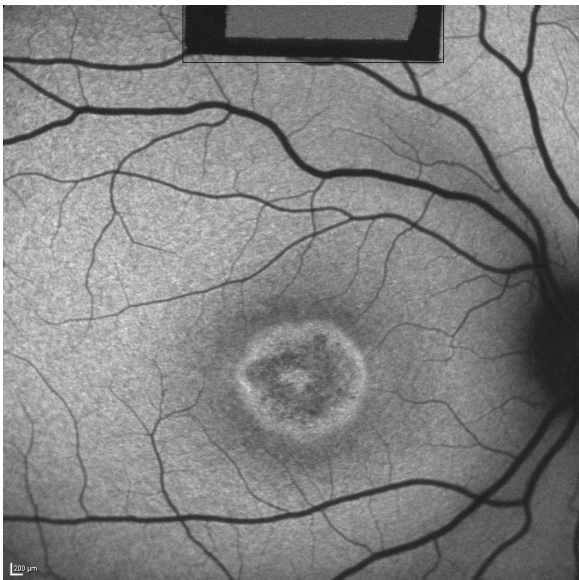
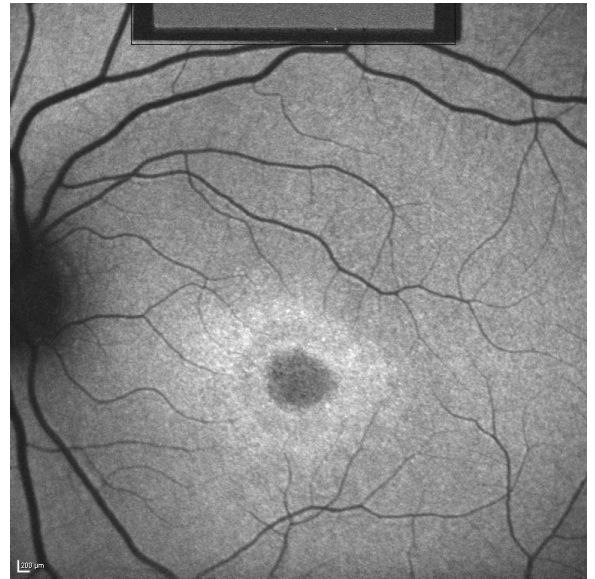



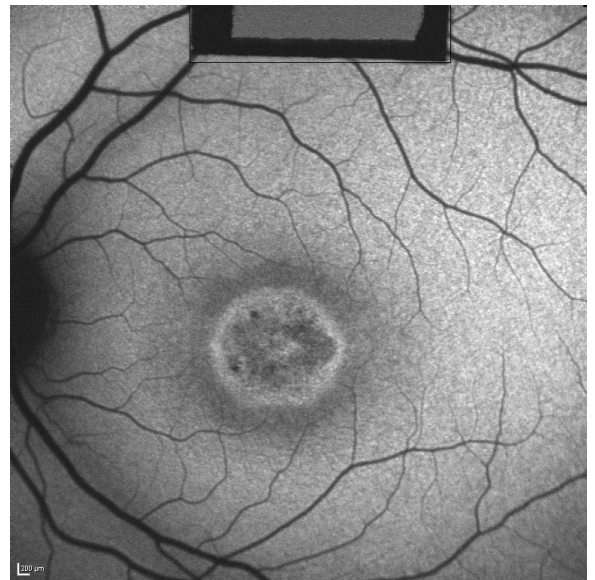
7  
+

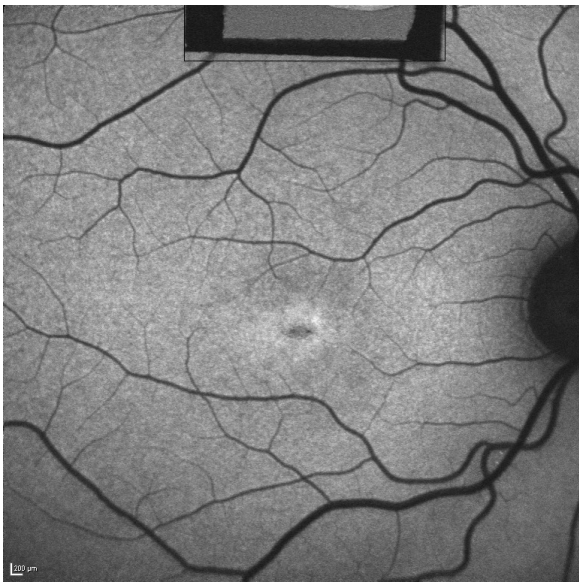


8  
+

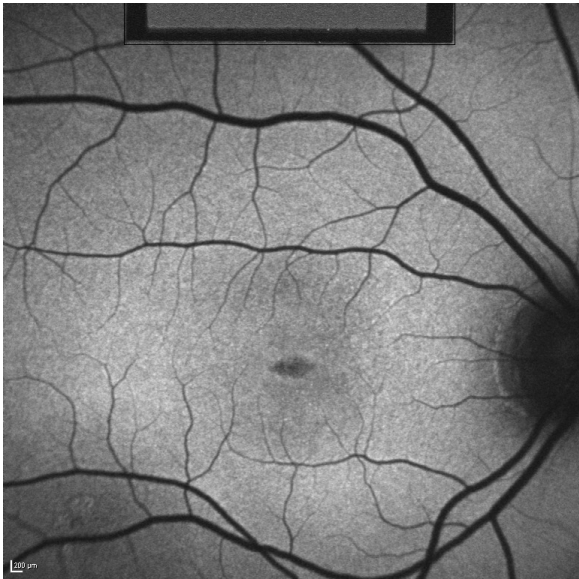
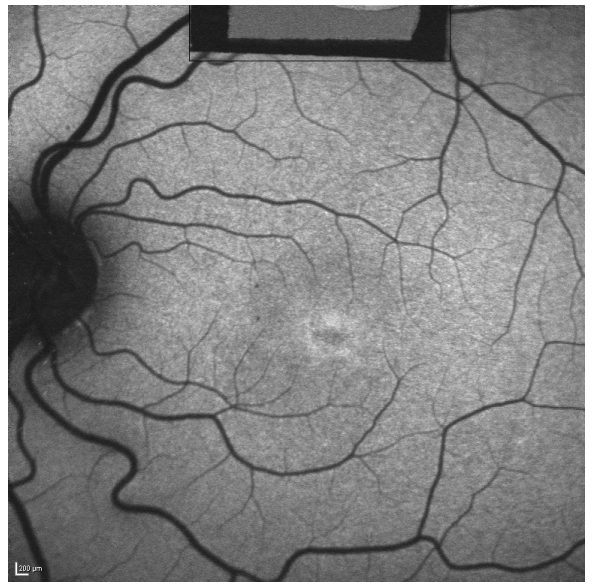

9  
+

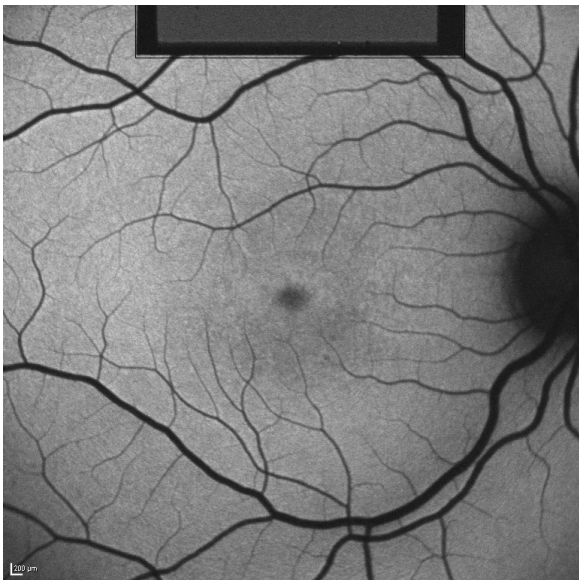
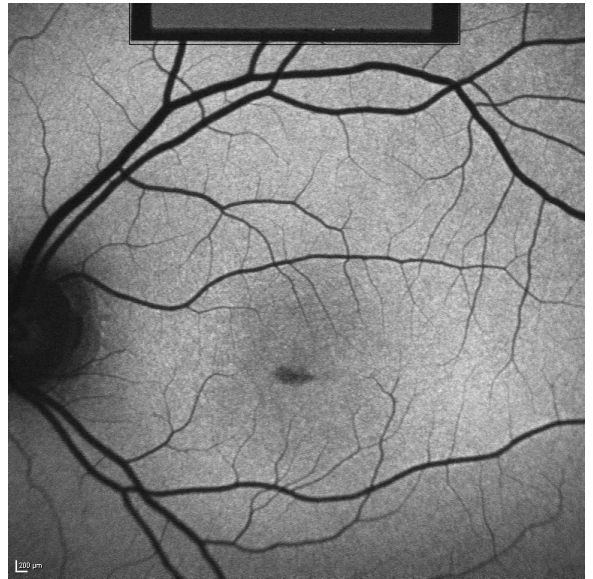




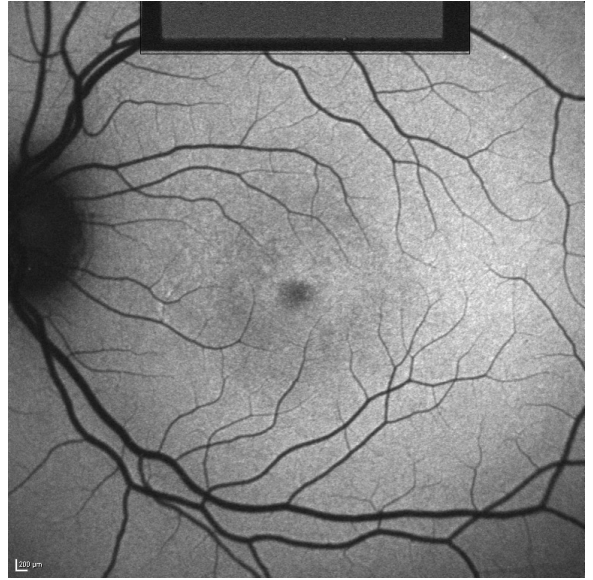
10  
+

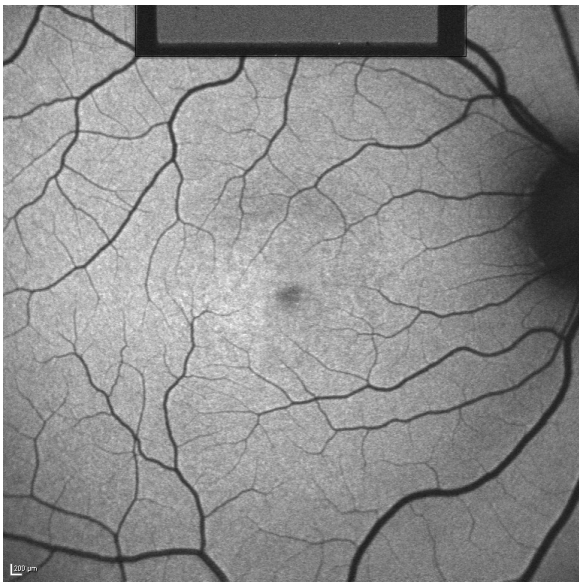


11  
+

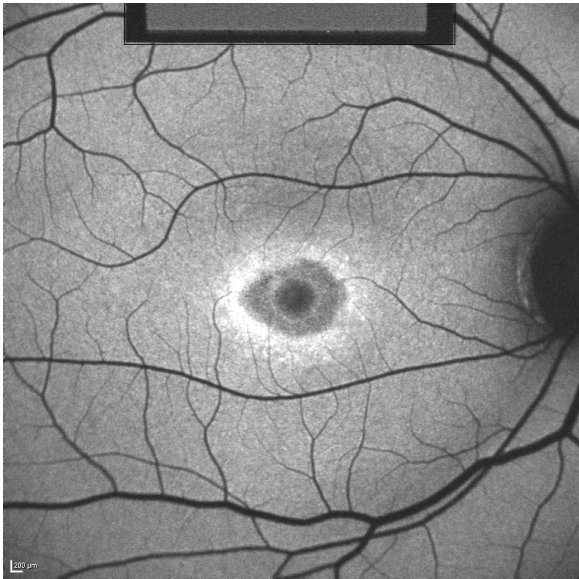
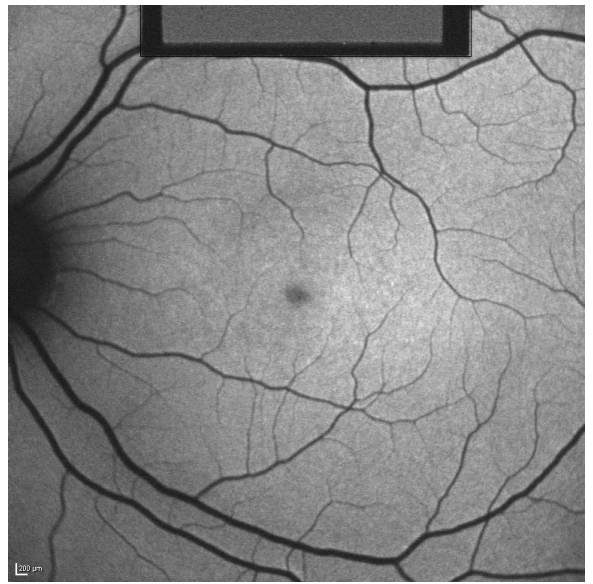


12  
+

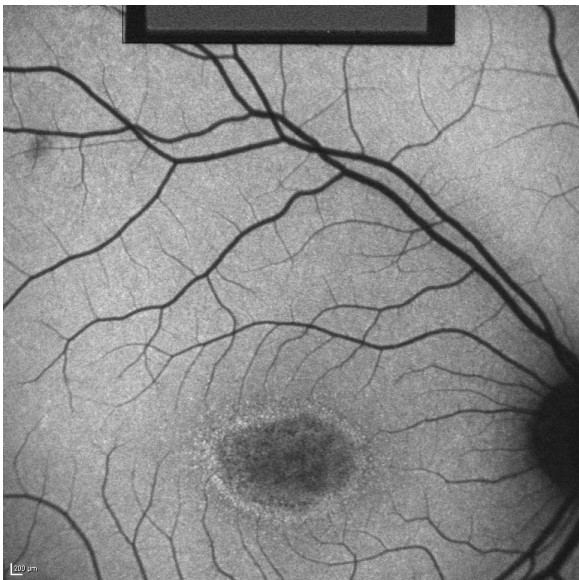
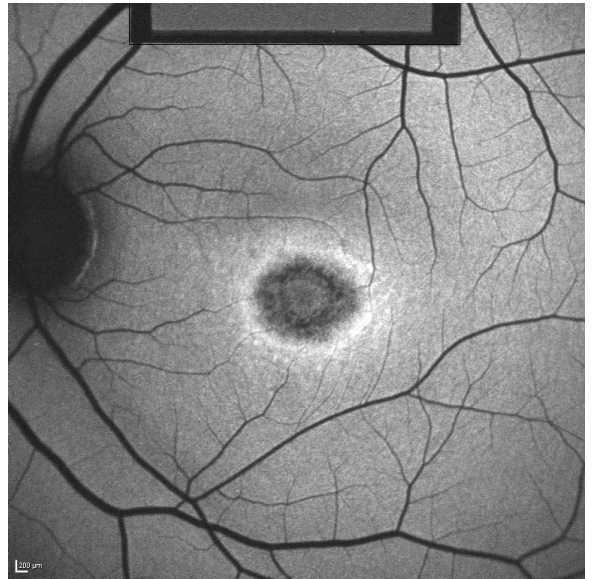




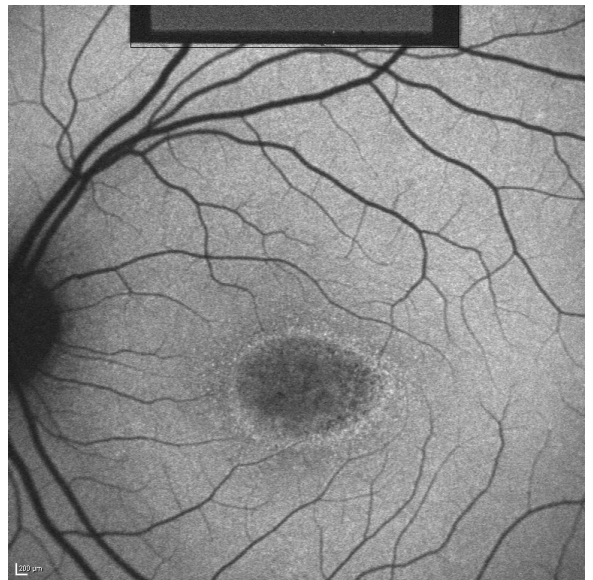
13  
+

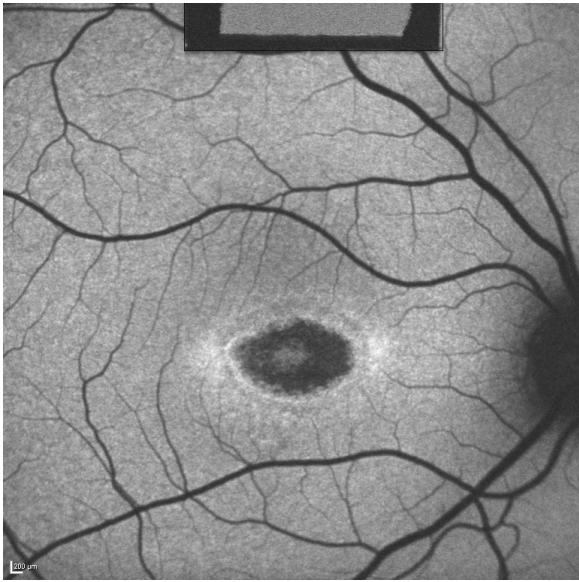


14  
+

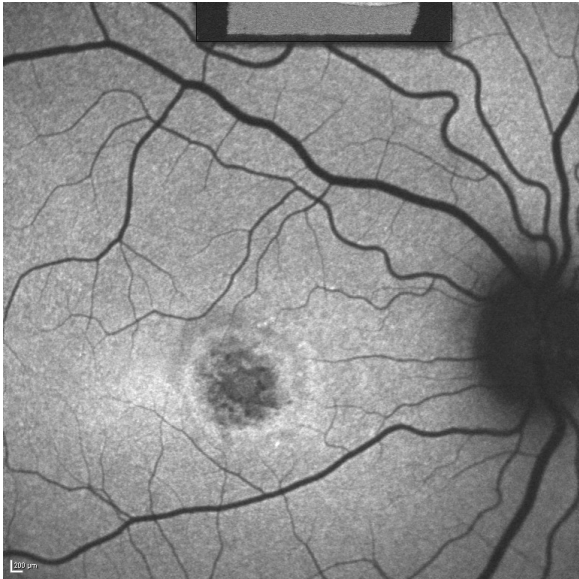


15  
+

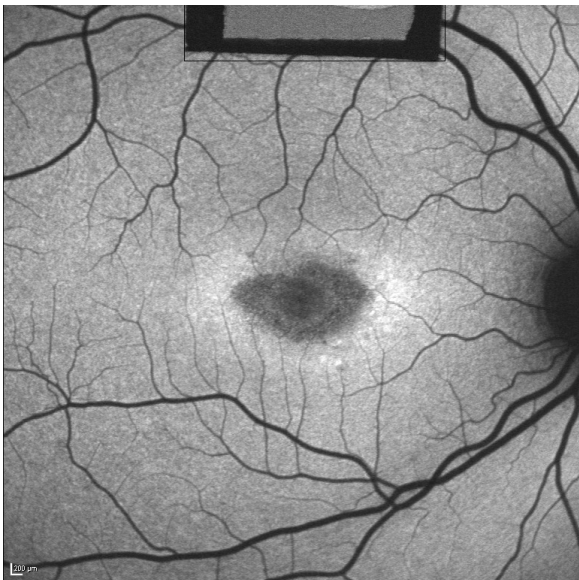
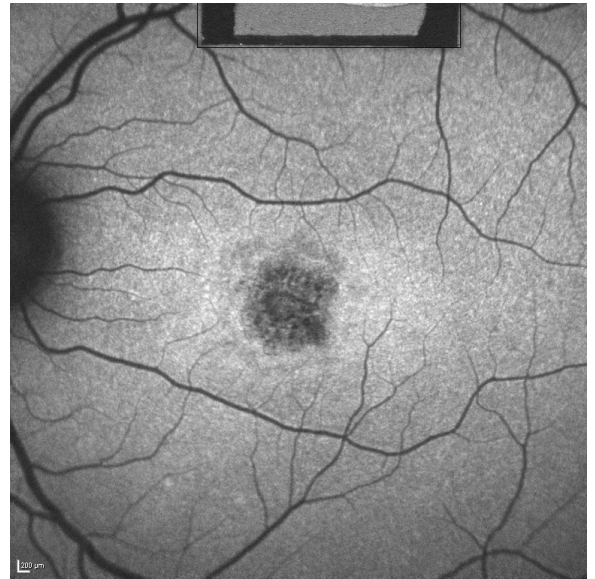




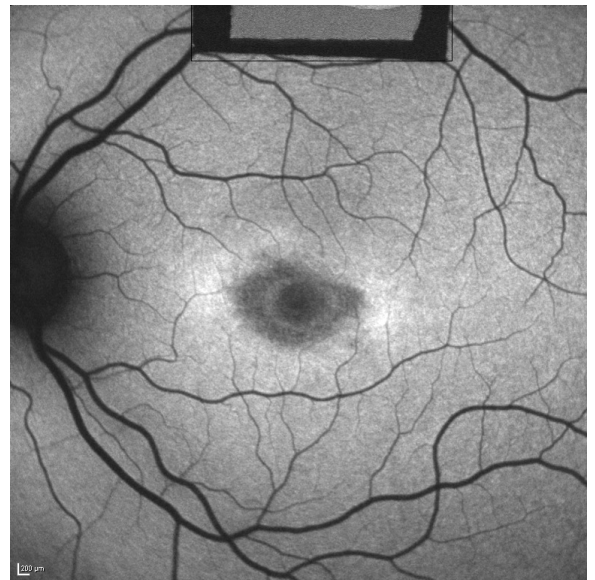
16  
+

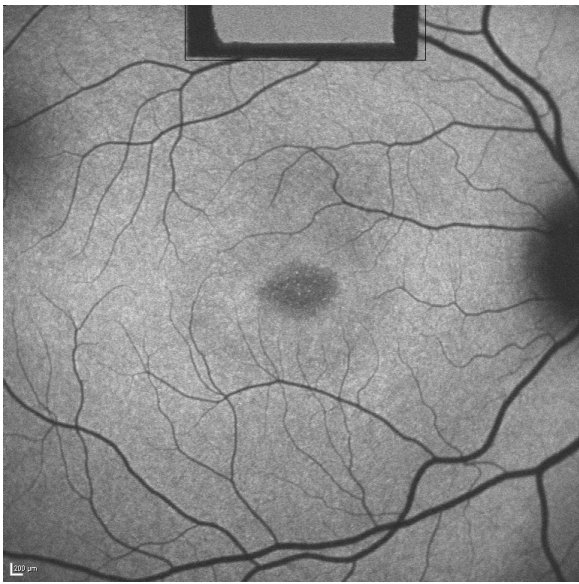

17  
+

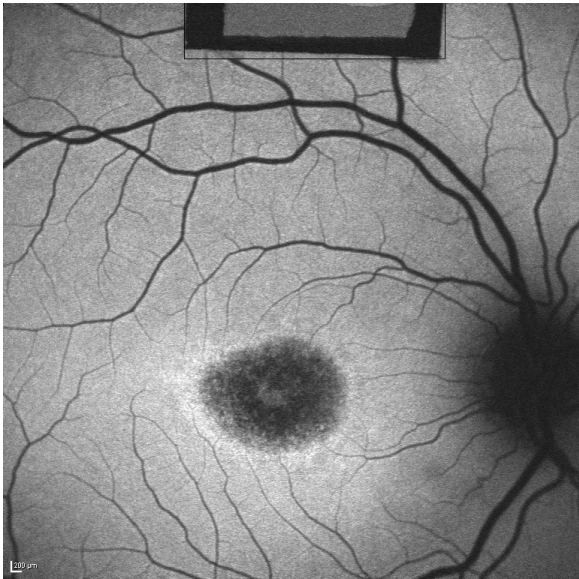
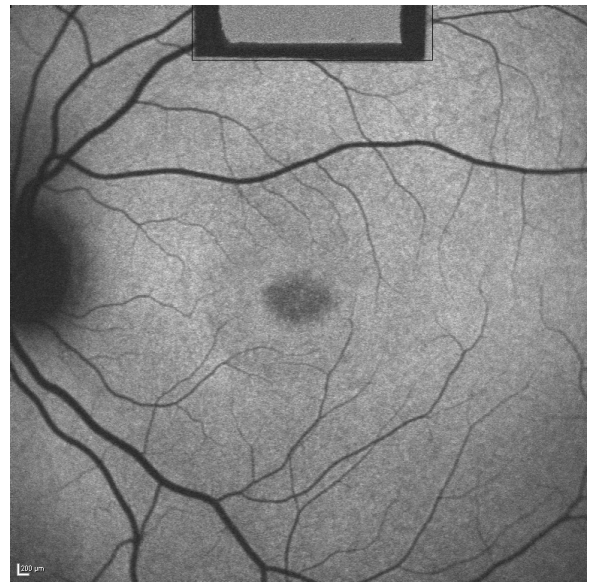

18  
+

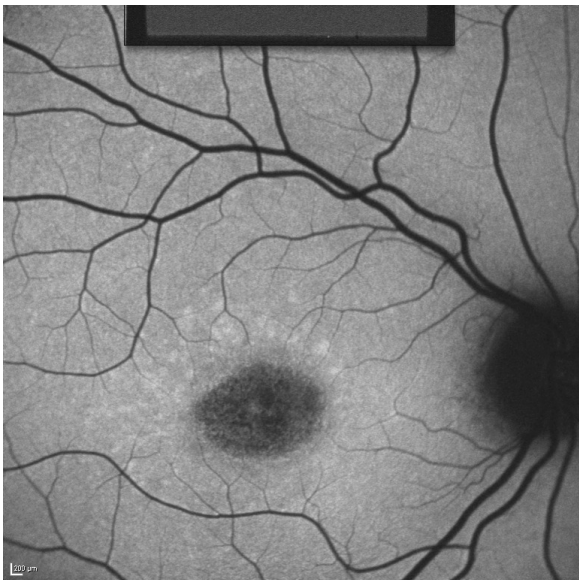
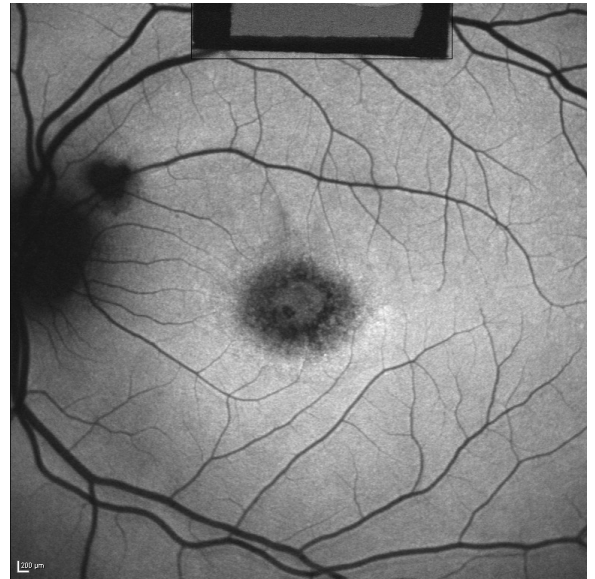




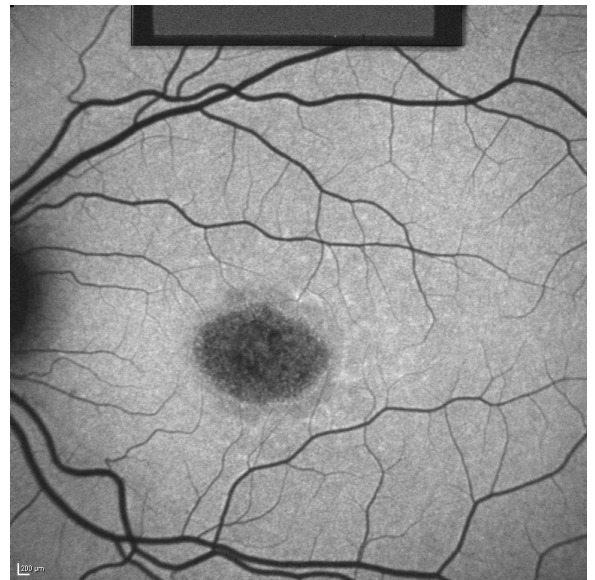
19  
+



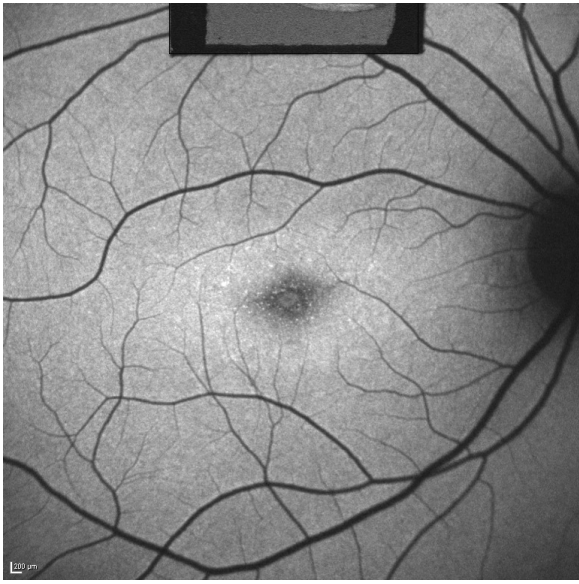
20  
+



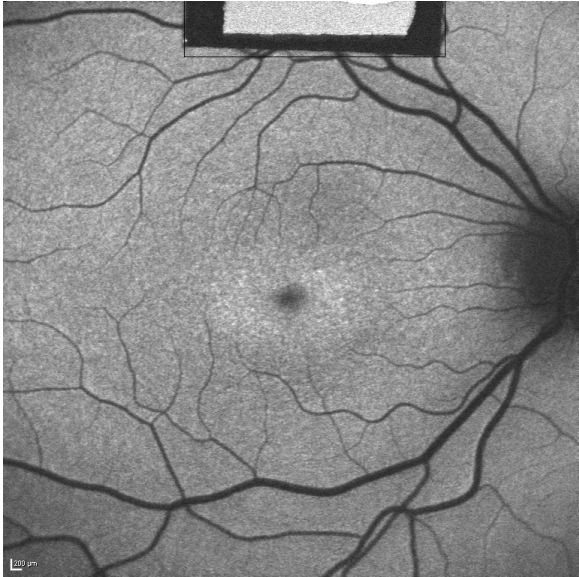
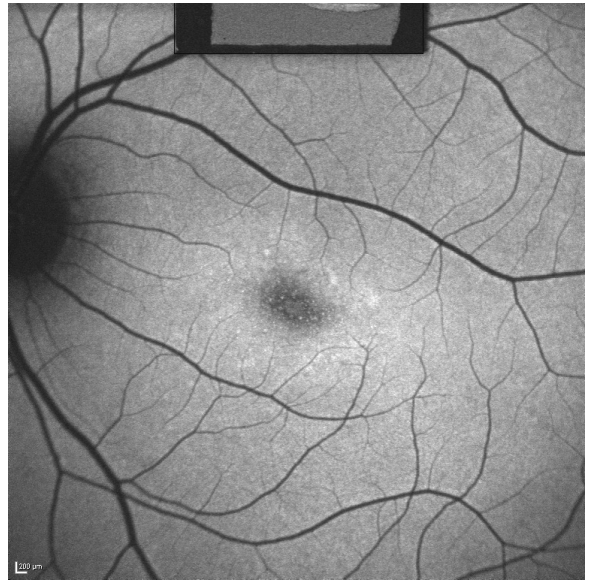
21  
+



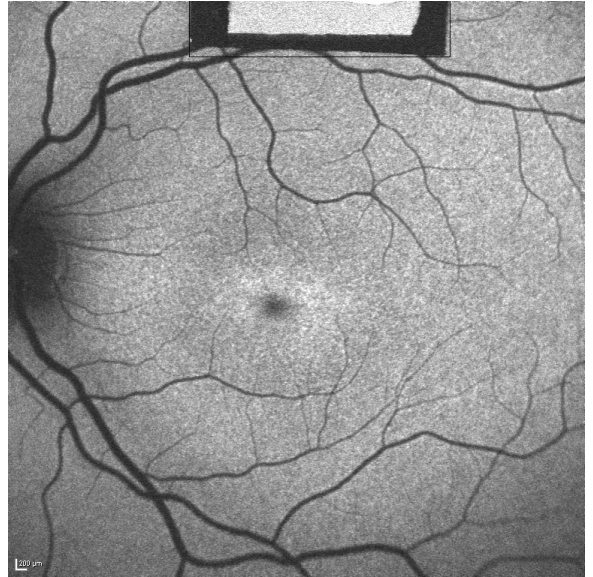




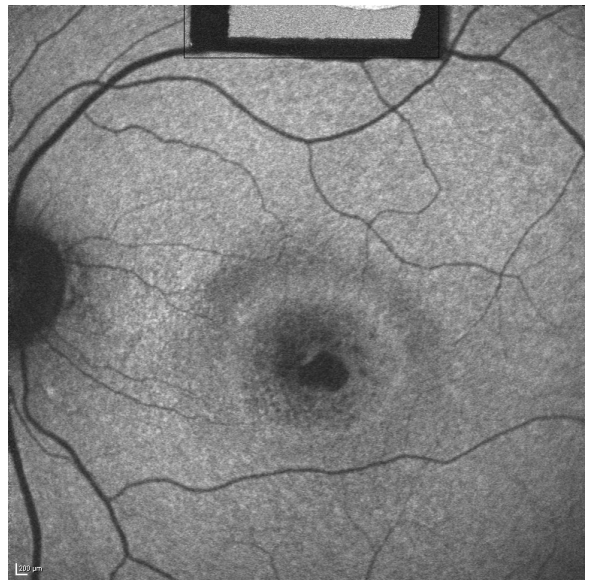22  
+

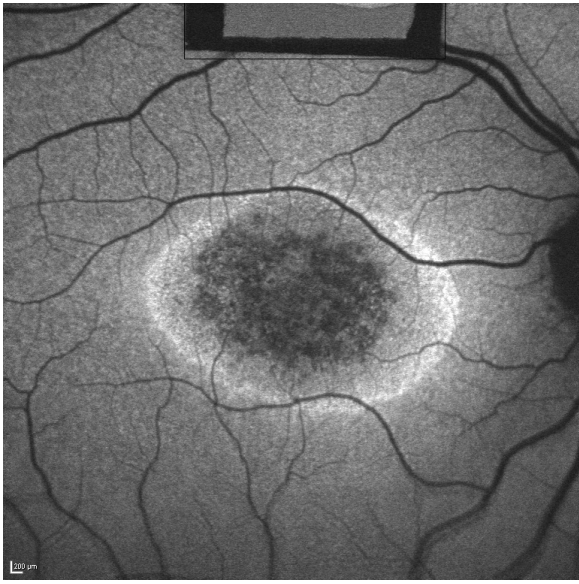


23  
-



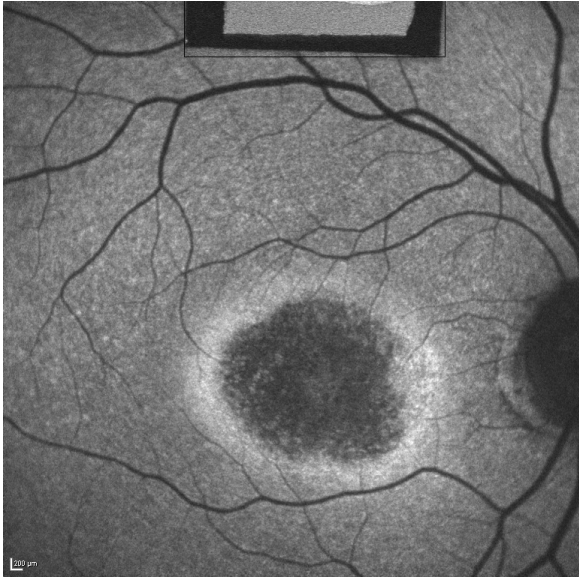
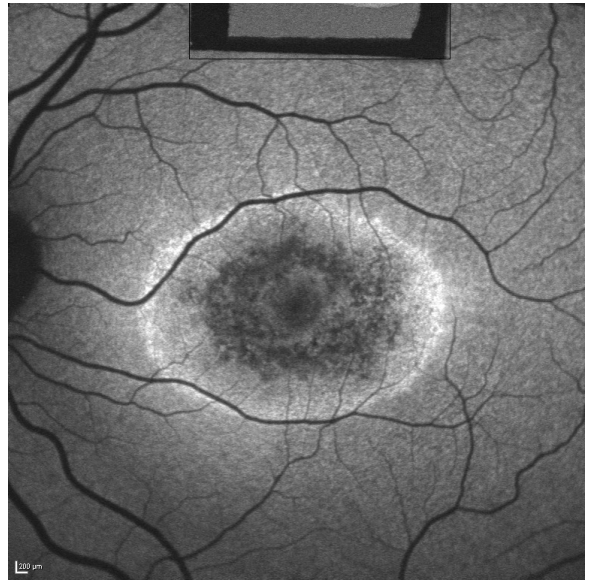
24  
-





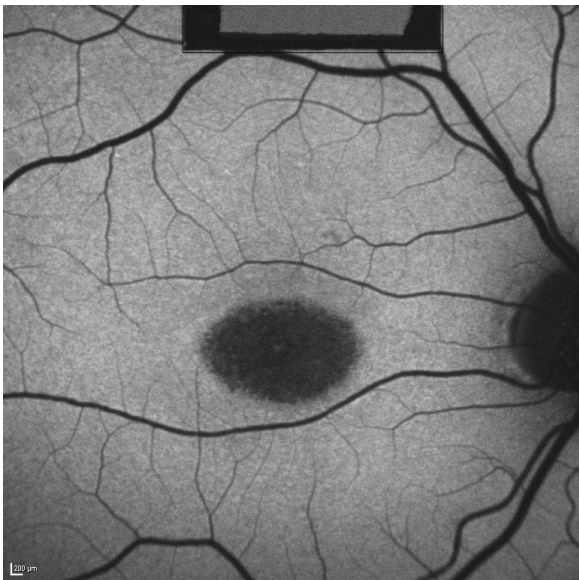
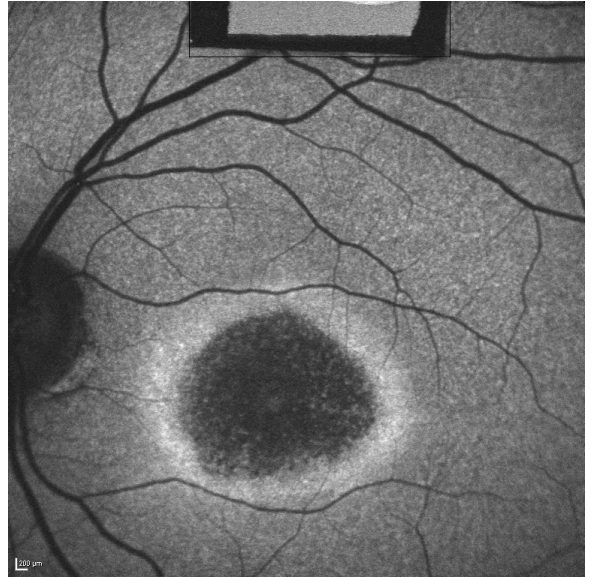
25

-



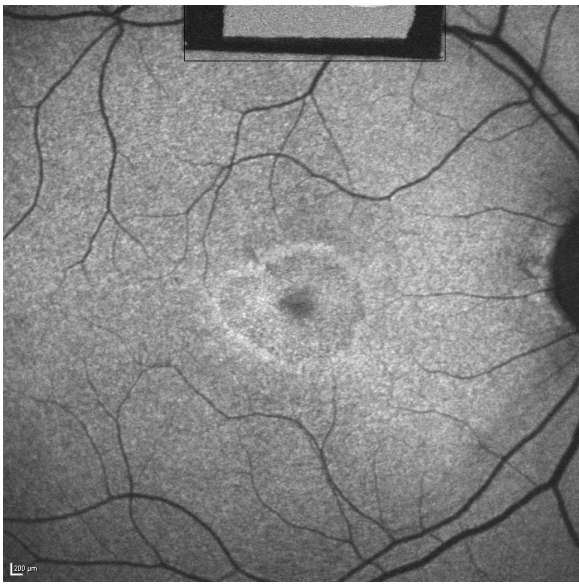
26

-



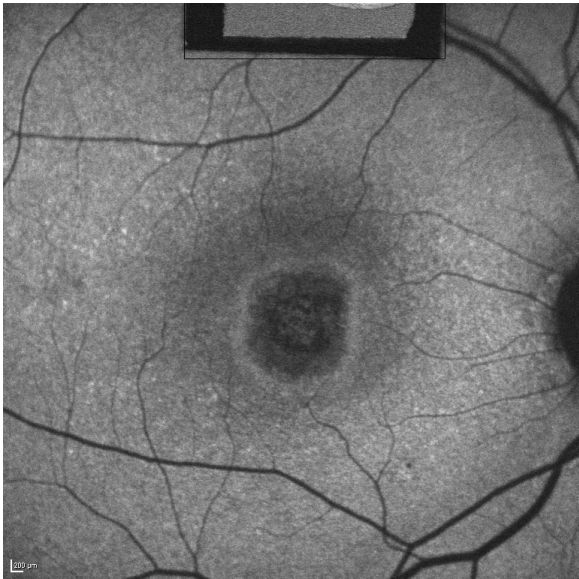
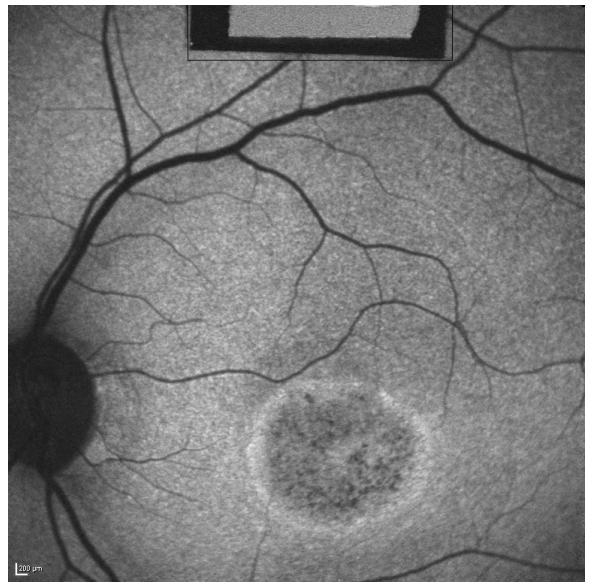
27

-



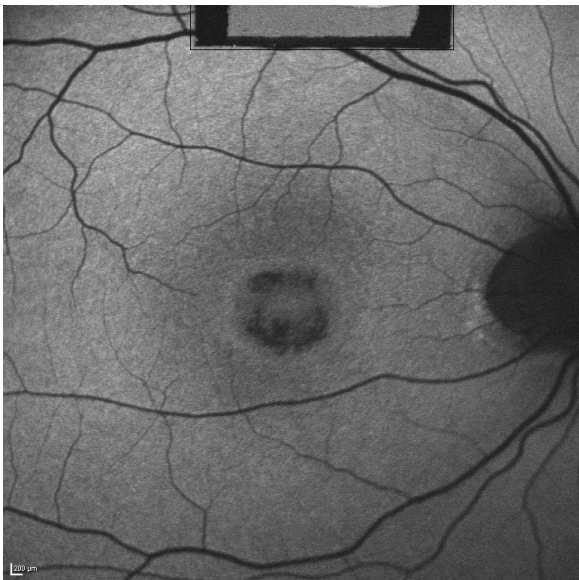
28

-



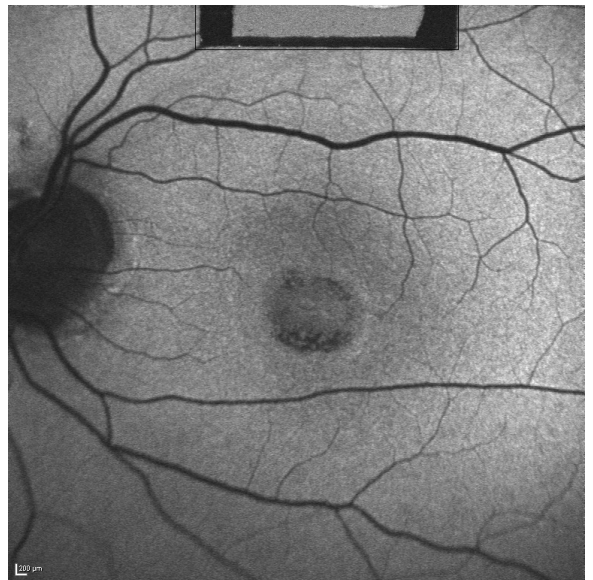
29

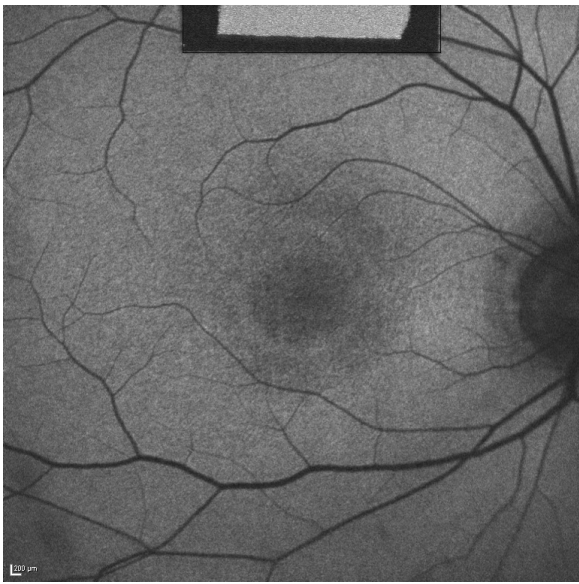
-



30

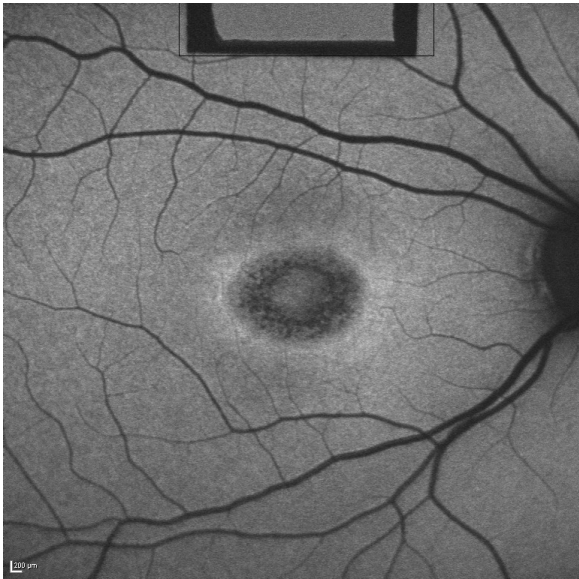
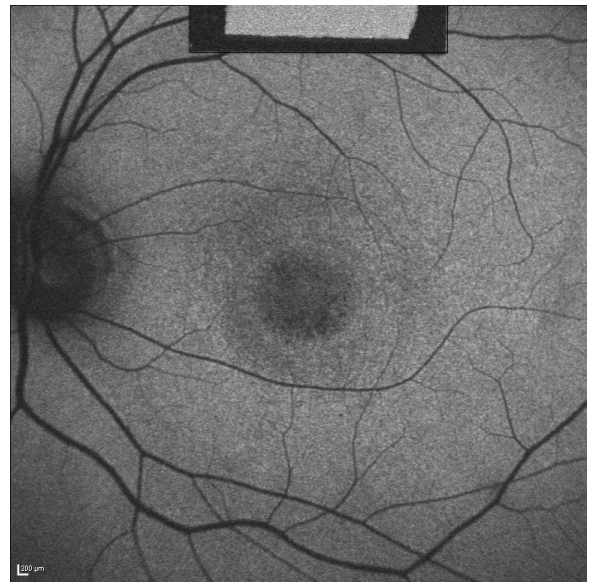
-





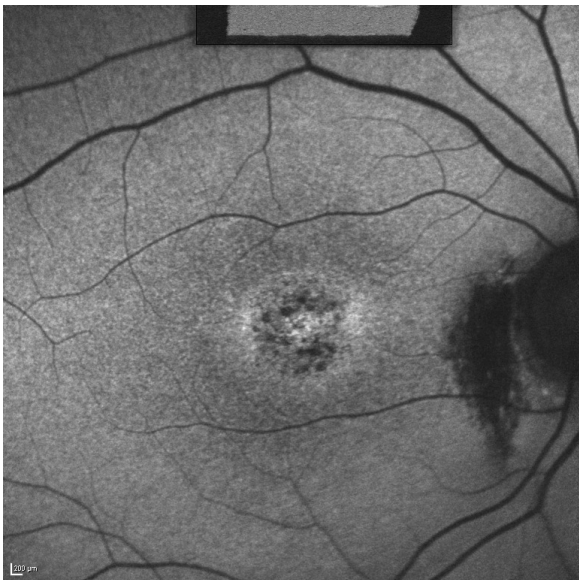
31

-



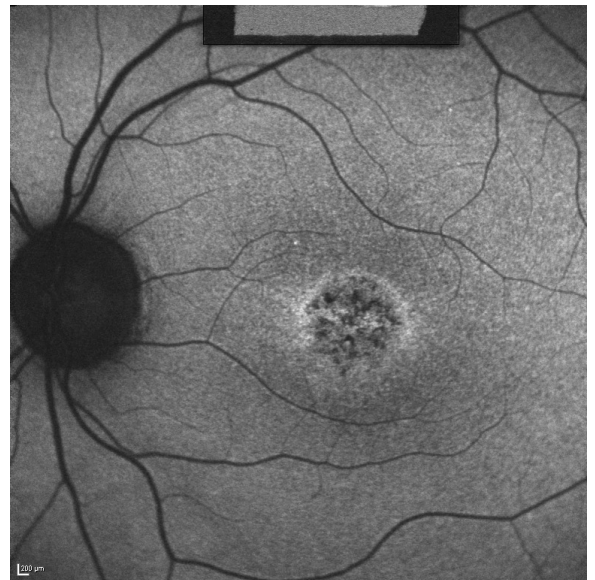
32

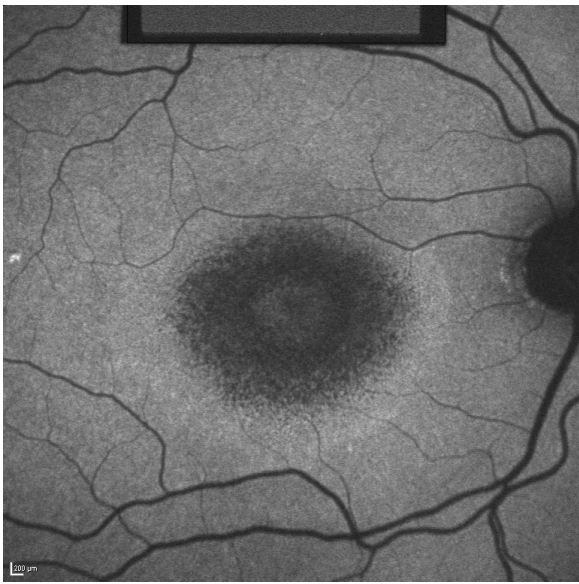
-



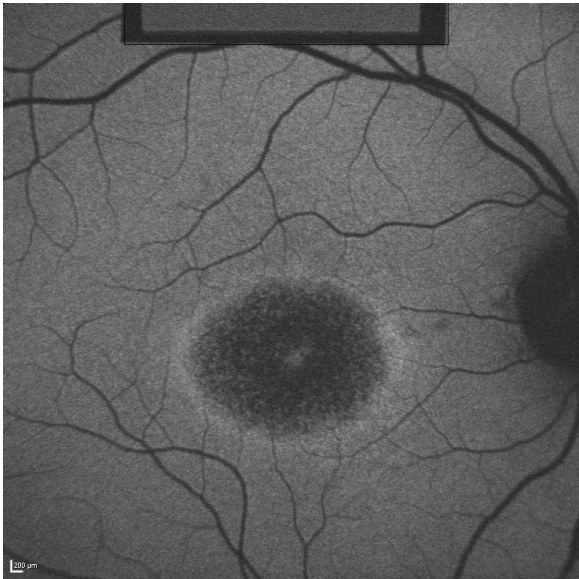
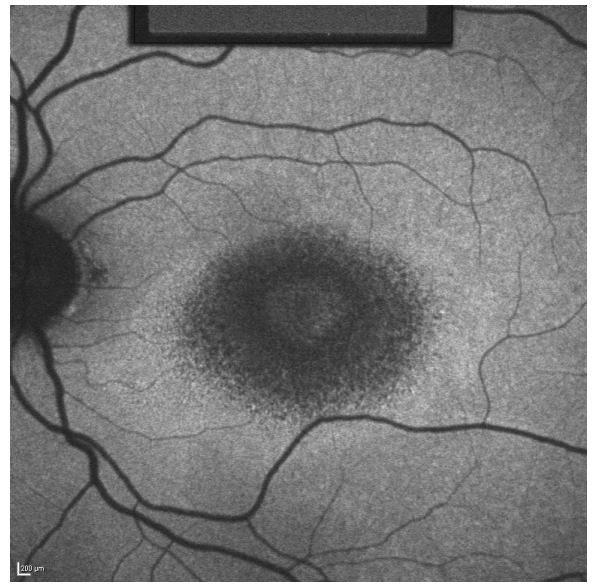
33

-

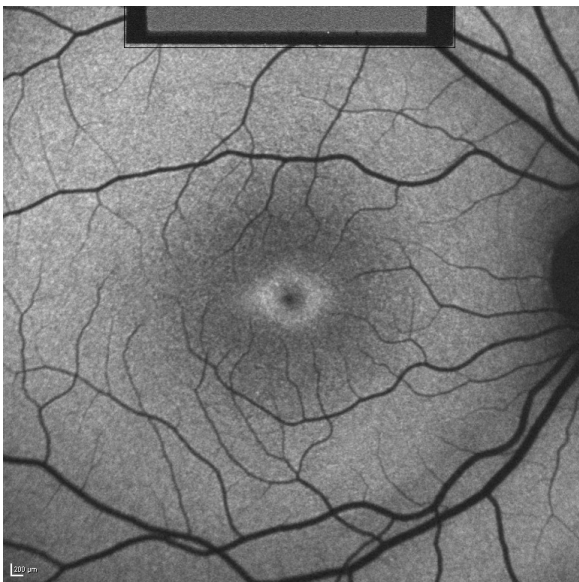
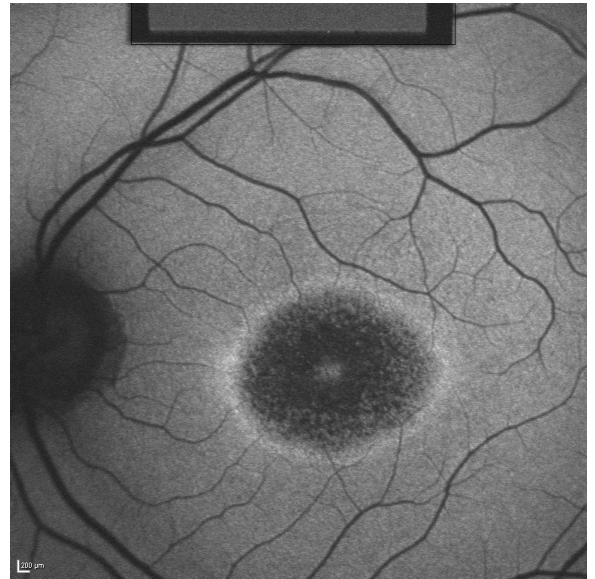




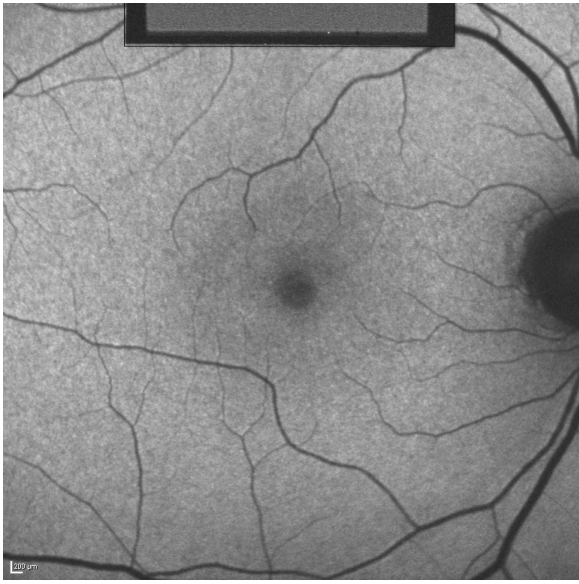
34  
-



35  
-



36  
-



37

-

